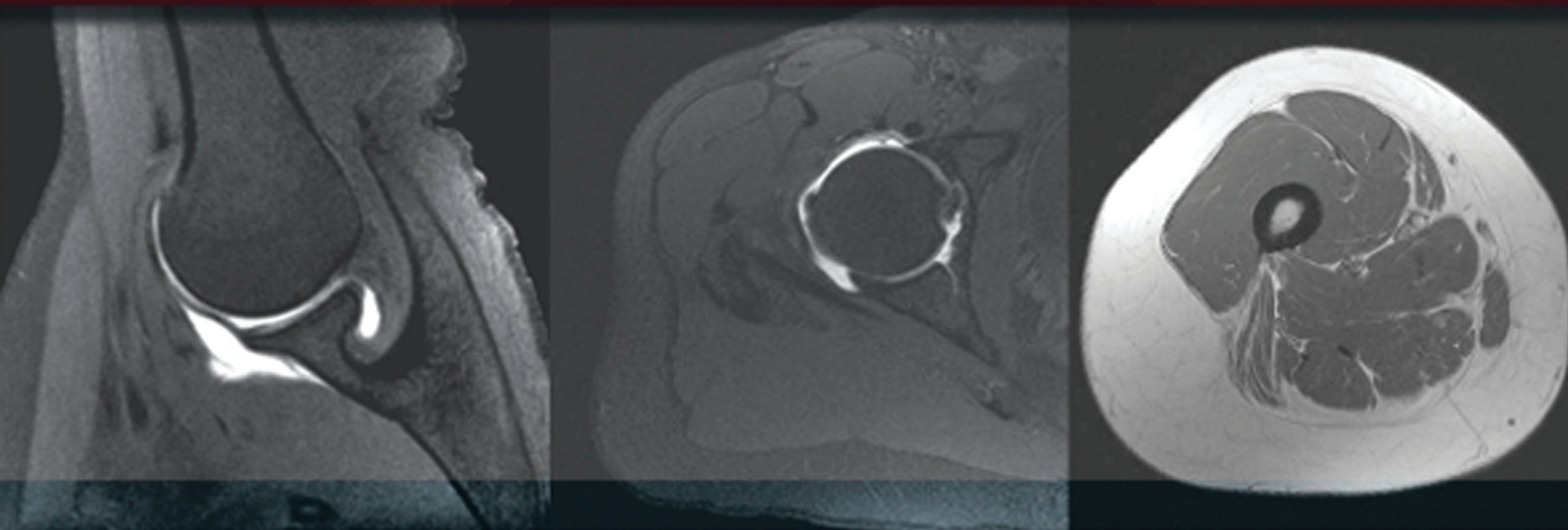


FOURTH EDITION

SECTIONAL ANATOMY

by MRI and CT



MARK W. ANDERSON • MICHAEL G. FOX

ELSEVIER

CLINICAL **KEY**[™]

Smarter search. Faster answers.



Smarter, Faster Search for Better Patient Care

**Unlike a conventional search engine, ClinicalKey
is specifically designed to serve doctors by providing
three core components:**

**1 Comprehensive
Content**

The most current, evidence-based answers available for every medical and surgical specialty.

**2 Trusted
Answers**

Content supplied by Elsevier, the world's leading provider of health and science information.

**3 Unrivaled Speed
to Answer**

Faster, more relevant clinical answers, so you can spend less time searching and more time caring for patients.

Start searching with ClinicalKey today!

Visit ClinicalKey.com for more information and subscription options.

ELSEVIER

Sectional Anatomy by MRI and CT

This page intentionally left blank

Sectional Anatomy by MRI and CT

Fourth Edition

Mark W. Anderson, MD

Harrison Distinguished Teaching Professor of Radiology
Chief, Musculoskeletal Imaging
Professor of Orthopaedic Surgery
University of Virginia
Charlottesville, Virginia

Michael G. Fox, MD

Associate Professor of Radiology and Medical Imaging
Associate Professor of Orthopaedic Surgery
University of Virginia
Charlottesville, Virginia

ELSEVIER

ELSEVIER

1600 John F. Kennedy Blvd.
Ste 1800
Philadelphia, PA 19103-2899

SECTIONAL ANATOMY BY MRI AND CT, FOURTH EDITION

ISBN: 978-0-323-39419-2

Copyright © 2017 by Elsevier, Inc. All rights reserved.

No part of this publication may be reproduced or transmitted in any form or by any means, electronic or mechanical, including photocopying, recording, or any information storage and retrieval system, without permission in writing from the publisher. Details on how to seek permission, further information about the Publisher's permissions policies and our arrangements with organizations such as the Copyright Clearance Center and the Copyright Licensing Agency, can be found at our website: www.elsevier.com/permissions.

This book and the individual contributions contained in it are protected under copyright by the Publisher (other than as may be noted herein).

Notices

Knowledge and best practice in this field are constantly changing. As new research and experience broaden our understanding, changes in research methods, professional practices, or medical treatment may become necessary.

Practitioners and researchers must always rely on their own experience and knowledge in evaluating and using any information, methods, compounds, or experiments described herein. In using such information or methods they should be mindful of their own safety and the safety of others, including parties for whom they have a professional responsibility.

With respect to any drug or pharmaceutical products identified, readers are advised to check the most current information provided (i) on procedures featured or (ii) by the manufacturer of each product to be administered, to verify the recommended dose or formula, the method and duration of administration, and contraindications. It is the responsibility of practitioners, relying on their own experience and knowledge of their patients, to make diagnoses, to determine dosages and the best treatment for each individual patient, and to take all appropriate safety precautions.

To the fullest extent of the law, neither the Publisher nor the authors, contributors, or editors, assume any liability for any injury and/or damage to persons or property as a matter of products liability, negligence or otherwise, or from any use or operation of any methods, products, instructions, or ideas contained in the material herein.

Previous editions copyrighted 2007, 1995, and 1990.

Library of Congress Cataloging-in-Publication Data

Names: Anderson, Mark W., 1957- , author. | Fox, Michael G., author. | El-Khoury, Georges Y. Sectional anatomy by MRI and CT. Preceded by (work):
Title: Sectional anatomy by MRI and CT / Mark W. Anderson, Michael G. Fox.
Description: Fourth edition. | Philadelphia, PA : Elsevier, [2017] | Includes index. | Preceded by Sectional anatomy by MRI and CT / Georges Y. El-Khoury, William J. Montgomery, Ronald A. Bergman. 3rd ed. 2007.
Identifiers: LCCN 2015049199 | ISBN 9780323394192 (hardcover : alk. paper)
Subjects: | MESH: Anatomy, Regional | Magnetic Resonance Imaging | Tomography, X-Ray Computed | Atlases
Classification: LCC QM25 | NLM QS 17 | DDC 611/.90222--dc23
LC record available at <http://lcn.loc.gov/2015049199>

Content Strategist: Robin Carter
Content Development Specialist: Kathryn DeFrancesco
Publishing Services Manager: Catherine Jackson
Senior Project Manager: Daniel Fitzgerald
Designer: Paula Catalano

Printed in China

Last digit is the print number: 9 8 7 6 5 4 3 2 1



Working together
to grow libraries in
developing countries

www.elsevier.com • www.bookaid.org

Preface

With the explosion of cross-sectional imaging, the accessibility of a high quality anatomic atlas has become essential and it is with great pleasure that we introduce the fourth edition of this classic atlas.

Since it was first published in 1990, it has become a standard anatomic reference source. The first three editions were masterfully edited by Drs. Georges El-Khoury, Ronald Bergman, and William Montgomery, and we are honored to be able to continue the tradition of excellence that they established.

New features in this fourth edition include color-coded labeling and a corresponding online version that allows for easy access anytime/anywhere and provides features such as scroll, zoom, and search functions that should further enhance the user's experience.

We hope that you will find this new edition to be an integral and valuable addition to your practice.

Mark W. Anderson, MD
Michael G. Fox, MD

Acknowledgments

We are indebted to Drs. El-Khoury and Bergman for their prior efforts in producing and improving this text and for allowing us to continue along the path of excellence they established. We also thank Robin Carter, Katie DeFrancesco, and Dan Fitzgerald

from Elsevier for helping to bring this project to fruition. Without their invaluable assistance, it wouldn't have happened!

Mark W. Anderson, MD
Michael G. Fox, MD

Contents

SECTION I UPPER EXTREMITY

Chapter 1 MRI of the Pectoral Girdle and Chest Wall, 3

Axial, 4
Sagittal, 14
Coronal, 24

Chapter 2 MRI of the Shoulder, 34

Axial, 36
Oblique Sagittal, 46
Oblique Coronal, 56

Chapter 3 MR Arthrography of the Shoulder, 66

Axial, 67
Oblique Sagittal, 72
Oblique Coronal, 78
ABER (Abduction and External Rotation), 84

Chapter 4 MRI of the Arm, 90

Axial, 92
Sagittal, 98
Coronal, 105

Chapter 5 MRI of the Elbow, 114

Axial, 115
Oblique Sagittal, 125
Oblique Coronal, 134

Chapter 6 MRI of the Forearm, 143

Axial, 146
Sagittal, 156
Coronal, 162

Chapter 7 MRI of the Wrist, 170

Axial, 171
Sagittal, 180
Coronal, 189

Chapter 8 MRI of the Hand, 196

Axial, 198
Sagittal, 205
Coronal, 214

SECTION II LOWER EXTREMITY

Chapter 9 MRI of the Hip, 221

Axial, 224
Sagittal, 233
Coronal, 243

Chapter 10 MR Arthrography of the Hip, 250

Axial, 251
Sagittal, 257
Coronal, 262

Chapter 11 MRI of the Thigh, 267

Axial, 269
Sagittal, 277
Coronal, 286

Chapter 12 MRI of the Knee, 294

Axial, 295
Sagittal, 302
Coronal, 311

Chapter 13 MRI of the Leg, 321

Axial, 324
Sagittal, 334
Coronal, 342

Chapter 14 MRI of the Ankle, 348

Axial, 349
Oblique Axial, 359
Sagittal, 365
Coronal, 372

Chapter 15 MRI of the Foot, 381

Axial, 385
Sagittal, 391
Coronal, 399

SECTION III SPINE AND BACK

Chapter 16 MRI of the Thoracic Spine, 411

Axial, 415
Sagittal, 417
Coronal, 420

Chapter 17 MRI of the Lumbar Spine, 424

Axial, 425
Sagittal, 429
Coronal, 432

SECTION IV THORAX

Chapter 18 CT of the Thorax, 441

Axial, 442
Sagittal, 449
Coronal, 453

Chapter 19 MRI of the Heart, 459

Axial, 460
Sagittal, 464
Coronal, 467

SECTION V ABDOMEN

Chapter 20 CT of the Abdomen, 473

Axial, 475
Sagittal, 481
Coronal, 487

Chapter 21 MRI of the Abdomen, 493

Axial, 494
Sagittal, 502
Coronal, 510

SECTION VI PELVIS

Chapter 22 CT of the Male Pelvis, 521

Axial, 522
Sagittal, 528
Coronal, 531

Chapter 23 CT of the Female Pelvis, 537

Axial, 538
Sagittal, 543
Coronal, 546

Chapter 24 MRI of the Male Pelvis, 552

Axial, 553
Sagittal, 559
Coronal, 565

Chapter 25 MRI of the Female Pelvis, 571

Axial, 572
Sagittal, 576
Coronal, 580

Index, 585

I
Section

Upper Extremity

This page intentionally left blank

Chapter
1

**MRI of the Pectoral Girdle
and Chest Wall**

AXIAL

Figure 1.1.1

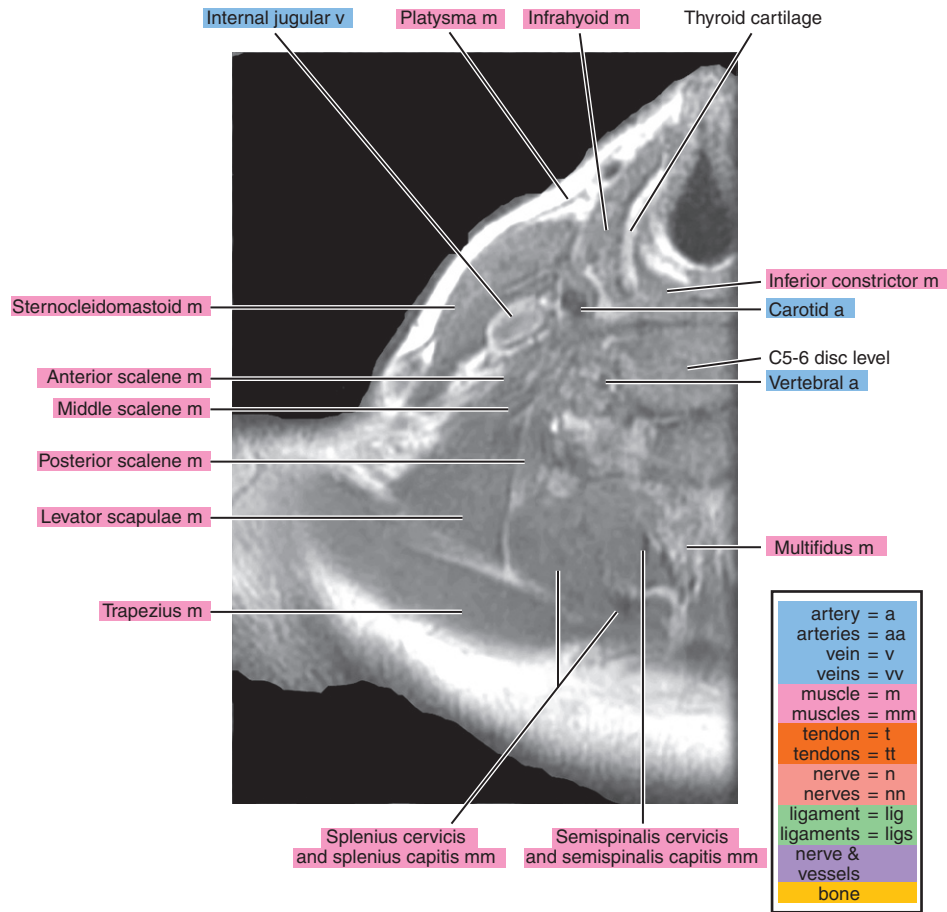
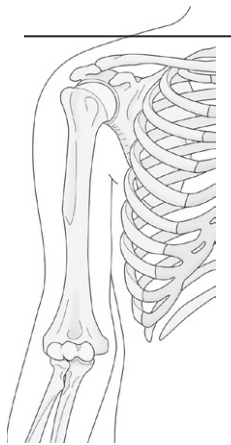


Figure 1.1.2

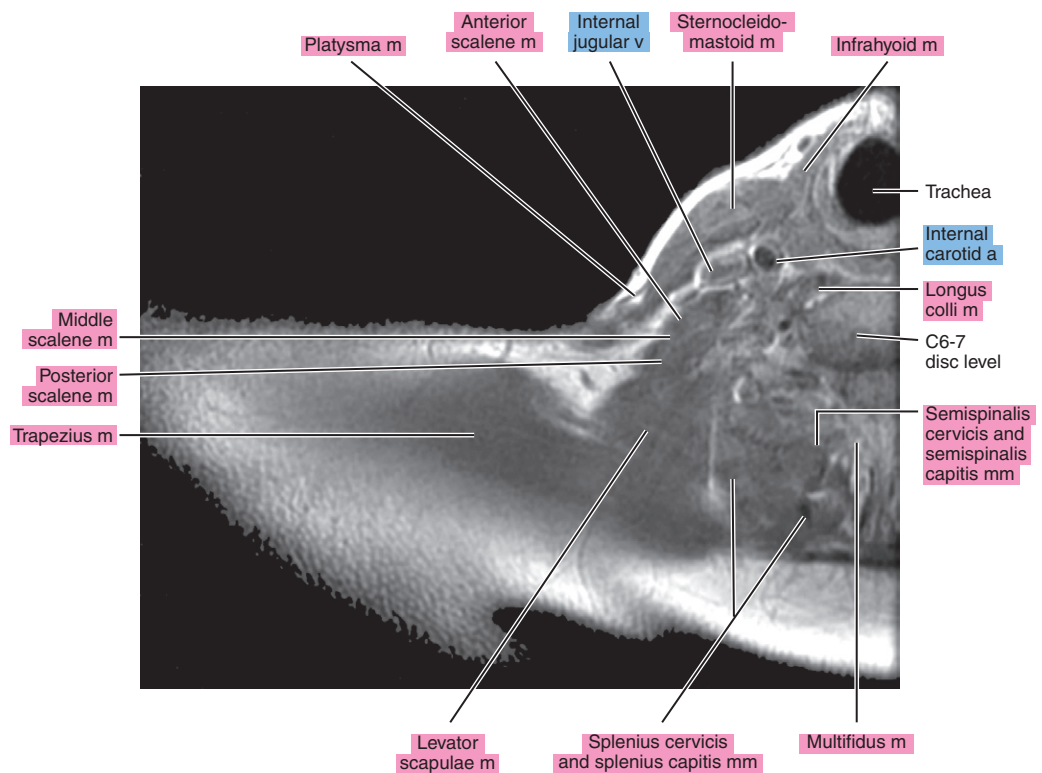
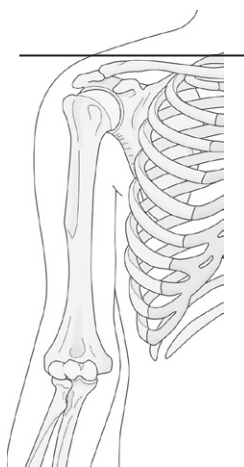


Figure 1.1.3

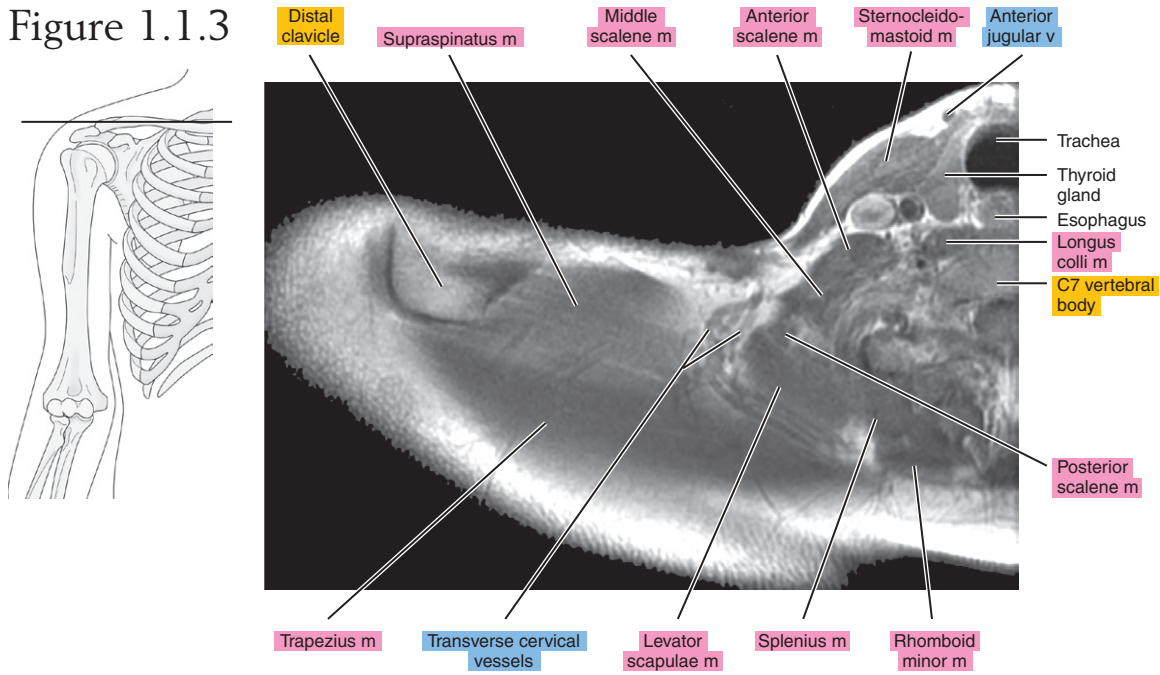


Figure 1.1.4

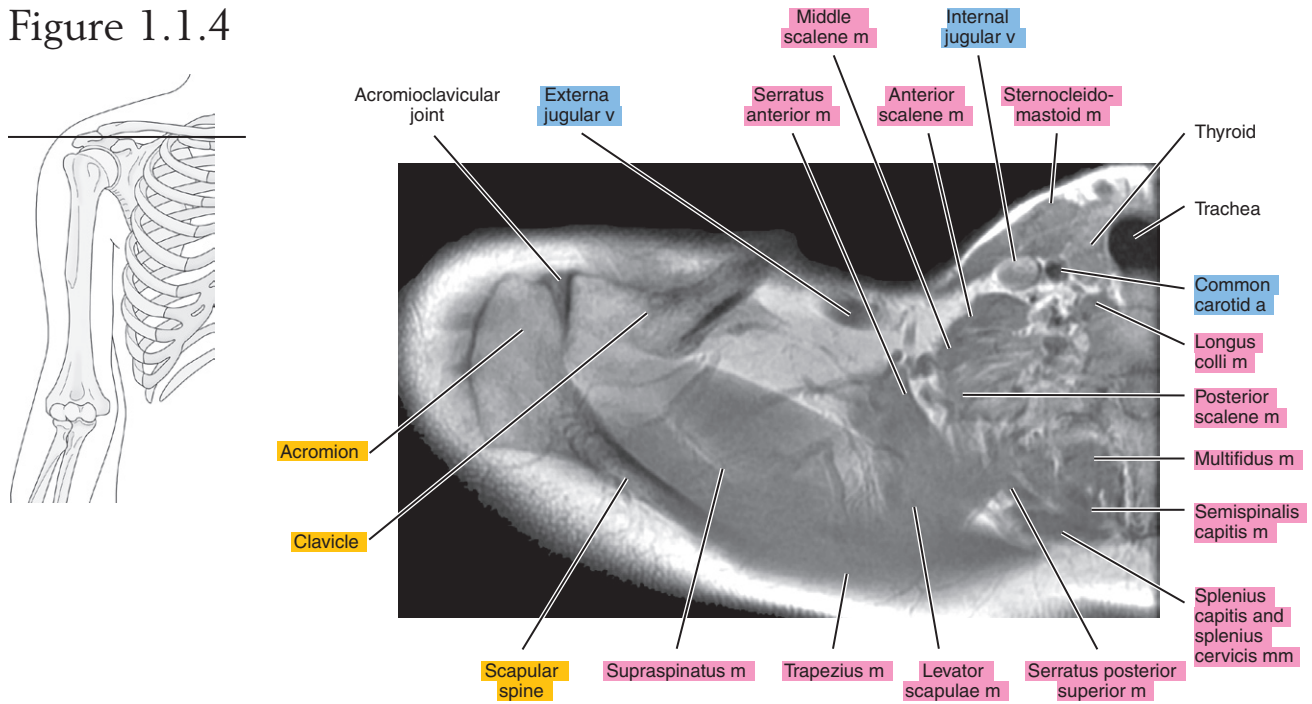


Figure 1.1.5

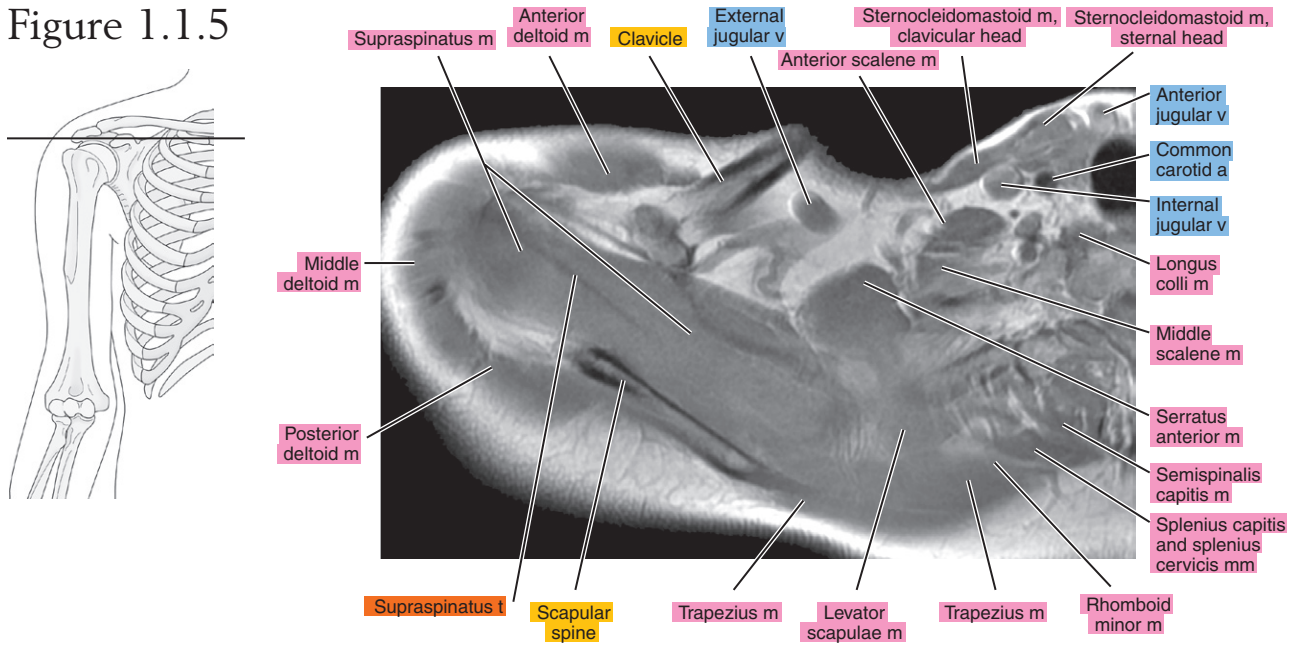


Figure 1.1.6

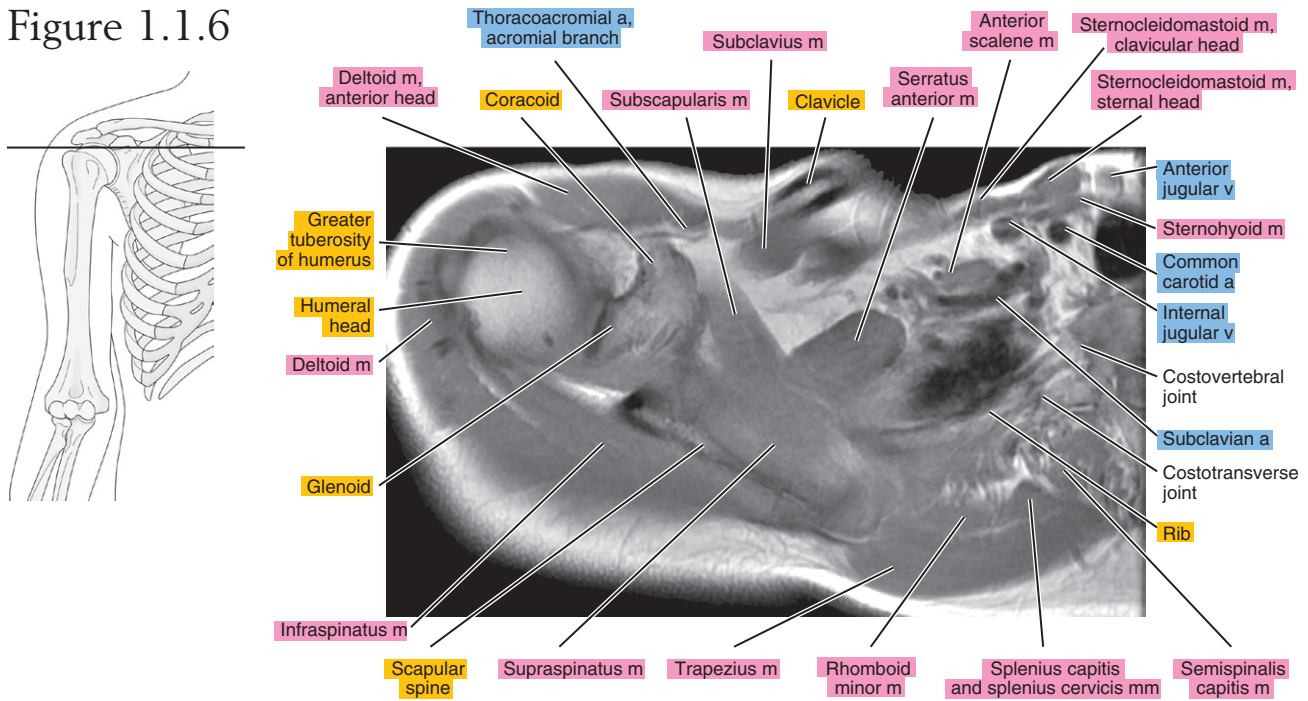


Figure 1.1.7

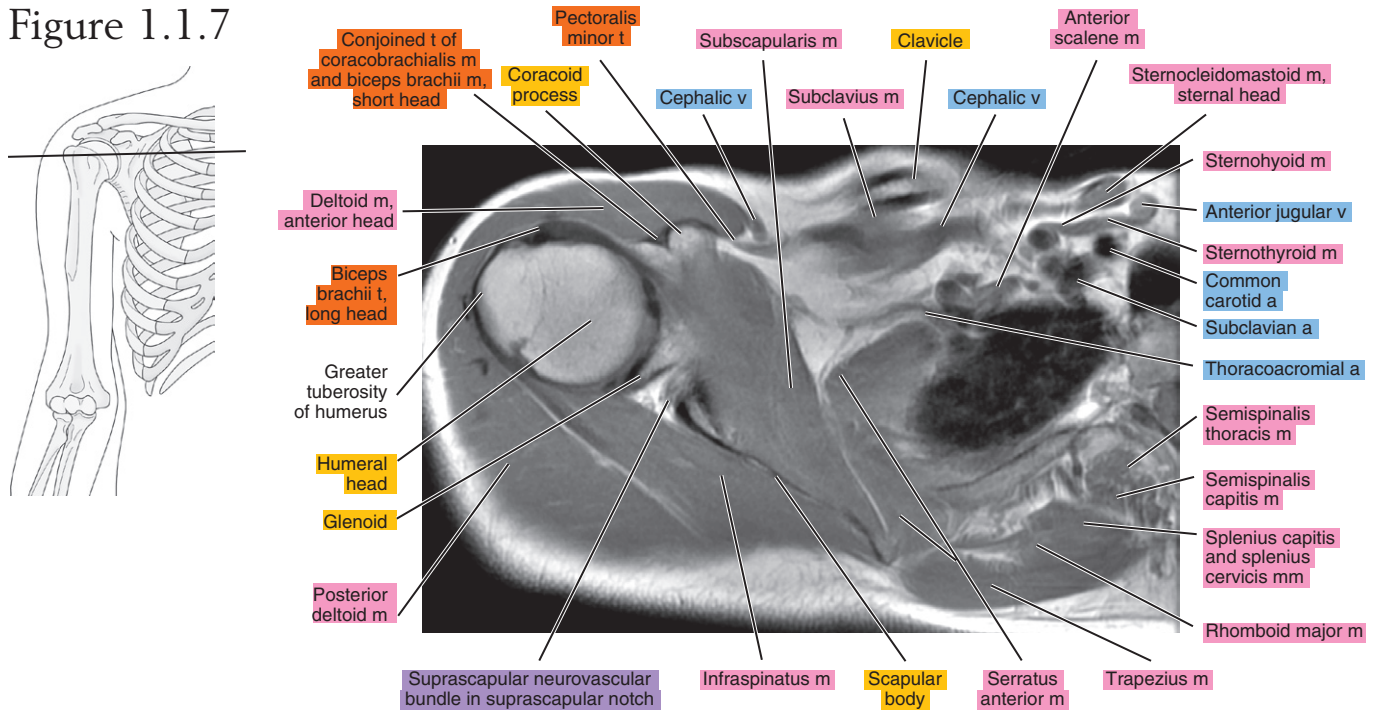


Figure 1.1.8

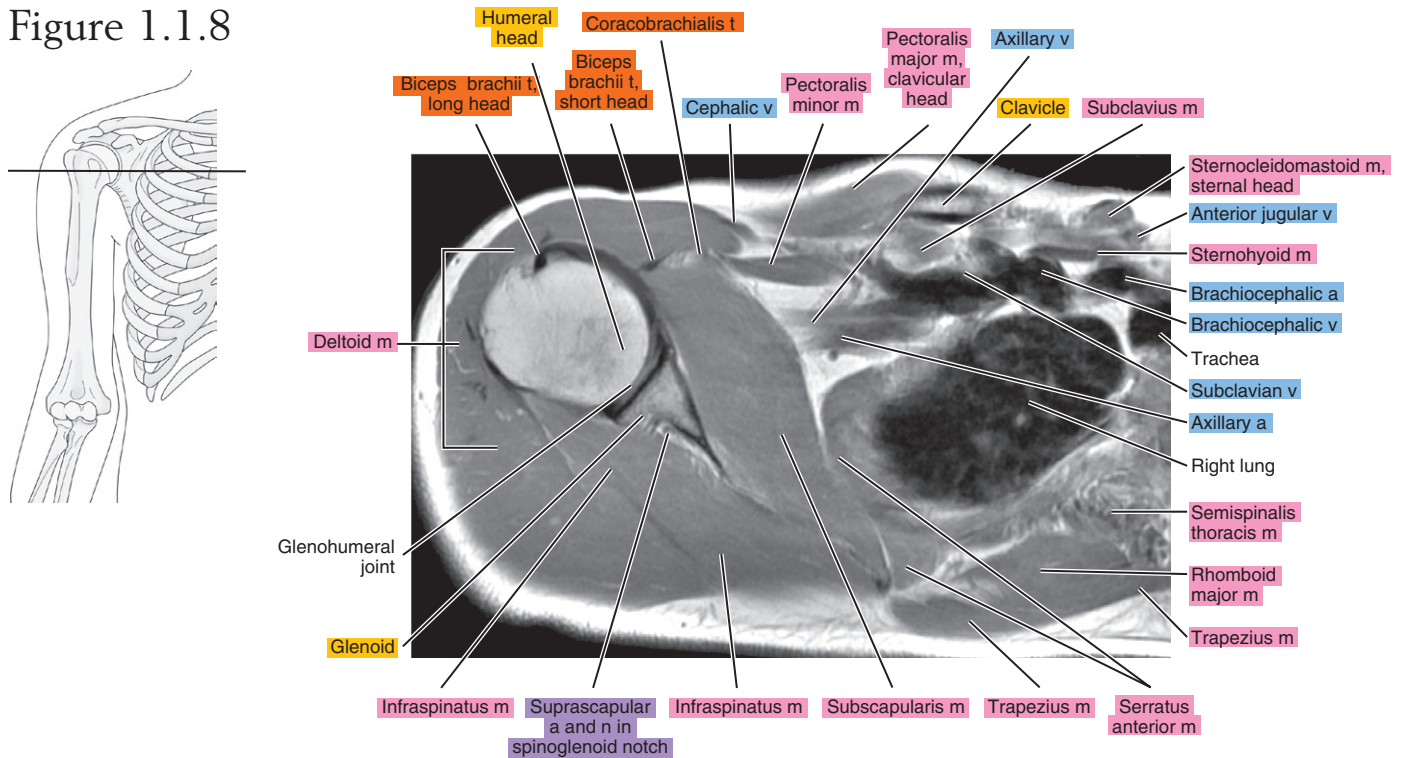


Figure 1.1.9

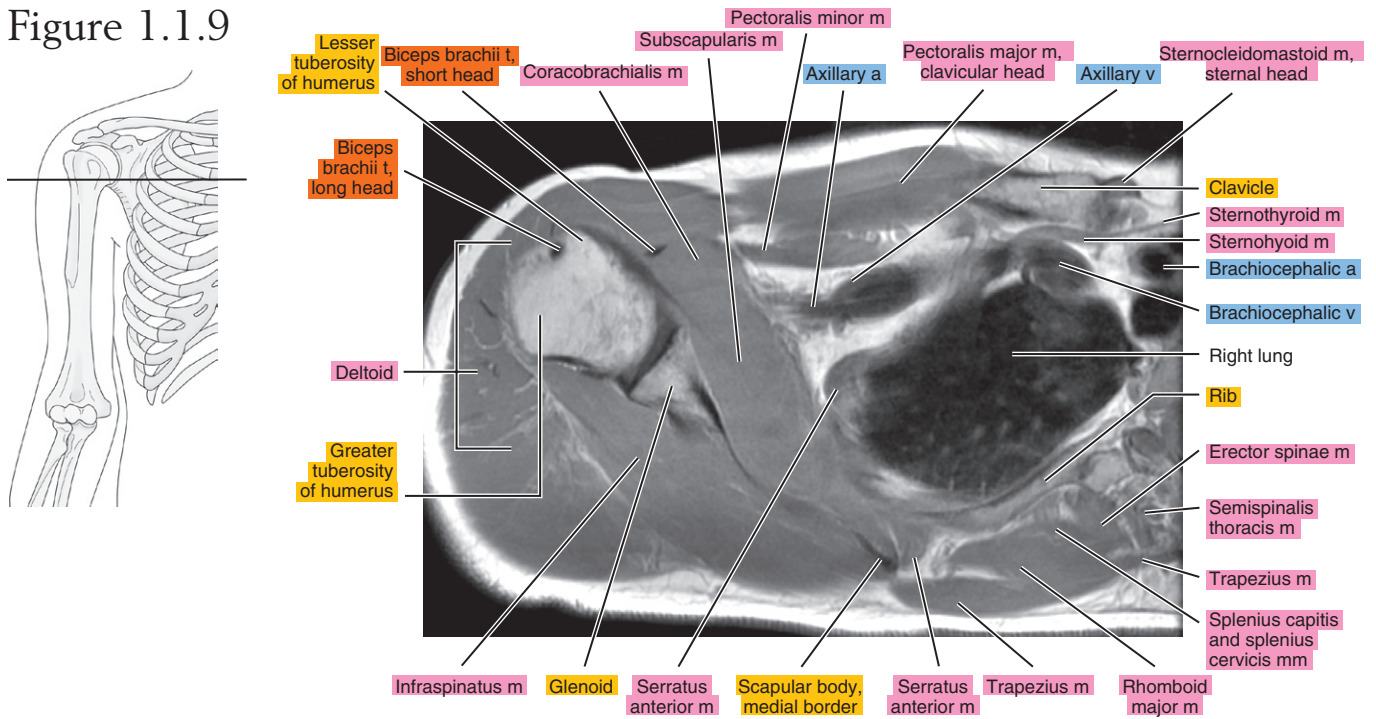


Figure 1.1.10

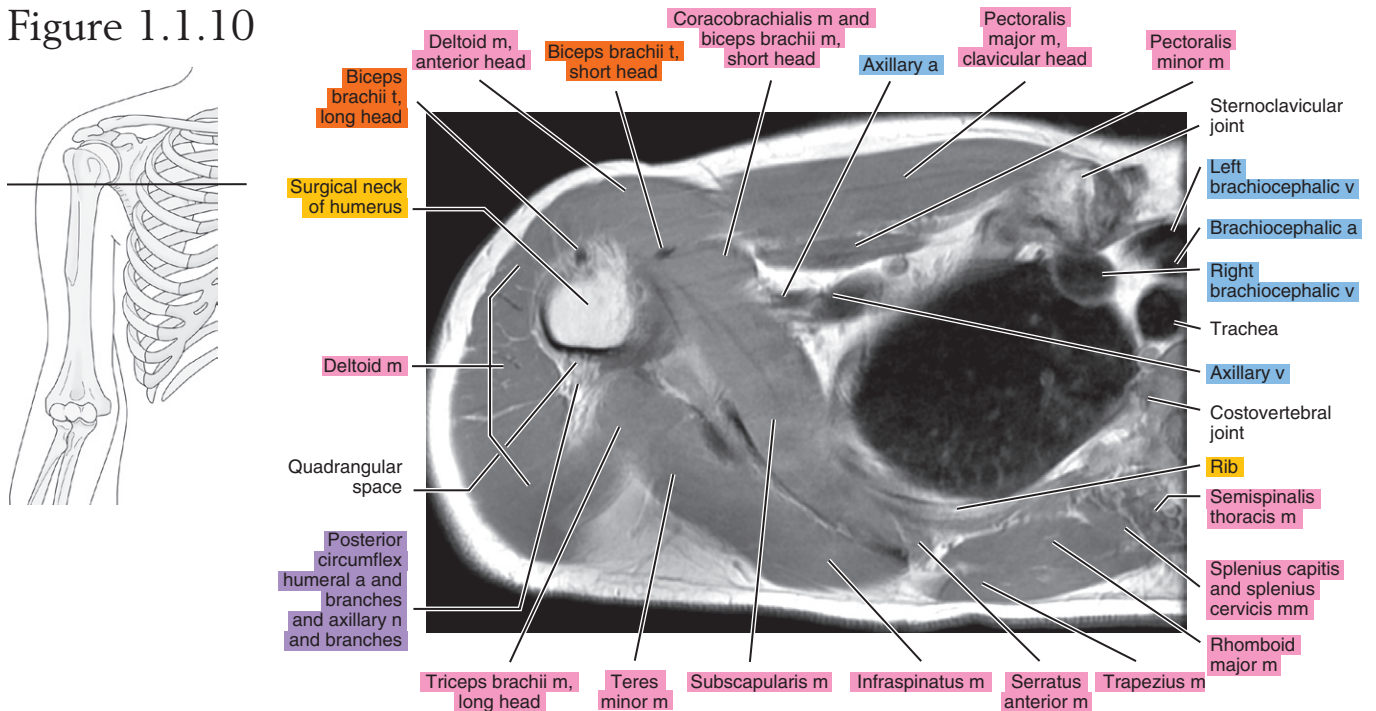


Figure 1.1.11

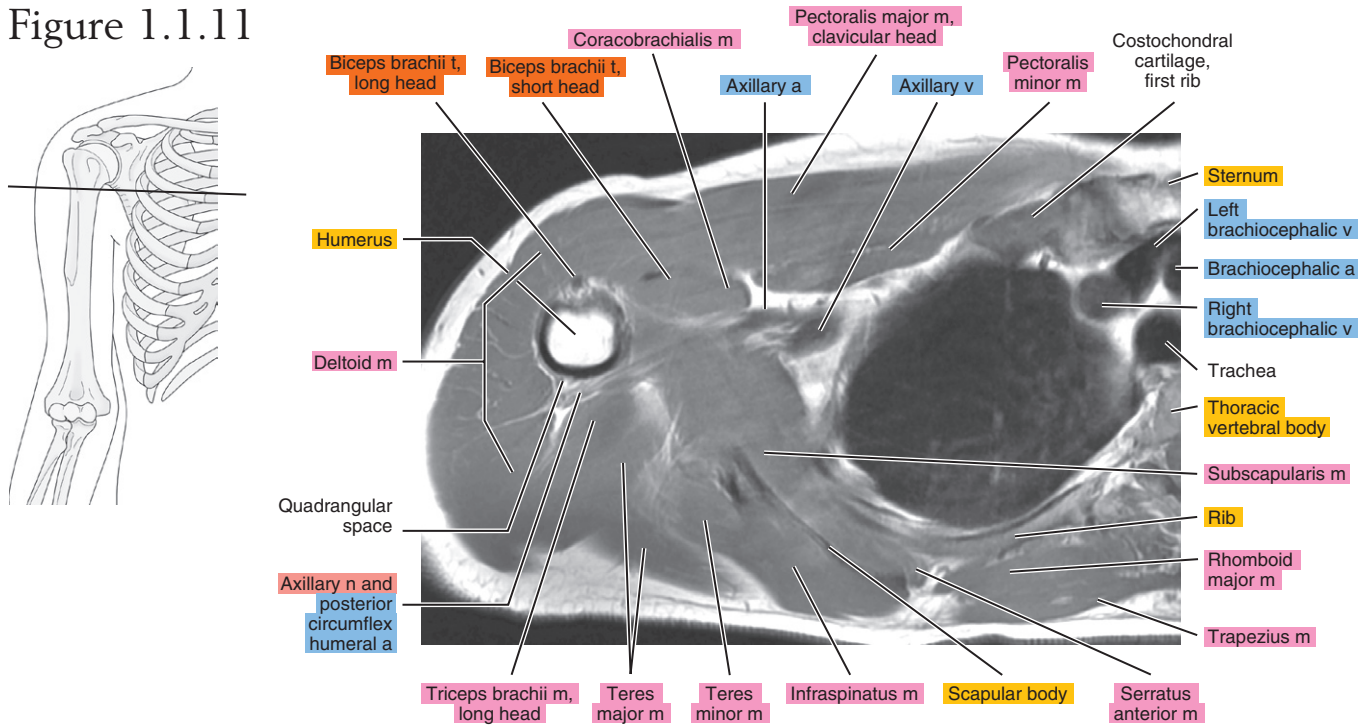


Figure 1.1.12

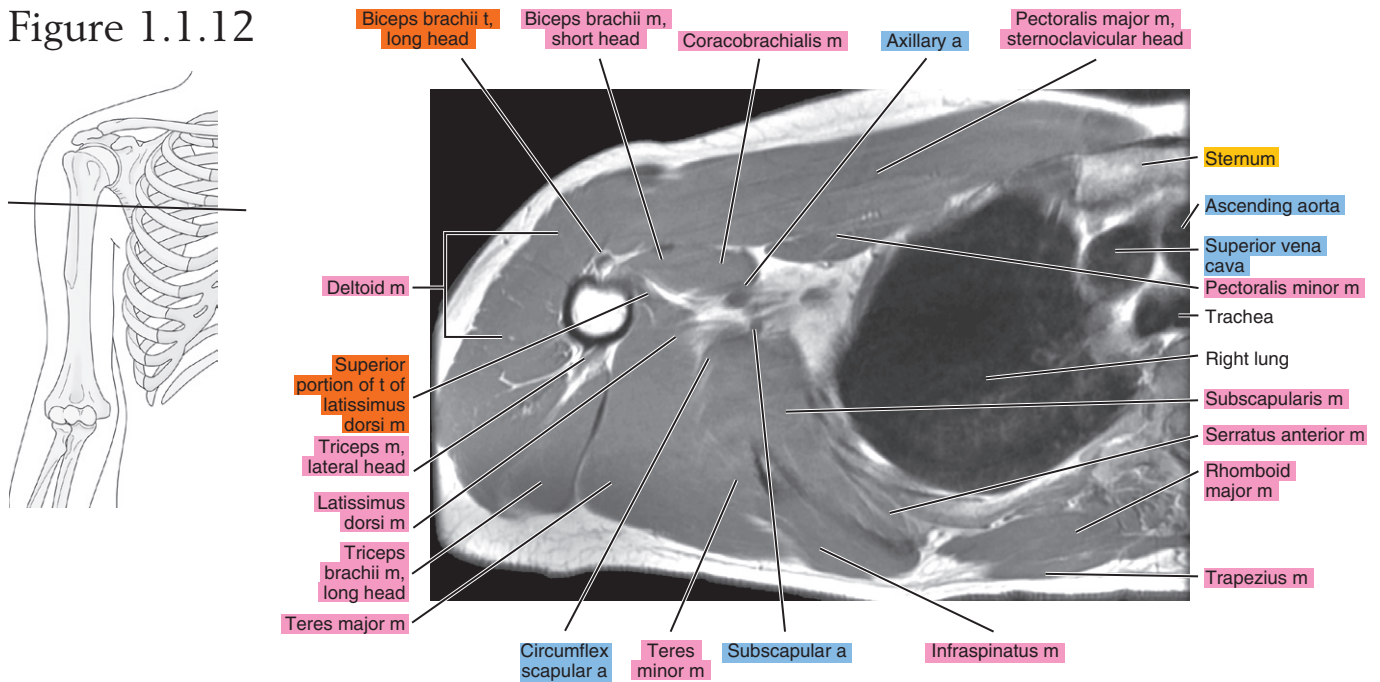


Figure 1.1.13

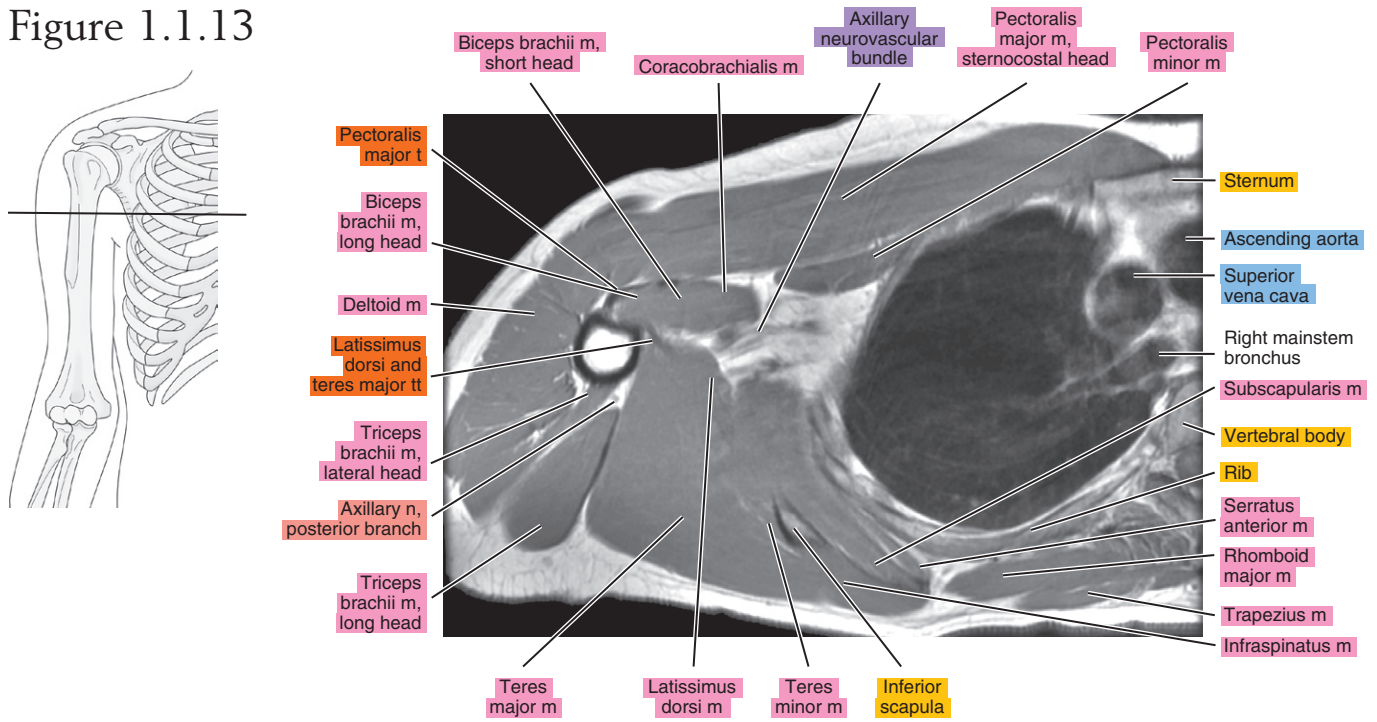


Figure 1.1.14

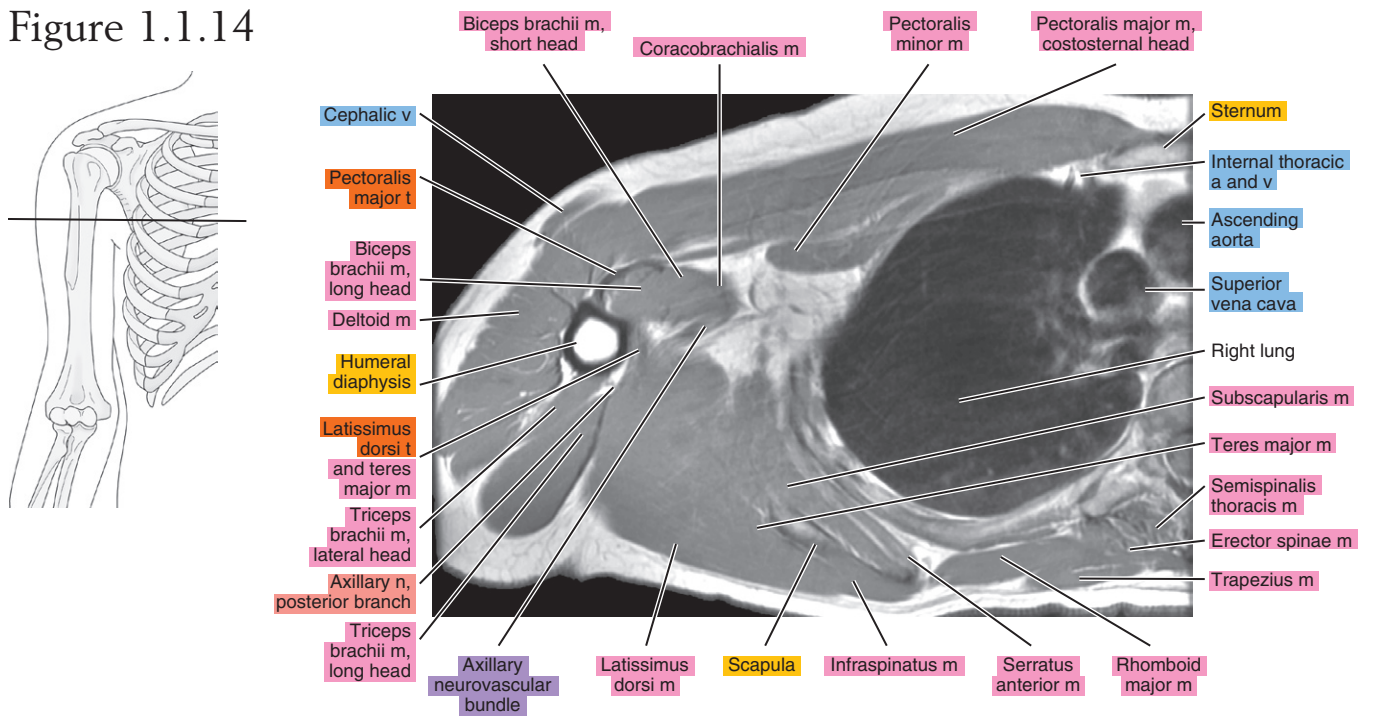


Figure 1.1.15

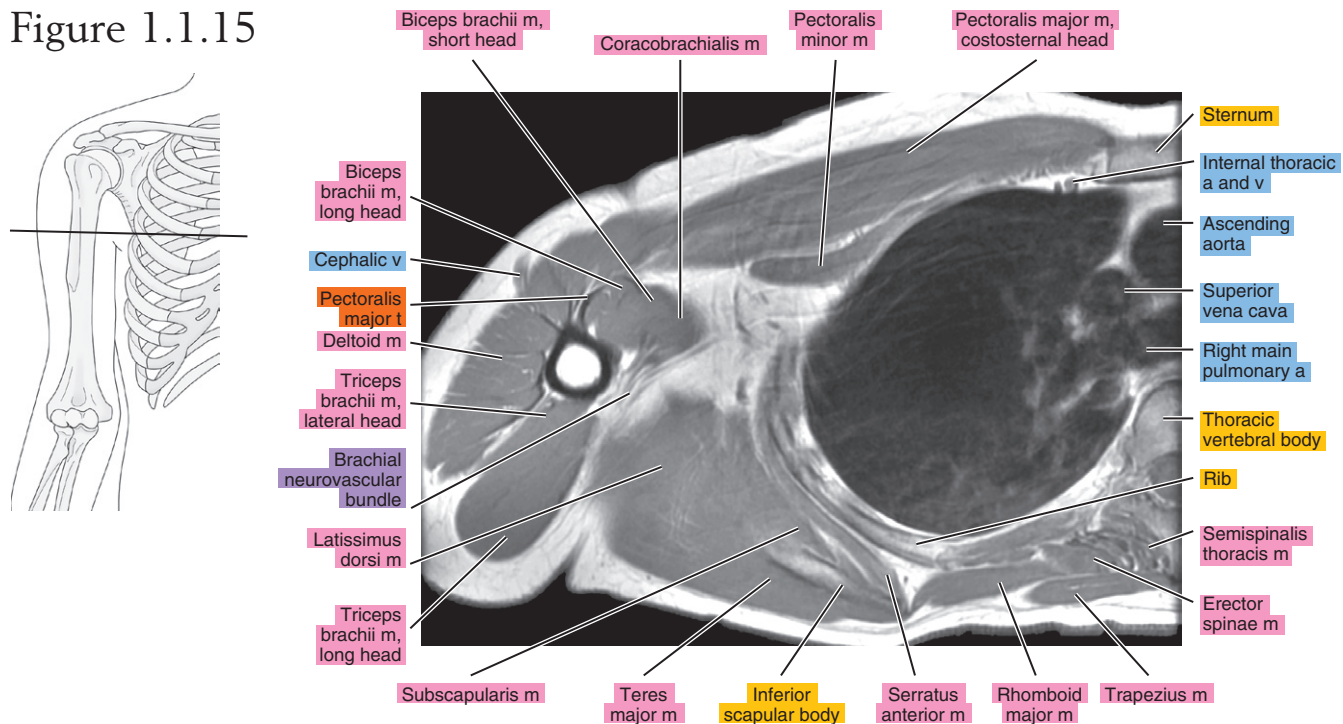


Figure 1.1.16

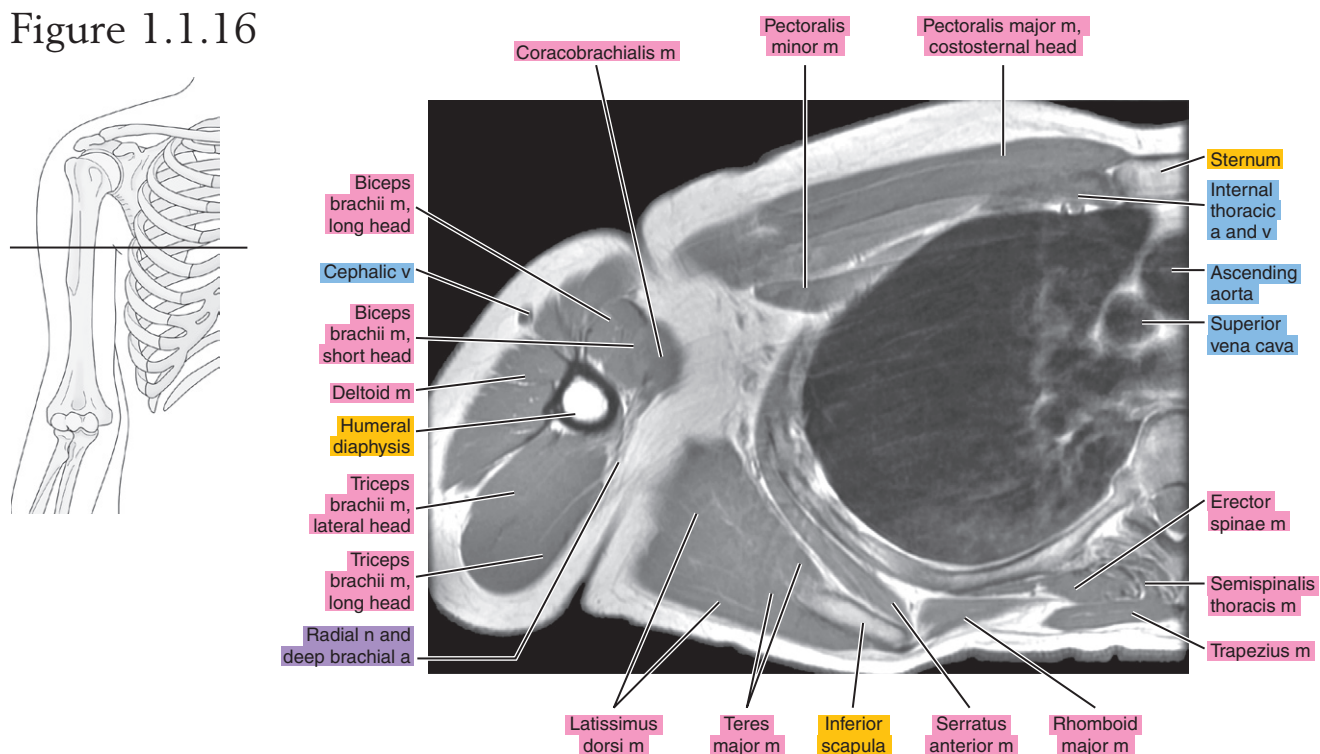


Figure 1.1.17

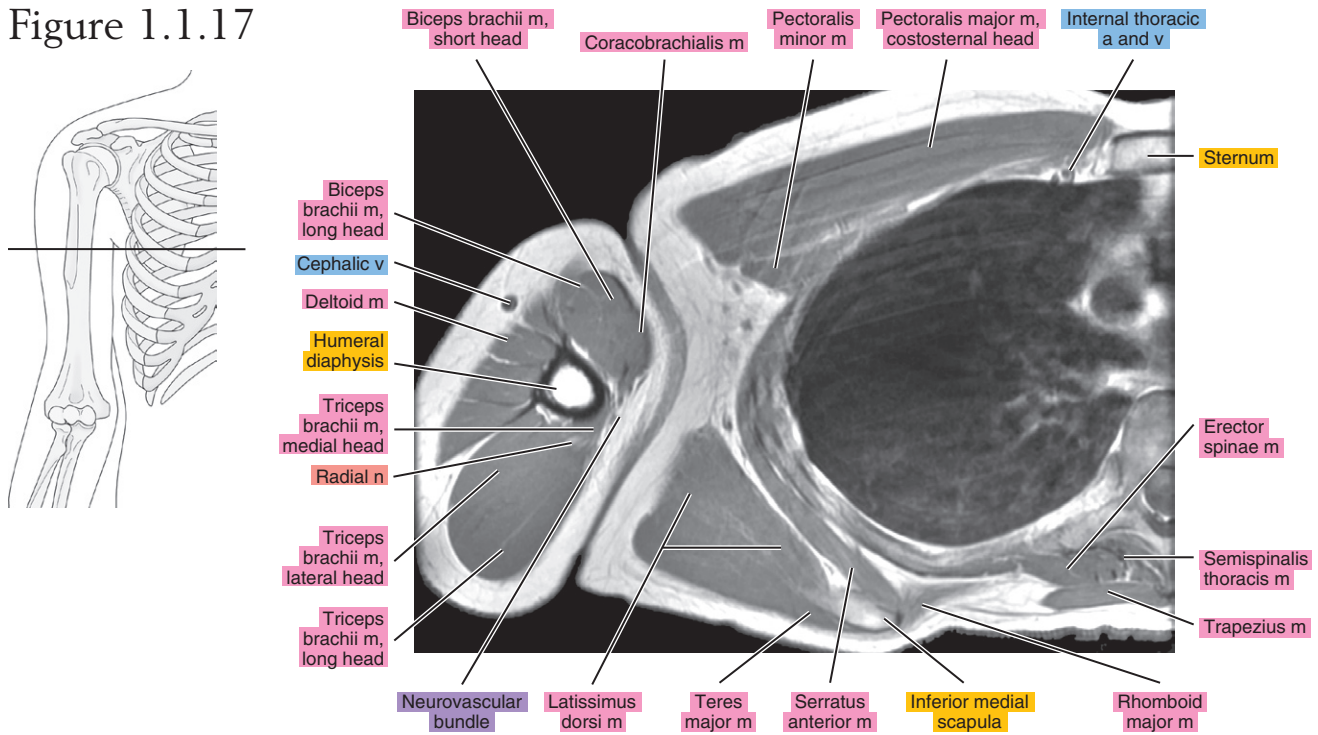


Figure 1.1.18

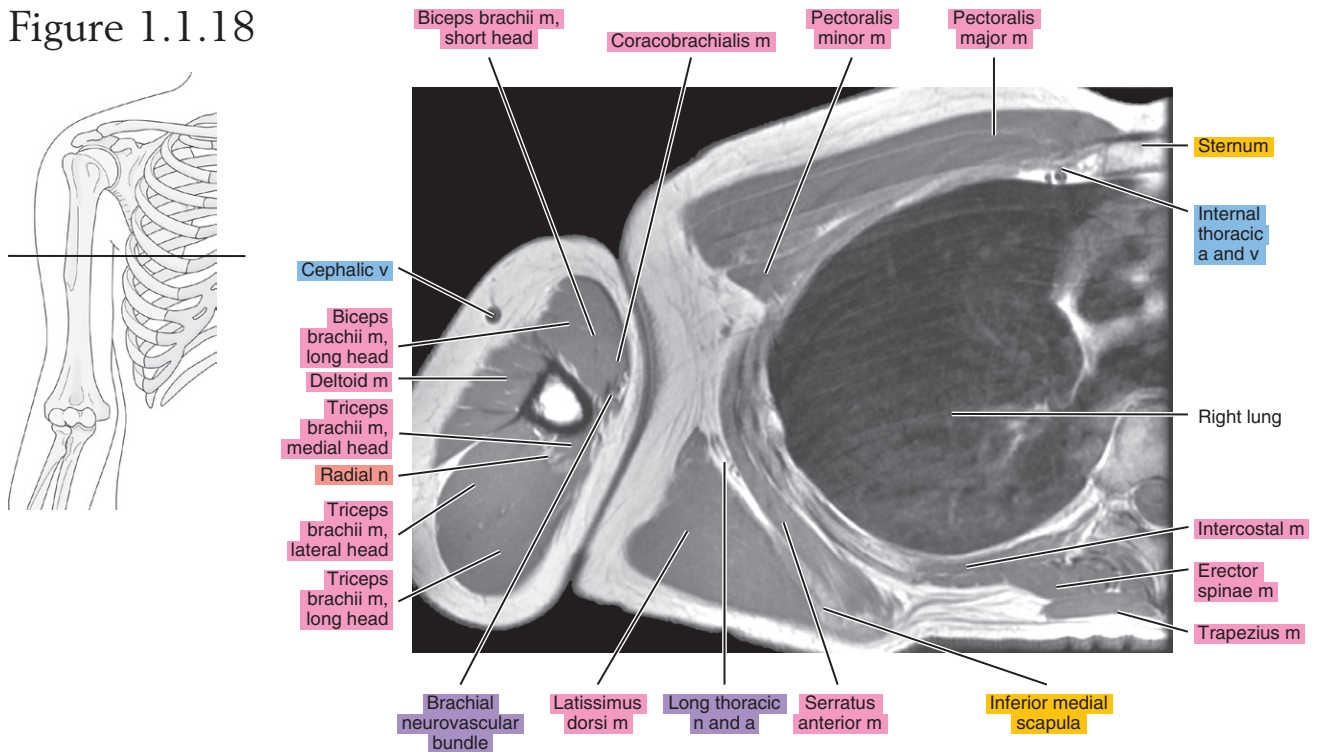
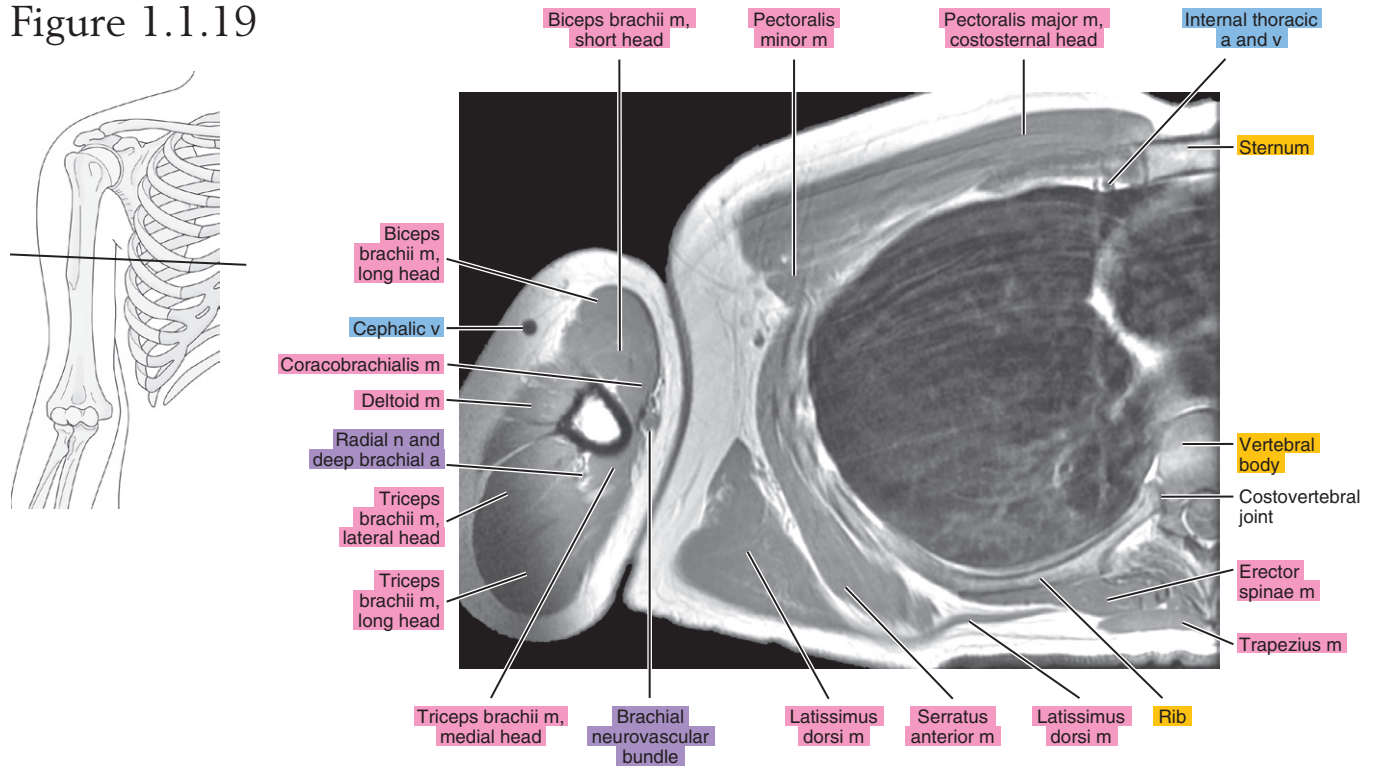


Figure 1.1.19



SAGITTAL

Figure 1.2.1

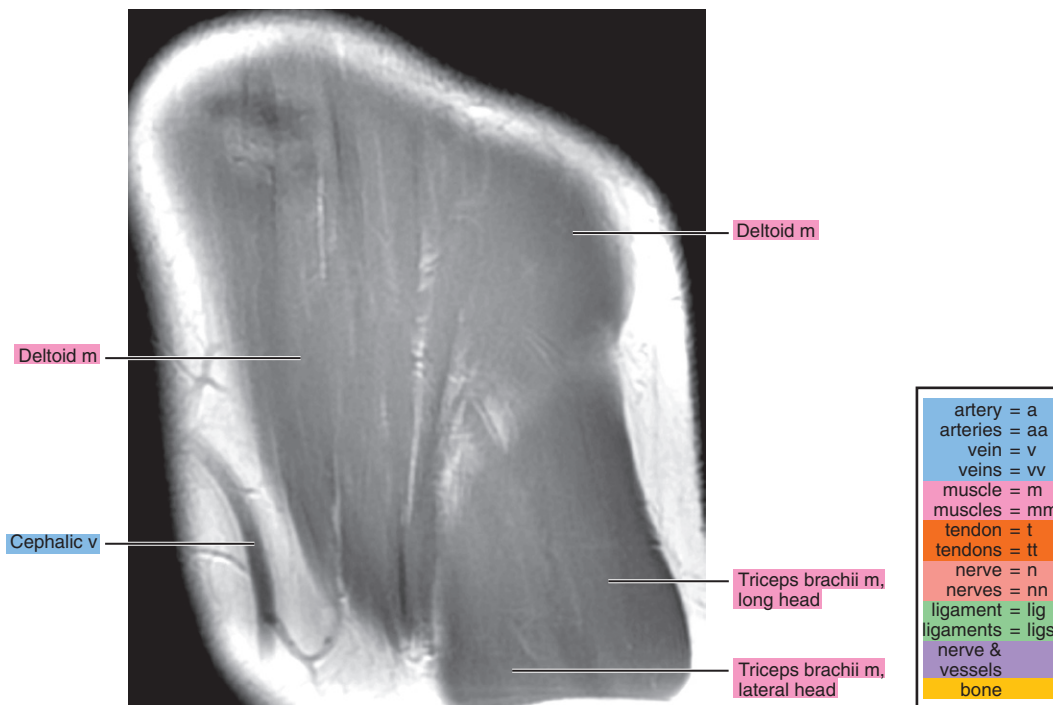
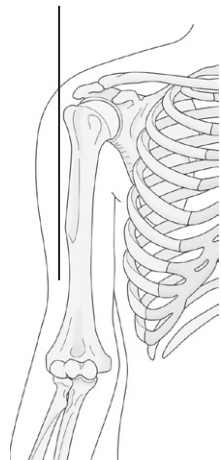


Figure 1.2.2

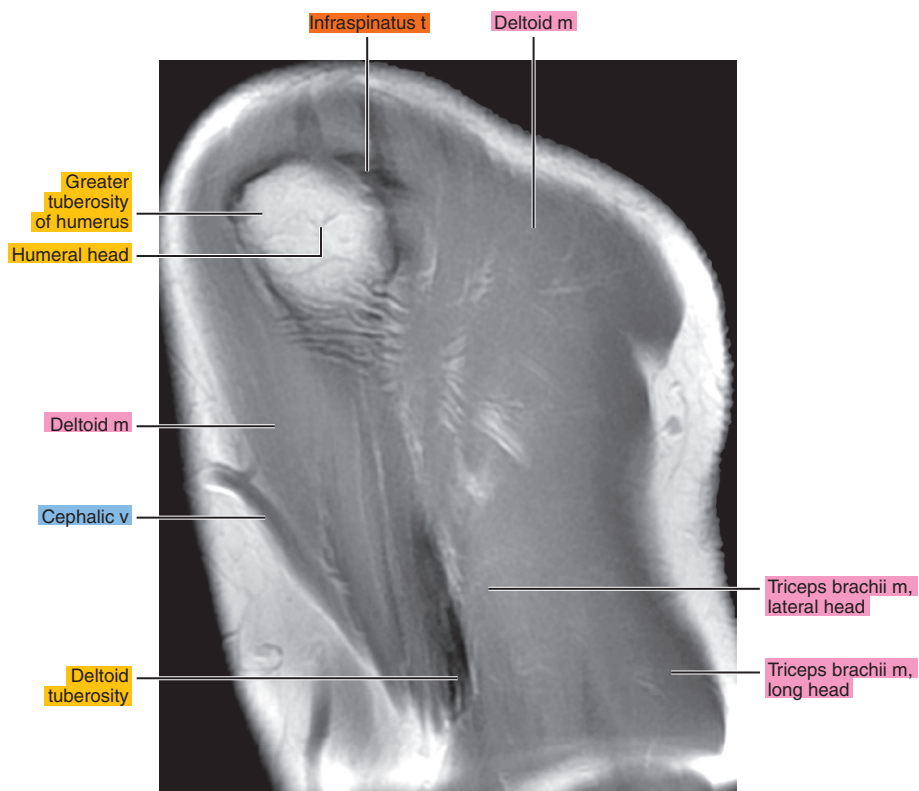
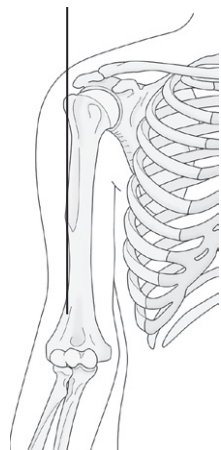


Figure 1.2.3

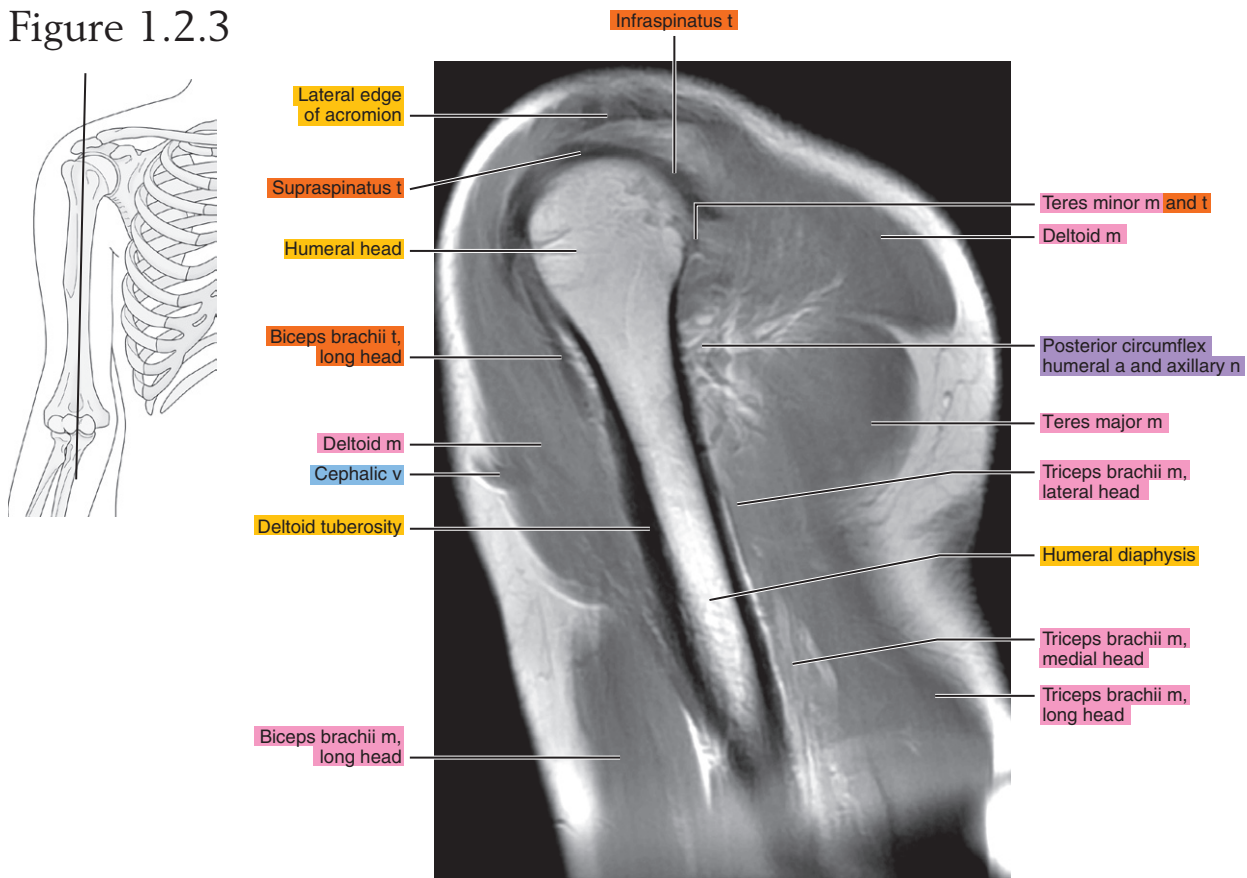


Figure 1.2.4

