

CAT VERSION



Elaine N. Marieb  
Lori A. Smith

# Human Anatomy & Physiology Laboratory Manual

TWELFTH EDITION

# Getting Started—What to Expect, The Scientific Method, and Metrics

Two hundred years ago, science was largely a plaything of wealthy patrons, but today's world is dominated by science and its technology. Whether or not we believe that such domination is desirable, we all have a responsibility to try to understand the goals and methods of science that have seeded this knowledge and technological explosion.

The biosciences are very special and exciting because they open the doors to an understanding of all the wondrous workings of living things. A course in human anatomy and physiology (a subdivision of bioscience) provides such insights in relation to your own body. Although some experience in scientific studies is helpful when beginning a study of anatomy and physiology, perhaps the single most important prerequisite is curiosity.

Gaining an understanding of science is a little like becoming acquainted with another person. Even though a written description can provide a good deal of information about the person, you can never really know another unless there is personal contact. And so it is with science—if you are to know it well, you must deal with it intimately.

The laboratory is the setting for “intimate contact” with science. It is where scientists test their ideas (do research), the essential purpose of which is to provide a basis from which predictions about scientific phenomena can be made. Likewise, it will be the site of your “intimate contact” with the subject of human anatomy and physiology as you are introduced to the methods and instruments used in biological research.

For many students, human anatomy and physiology is an introductory-level course; and their scientific background exists, at best, as a dim memory. If this is your predicament, this prologue may be just what you need to fill in a few gaps and to get you started on the right track before your actual laboratory experiences begin. So—let's get to it!

## The Scientific Method

Science would quickly stagnate if new knowledge were not continually derived from and added to it. The approach scientists commonly use when they investigate various aspects of their respective disciplines is called the **scientific method**. This method is *not* a single rigorous technique that must be followed in a lockstep manner. It is nothing more or less than a logical, practical, and reliable way of approaching and solving problems of every kind—scientific or otherwise—to gain knowledge. It includes five major steps.

### Step 1: Observation of Phenomena

The crucial first step involves observation of some phenomenon of interest. In other words, before a scientist can investigate anything, he or she must decide on a *problem* or focus for the investigation. In most college laboratory experiments, the problem or focus has been decided for you. However, to illustrate this important step, we will assume that you want

to investigate the true nature of apples, particularly green apples. In such a case you would begin your studies by making a number of different observations concerning apples.

### Step 2: Statement of the Hypothesis

Once you have decided on a focus of concern, the next step is to design a significant question to be answered. Such a question is usually posed in the form of a **hypothesis**, an unproven conclusion that attempts to explain some phenomenon. (At its crudest level, a hypothesis can be considered to be a “guess” or an intuitive hunch that tentatively explains some observation.) Generally, scientists do not restrict themselves to a single hypothesis; instead, they usually pose several and then test each one systematically.

We will assume that to accomplish step 1, you go to the supermarket and randomly select apples from several bins. When you later eat the apples, you find that the green apples are sour but that the red and yellow apples are sweet. From this observation, you might conclude (*hypothesize*) that “green apples are sour.” This statement would represent your current understanding of green apples. You might also reasonably predict that if you were to buy more apples, any green ones you buy will be sour. Thus, you would have gone beyond your initial observation that “these” green apples are sour to the prediction that “all” green apples are sour.

Any good hypothesis must meet several criteria. First, *it must be testable*. This characteristic is far more important than its being correct. The test data may or may not support the hypothesis, or new information may require that the hypothesis be modified. Clearly the accuracy of a prediction in any scientific study depends on the accuracy of the initial information on which it is based.

In our example, no great harm will come from an inaccurate prediction—that is, were we to find that some green apples are sweet. However, in some cases human life may depend on the accuracy of the prediction. For that and other reasons: (1) Repeated testing of scientific ideas is important, particularly because scientists working on the same problem do not always agree in their conclusions. (2) Careful observation is essential, even at the very outset of a study, because conclusions drawn from scientific tests are only as accurate as the information on which they are based.

A second criterion is that, even though hypotheses are guesses of a sort, *they must be based on measurable, describable facts. No mysticism can be theorized*. We cannot conjure up, to support our hypothesis, forces that have not been shown to exist. For example, as scientists, we cannot say that the tooth fairy took Johnny's tooth unless we can prove that the tooth fairy exists!

Third, a hypothesis *must not be anthropomorphic*. Human beings tend to anthropomorphize—that is, to relate all experiences to human experience. Whereas we could state that bears instinctively protect their young, it would be anthropomorphic to say that bears love their young, because love is a human emotional response. Thus, the initial hypothesis must be stated without interpretation.

### Step 3: Data Collection

Once the initial hypothesis has been stated, scientists plan experiments that will provide data (or evidence) to support or disprove their hypotheses—that is, they *test* their hypotheses. They accumulate data by making qualitative or quantitative observations of some sort. The observations are often aided by the use of various types of equipment such as cameras, microscopes, stimulators, or various electronic devices that allow chemical and physiological measurements to be taken.

Observations referred to as **qualitative** are those we can make with our senses—that is, by using our vision, hearing, or sense of taste, smell, or touch. For some quick practice in qualitative observation, compare and contrast an orange and an apple. (*Compare* means to emphasize the similarities between two things, whereas *contrast* means to emphasize the differences.)

Whereas the differences between an apple and an orange are obvious, this is not always the case in biological observations. Quite often a scientist tries to detect very subtle differences that cannot be determined by qualitative observations; data must be derived from measurements. Such observations based on precise measurements of one type or another are **quantitative observations**. Examples of quantitative observations include careful measurements of body or organ dimensions such as mass, size, and volume; measurement of volumes of oxygen consumed during metabolic studies; determination of the concentration of glucose in urine; and determination of the differences in blood pressure and pulse under conditions of rest and exercise. An apple and an orange could be compared quantitatively by analyzing the relative amounts of sugar and water in a given volume of fruit flesh, the pigments and vitamins present in the apple skin and orange peel, and so on.

A valuable part of data gathering is the use of experiments to support or disprove a hypothesis. An **experiment** is a procedure designed to describe the factors in a given situation that affect one another (that is, to discover cause and effect) under certain conditions.

Two general rules govern experimentation. The first of these rules is that the experiment(s) should be conducted in such a manner that every **variable** (any factor that might affect the outcome of the experiment) is under the control of the experimenter. The **independent variables** are manipulated by the experimenter. For example, if the goal is to determine the effect of body temperature on breathing rate, the independent variable is body temperature. The effect observed or value measured (in this case breathing rate) is called the **dependent** or **response variable**. Its value “depends” on the value chosen for the independent variable. The ideal way to perform such an experiment is to set up and run a series of tests that are all identical, except for one specific factor that is varied.

One specimen (or group of specimens) is used as the **control** against which all other experimental samples are compared. The importance of the control sample cannot be overemphasized. The control group provides the “normal standard” against which all other samples are compared relative to the dependent variable. Taking our example one step further, if we wanted to investigate the effects of body temperature (the independent variable) on breathing rate (the dependent variable), we could collect data on the breathing rate of individuals with “normal” body temperature (the

implicit control group), and compare these data to breathing-rate measurements obtained from groups of individuals with higher and lower body temperatures.

The second rule governing experimentation is that valid results require that testing be done on large numbers of subjects. It is essential to understand that it is nearly impossible to control all possible variables in biological tests. Indeed, there is a bit of scientific wisdom that mirrors this truth—that is, that laboratory animals, even in the most rigidly controlled and carefully designed experiments, “will do as they damn well please.” Thus, stating that the testing of a drug for its painkilling effects was successful after having tested it on only one postoperative patient would be scientific suicide. Large numbers of patients would have to receive the drug and be monitored for a decrease in postoperative pain before such a statement could have any scientific validity. Then, other researchers would have to be able to uphold those conclusions by running similar experiments. *Repeatability* is an important part of the scientific method and is the primary basis for support or rejection of many hypotheses.

During experimentation and observation, data must be carefully recorded. Usually, such initial, or raw, data are recorded in table form. The table should be labeled to show the variables investigated and the results for each sample. At this point, *accurate recording* of observations is the primary concern. Later, these raw data will be reorganized and manipulated to show more explicitly the outcome of the experimentation.

Some of the observations that you will be asked to make in the anatomy and physiology laboratory will require that a drawing be made. Don’t panic! The purpose of making drawings (in addition to providing a record) is to force you to observe things very closely. You need not be an artist (most biological drawings are simple outline drawings), but you do need to be neat and as accurate as possible. It is advisable to use a 4H pencil to do your drawings because it is easily erased and doesn’t smudge. Before beginning to draw, you should examine your specimen closely, studying it as though you were going to have to draw it from memory. For example, when looking at cells you should ask yourself questions such as “What is their shape—the relationship of length and width? How are they joined together?” Then decide precisely what you are going to show and how large the drawing must be to show the necessary detail. After making the drawing, add labels in the margins and connect them by straight lines (leader lines) to the structures being named.

### Step 4: Manipulation and Analysis of Data

The form of the final data varies, depending on the nature of the data collected. Usually, the final data represent information converted from the original measured values (raw data) to some other form. This may mean that averaging or some other statistical treatment must be applied, or it may require conversions from one kind of units to another. In other cases, graphs may be needed to display the data.

#### *Elementary Treatment of Data*

Only very elementary statistical treatment of data is required in this manual. For example, you will be expected to understand and/or compute an average (mean), percentages, and a range.

Two of these statistics, the mean and the range, are useful in describing the *typical* case among a large number of samples evaluated. Let us use a simple example. We will assume that the following heart rates (in beats/min) were recorded during an experiment: 64, 70, 82, 94, 85, 75, 72, 78. If you put these numbers in numerical order, the **range** is easily computed, because the range is the difference between the highest and lowest numbers obtained (highest number minus lowest number). The **mean** is obtained by summing the items and dividing the sum by the number of items. What is the range and the mean for the set of numbers just provided?

1. \_\_\_\_\_\*

The word *percent* comes from the Latin meaning “for 100”; thus *percent*, indicated by the percent sign, %, means parts per 100 parts. Thus, if we say that 45% of Americans have type O blood, what we are really saying is that among each group of 100 Americans, 45 (45/100) can be expected to have type O blood. Any ratio can be converted to a percent by multiplying by 100 and adding the percent sign.

$$.25 \times 100 = 25\% \quad 5 \times 100 = 500\%$$

It is very easy to convert any number (including decimals) to a percent. The rule is to move the decimal point two places to the right and add the percent sign. If no decimal point appears, it is *assumed* to be at the end of the number; and zeros are added to fill any empty spaces. Two examples follow:

$$0.25 = 0.25 = 25\%$$

$$5 = 5 = 500\%$$

Change the following to percents:

2. 38 = \_\_\_\_\_      4. 1.6 = \_\_\_\_\_

3. .75 = \_\_\_\_\_

Note that although you are being asked here to convert numbers to percents, percents by themselves are meaningless. We always speak in terms of a percentage *of* something.

To change a percent to decimal form, remove the percent sign, and divide by 100. Change the following percents to whole numbers or decimals:

5. 800% = \_\_\_\_\_      6. 0.05% = \_\_\_\_\_

### Making and Reading Line Graphs

For some laboratory experiments you will be required to show your data (or part of them) graphically. Simple line graphs allow relationships within the data to be shown interestingly and allow trends (or patterns) in the data to be demonstrated. An advantage of properly drawn graphs is that they save the reader’s time because the essential meaning of a large amount of statistical data can be seen at a glance.

To aid in making accurate graphs, graph paper (or a printed grid in the manual) is used. Line graphs have both horizontal (X) and vertical (Y) axes with scales. Each scale

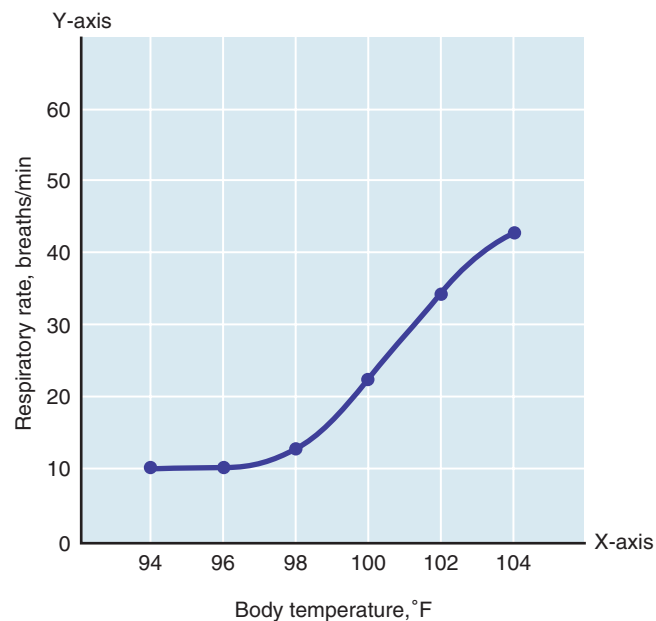
should have uniform intervals—that is, each unit measured on the scale should require the same distance along the scale as any other. Variations from this rule may be misleading and result in false interpretations of the data. By convention, the condition that is manipulated (the independent variable) in the experimental series is plotted on the X-axis (the horizontal axis); and the value that we then measure (the dependent variable) is plotted on the Y-axis (the vertical axis). To plot the data, a dot or a small x is placed at the precise point where the two variables (measured for each sample) meet; and then a line (this is called the **curve**) is drawn to connect the plotted points.

Sometimes, you will see the curve on a line graph extended beyond the last plotted point. This is (supposedly) done to predict “what comes next.” When you see this done, be skeptical. The information provided by such a technique is only slightly more accurate than that provided by a crystal ball! When constructing a graph, be sure to label the X-axis and Y-axis and give the graph a legend (**Figure 1**).

To read a line graph, pick any point on the line, and match it with the information directly below on the X-axis and with that directly to the left of it on the Y-axis. The figure below (Figure 1) is a graph that illustrates the relationship between breaths per minute (respiratory rate) and body temperature. Answer the following questions about this graph:

7. What was the respiratory rate at a body temperature of 96°F? \_\_\_\_\_

8. Between which two body temperature readings was the increase in breaths per minute greatest? \_\_\_\_\_



**Figure 1** Example of graphically presented data. Respiratory rate as a function of body temperature.

\*Answers are given at the end of this section (page xx).

## Step 5: Reporting Conclusions of the Study

Drawings, tables, and graphs alone do not suffice as the final presentation of scientific results. The final step requires that you provide a straightforward description of the conclusions drawn from your results. If possible, your findings should be compared to those of other investigators working on the same problem. For laboratory investigations conducted by students, these comparative figures are provided by classmates.

It is important to realize that scientific investigations do not always yield the anticipated results. If there are discrepancies between your results and those of others, or what you expected to find based on your class notes or textbook readings, this is the place to try to explain those discrepancies.

Results are often only as good as the observation techniques used. Depending on the type of experiment conducted, you may need to answer several questions. Did you weigh the specimen carefully enough? Did you balance the scale first? Was the subject's blood pressure actually as high as you recorded it, or did you record it inaccurately? If you did record it accurately, is it possible that the subject was emotionally upset about something, which might have given falsely high data for the variable being investigated? Attempting to explain an unexpected result will often teach you more than you would have learned from anticipated results.

When the experiment produces results that are consistent with the hypothesis, then the hypothesis can be said to have

reached a higher level of certainty. The probability that the hypothesis is correct is greater.

A hypothesis that has been validated by many different investigators is called a **theory**. Theories are useful in two important ways. First, they link sets of data; and second, they make predictions that may lead to additional avenues of investigation. (OK, we know this with a high degree of certainty; what's next?)

When a theory has been repeatedly verified and appears to have wide applicability in biology, it may assume the status of a **biological principle**. A principle is a statement that applies with a high degree of probability to a range of events. For example, "Living matter is made of cells or cell products" is a principle stated in many biology texts. It is a sound and useful principle, and will continue to be used as such—unless new findings prove it wrong.

We have been through quite a bit of background concerning the scientific method and what its use entails. Because it is important that you remember the phases of the scientific method, they are summarized here:

1. Observation of some phenomenon
2. Statement of a hypothesis (based on the observations)
3. Collection of data (testing the hypothesis with controlled experiments)
4. Manipulation and analysis of the data
5. Reporting of the conclusions of the study (routinely done by preparing a lab report—see page xvii)

## Lab Report

### Cover Page

- Title of Experiment
- Author's Name
- Course
- Instructor
- Date

### Introduction

- Provide background information.
- Describe any relevant observations.
- State hypotheses clearly.

### Materials and Methods

- List equipment or supplies needed.
- Provide step-by-step directions for conducting the experiment.

### Results

- Present data using a drawing (figure), table, or graph.
- Analyze data.
- Summarize findings briefly.

### Discussion and Conclusions

- Conclude whether data gathered support or do not support hypotheses.
- Include relevant information from other sources.
- Explain any uncontrolled variables or unexpected difficulties.
- Make suggestions for further experimentation.

### Reference List

- Cite the source of any material used to support this report.

## Writing a Lab Report Based on The Scientific Method

A laboratory report is not the same as a scientific paper, but it has some of the same elements and is a formal way to report the results of a scientific experiment. The report should have a cover page that includes the title of the experiment, the author's name, the name of the course, the instructor, and the date. The report should include five separate, clearly marked sections: Introduction, Materials and Methods, Results, Discussion and Conclusions, and References. Use the previous template to guide you through writing a lab report.

### Metrics

No matter how highly developed our ability to observe, observations have scientific value only if we can communicate them to others. Without measurement, we would be limited to qualitative description. For precise and repeatable communication of information, the agreed-upon system of measurement used by scientists is the **metric system**.

A major advantage of the metric system is that it is based on units of 10. This allows rapid conversion to workable numbers so that neither very large nor very small figures need be used in calculations. Fractions or multiples of the standard units of length, volume, mass, time, and temperature have been assigned specific names. The metric system (**Table 1**) shows the commonly used units of the metric system, along with the prefixes used to designate fractions and multiples thereof.

To change from smaller units to larger units, you must *divide* by the appropriate factor of 10 (because there are fewer of the larger units). For example, a milliunit (*milli* = one-thousandth), such as a millimeter, is one step smaller than a centiunit (*centi* = one-hundredth), such as a centimeter. Thus to change milliunits to centiunits, you must divide by 10. On the other hand, when converting from larger units to smaller ones, you must *multiply* by the appropriate factor of 10. A partial scheme for conversions between the metric units is shown on the next page.

The objectives of the sections that follow are to provide a brief overview of the most-used measurements in science or health professions and to help you gain some measure of confidence in dealing with them. A listing of the most frequently used conversion factors, for conversions between British and metric system units, is provided on the inside back cover.

### Length Measurements

The metric unit of length is the **meter (m)**. Smaller objects are measured in centimeters or millimeters. Subcellular structures are measured in micrometers.

To help you picture these units of length, some equivalents follow:

One meter (m) is slightly longer than one yard (1 m = 39.37 in.).

One centimeter (cm) is approximately the width of a piece of chalk. (Note: There are 2.54 cm in 1 in.)

One millimeter (mm) is approximately the thickness of the wire of a paper clip or of a mark made by a No. 2 pencil lead.

One micrometer ( $\mu\text{m}$ ) is extremely tiny and can be measured only microscopically.

Make the following conversions between metric units of length:

9. 12 cm = \_\_\_\_\_ mm

10. 2000  $\mu\text{m}$  = \_\_\_\_\_ mm

Now, circle the answer that would make the most sense in each of the following statements:

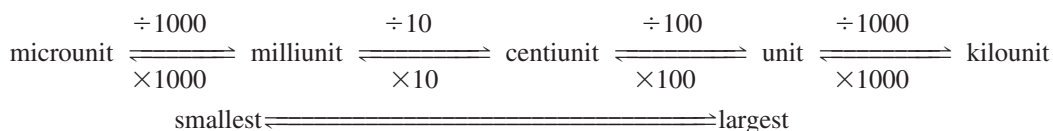
11. A match (in a matchbook) is (0.3, 3, 30) cm long.

12. A standard-size American car is about 4 (mm, cm, m, km) long.

**Table 1** Metric System

A. Commonly used units		B. Fractions and their multiples		
Measurement	Unit	Fraction or multiple	Prefix	Symbol
Length	Meter (m)	$10^6$ one million	mega	M
Volume	Liter (L; l with prefix)	$10^3$ one thousand	kilo	k
Mass	Gram (g)	$10^{-1}$ one-tenth	deci	d
Time*	Second (s)	$10^{-2}$ one-hundredth	centi	c
Temperature	Degree Celsius ( $^{\circ}\text{C}$ )	$10^{-3}$ one-thousandth	milli	m
		$10^{-6}$ one-millionth	micro	$\mu$
		$10^{-9}$ one-billionth	nano	n

\* The accepted standard for time is the second; and thus hours and minutes are used in scientific, as well as everyday, measurement of time. The only prefixes generally used are those indicating *fractional portions* of seconds—for example, millisecond and microsecond.



### Volume Measurements

The metric unit of volume is the liter. A **liter** (l, or sometimes L, especially without a prefix) is slightly more than a quart (1 L = 1.057 quarts). Liquid volumes measured out for lab experiments are usually measured in milliliters (ml). (The terms *ml* and *cc*, cubic centimeter, are used interchangeably in laboratory and medical settings.)

To help you visualize metric volumes, the equivalents of some common substances follow:

A 12-oz can of soda is a little less than 360 ml.

A fluid ounce is about 30 (it's 29.57) ml (cc).

A teaspoon of vanilla is about 5 ml (cc).

Compute the following:

13. How many 5-ml injections can be prepared from 1 liter

of a medicine? \_\_\_\_\_

14. A 450-ml volume of alcohol is \_\_\_\_\_ L.

### Mass Measurements

Although many people use the terms *mass* and *weight* interchangeably, this usage is inaccurate. **Mass** is the amount of matter in an object; and an object has a constant mass, regardless of where it is—that is, on earth, or in outer space. However, weight varies with gravitational pull; the greater the gravitational pull, the greater the weight. Thus, our astronauts are said to be weightless when in outer space, but they still have the same mass as they do on earth. (Astronauts are not *really* weightless. It is just that they and their surroundings are being pulled toward the earth at the same speed; and so, in reference to their environment, they appear to float.)

The metric unit of mass is the **gram (g)**. Medical dosages are usually prescribed in milligrams (mg) or micrograms ( $\mu\text{g}$ ); and in the clinical agency, body weight (particularly of infants) is typically specified in kilograms (kg; 1 kg = 2.2 lb).

The following examples are provided to help you become familiar with the masses of some common objects:

Two aspirin tablets have a mass of approximately 1 g.

A nickel has a mass of 5 g.

The mass of an average woman (132 lb) is 60 kg.

Make the following conversions:

15.  $300 \text{ g} = \text{_____ mg} = \text{_____ } \mu\text{g}$

16.  $4000 \text{ } \mu\text{g} = \text{_____ mg} = \text{_____ g}$

17. A nurse must administer to her patient, Mrs. Smith, 5 mg of a drug per kg of body mass. Mrs. Smith weighs 140 lb. How many grams of the drug should the nurse administer to her patient?

\_\_\_\_\_ g

### Temperature Measurements

In the laboratory and in the clinical agency, temperature is measured both in metric units (degrees Celsius,  $^{\circ}\text{C}$ ) and in British units (degrees Fahrenheit,  $^{\circ}\text{F}$ ). Thus it helps to be familiar with both temperature scales.

The temperatures of boiling and freezing water can be used to compare the two scales:

The freezing point of water is  $0^{\circ}\text{C}$  and  $32^{\circ}\text{F}$ .

The boiling point of water is  $100^{\circ}\text{C}$  and  $212^{\circ}\text{F}$ .

As you can see, the range from the freezing point to the boiling point of water on the Celsius scale is 100 degrees, whereas the comparable range on the Fahrenheit scale is 180 degrees. Hence, one degree on the Celsius scale represents a greater change in temperature. Normal body temperature is approximately  $98.6^{\circ}\text{F}$  or  $37^{\circ}\text{C}$ .

To convert from the Celsius scale to the Fahrenheit scale, the following equation is used:

$$^{\circ}\text{C} = \frac{5(^{\circ}\text{F} - 32)}{9}$$

To convert from the Fahrenheit scale to the Celsius scale, the following equation is used:

$$^{\circ}\text{F} = (9/5)^{\circ}\text{C} + 32$$

Perform the following temperature conversions:

18. Convert  $38^{\circ}\text{C}$  to  $^{\circ}\text{F}$ : \_\_\_\_\_

19. Convert  $158^{\circ}\text{F}$  to  $^{\circ}\text{C}$ : \_\_\_\_\_

## Answers

1. range of 94–64 or 30 beats/min; mean 77.5 2. 3800% 3. 75% 4. 160% 5. 8 6. 0.0005 7. 10 breaths/min  
 8. interval between  $100\text{--}102^{\circ}$  (went from 22 to 36 breaths/min) 9. 12 cm = 120 mm 10.  $2000 \mu\text{m} = 2 \text{ mm}$  11. 3 cm long  
 12. 4 m long 13. 200 14. 0.45 L 15.  $300 \text{ g} = 3 \times 10^5 \text{ mg} = 3 \times 10^8 \mu\text{g}$  16.  $4000 \mu\text{g} = 4 \text{ mg} = 4 \times 10^{-3} \text{ g}$  (0.004 g)  
 17. 0.32 g 18.  $100.4^{\circ}\text{F}$  19.  $70^{\circ}\text{C}$

CAT VERSION



**Elaine N. Marieb, R.N., Ph.D.**  
Holyoke Community College

**Lori A. Smith, Ph.D.**  
American River College

# Human Anatomy & Physiology Laboratory Manual

TWELFTH EDITION

PhysioEx™ Version 9.1 authored by  
Peter Z. Zao North Idaho College  
Timothy Stabler, Ph.D. Indiana University Northwest  
Lori A. Smith, Ph.D. American River College  
Andrew Lokuta, Ph.D. University of Wisconsin–Madison  
Edwin Griff, Ph.D. University of Cincinnati

PEARSON



Editor-in-Chief: Serina Beauparlant  
Senior Acquisitions Editor: Brooke Suchomel  
Program Manager: Shannon Cutt  
Program Manager Team Lead: Michael Early  
Director of Development: Barbara Yien  
Development Editor: Lisa Clark  
Editorial Assistant: Arielle Grant  
Production Project and Design Manager: Michele Mangelli  
Project Manager Team Lead: Nancy Tabor  
Production Supervisor: Janet Vail

Art and Photo Coordinator: David Novak  
Photo Researcher: Kristin Piljay  
Interior and Cover Designer: tani hasegawa  
Copyeditor: Sally Peyrefitte  
Compositor: Cengage® Publisher Services  
Media Producers: Liz Winer and Lauren Hill  
PhysioEx Developer: BinaryLabs, Inc.  
Senior Manufacturing Buyer: Stacey Weinberger  
Senior Marketing Manager: Allison Rona  
Senior Anatomy & Physiology Specialist: Derek Perrigo

Cover photographs: Pole vaulter, Pete Saloutos/Getty Images; Sky, Gregor Schuster/Getty Images

Acknowledgments of third-party content appear on page BM-1, which constitutes an extension of this copyright page.

Copyright © 2016, 2014, 2012. Pearson Education, Inc. All Rights Reserved. Printed in the United States of America. This publication is protected by copyright, and permission should be obtained from the publisher prior to any prohibited reproduction, storage in a retrieval system, or transmission in any form or by any means, electronic, mechanical, photocopying, recording, or otherwise. For information regarding permissions, request forms and the appropriate contacts within the Pearson Education Global Rights & Permissions department, please visit [www.pearsoned.com/permissions/](http://www.pearsoned.com/permissions/).

PEARSON, ALWAYS LEARNING, MasteringA&P®, A&PFlix™, PAL™, and PEx™ are exclusive trademarks, in the U.S. and/or other countries, owned by Pearson Education, Inc. or its affiliates.

Unless otherwise indicated herein, any third-party trademarks that may appear in this work are the property of their respective owners and any references to third-party trademarks, logos or other trade dress are for demonstrative or descriptive purposes only. Such references are not intended to imply any sponsorship, endorsement, authorization, or promotion of Pearson's products by the owners of such marks, or any relationship between the owner and Pearson Education, Inc. or its affiliates, authors, licensees or distributors.

The Authors and Publisher believe that the lab experiments described in this publication, when conducted in conformity with the safety precautions described herein and according to the school's laboratory safety procedures, are reasonably safe for the student to whom this manual is directed. Nonetheless, many of the described experiments are accompanied by some degree of risk, including human error, the failure or misuses of laboratory or electrical equipment, mismeasurement, chemical spills, and exposure to sharp objects, heat, bodily fluids, blood, or other biologics. The Authors and Publisher disclaim any liability arising from such risks in connection with any of the experiments contained in this manual. If students have any questions or problems with materials, procedures, or instructions on any experiment, they should always ask their instructor for help before proceeding.

ISBN 10: 0-321-97135-3 (student edition)  
ISBN 13: 978-0-321-97135-7 (student edition)  
ISBN 10: 0-13-399927-0 (instructor's review copy)  
ISBN 13: 978-0-13-399927-3 (instructor's review copy)

**PEARSON**

[www.pearsonhighered.com](http://www.pearsonhighered.com)

1 2 3 4 5 6 7 8 9 10—V364—18 17 16 15 14

# Contents

## THE HUMAN BODY: AN ORIENTATION

- 1 The Language of Anatomy 1**
- 1 Locating Body Regions 3
  - 2 Practicing Using Correct Anatomical Terminology 4
  - 3 Observing Sectioned Specimens 6
  - 4 Identifying Organs in the Abdominopelvic Cavity 8
  - 5 Locating Abdominal Surface Regions 8
- Group Challenge** The Language of Anatomy 10
- Review Sheet** 11

- 2 Organ Systems Overview 15**
- 1 Observing External Structures 17
  - 2 Examining the Oral Cavity 17
  - 3 Opening the Ventral Body Cavity 17
  - 4 Examining the Ventral Body Cavity 18
  - 5 Examining the Human Torso Model 23
- Group Challenge** Odd Organ Out 24
- Review Sheet** 25

## THE MICROSCOPE AND ITS USES

- 3 The Microscope 27**
- 1 Identifying the Parts of a Microscope 28
  - 2 Viewing Objects Through the Microscope 29
  - 3 Estimating the Diameter of the Microscope Field 32
  - 4 Perceiving Depth 33
  - 5 Preparing and Observing a Wet Mount 33
- Review Sheet** 35

## THE CELL

- 4 The Cell: Anatomy and Division 39**
- 1 Identifying Parts of a Cell 40
  - 2 Identifying Components of a Plasma Membrane 41
  - 3 Locating Organelles 42
  - 4 Examining the Cell Model 42
  - 5 Observing Various Cell Structures 43
  - 6 Identifying the Mitotic Stages 45
  - 7 “Chenille Stick” Mitosis 45
- Review Sheet** 49

**5 The Cell: Transport Mechanisms and Cell Permeability 53**

- 1 Observing Diffusion of Dye Through Agar Gel 55
  - 2 Observing Diffusion of Dye Through Water 56
  - 3 Investigating Diffusion and Osmosis Through Nonliving Membranes 56
  - 4 Observing Osmometer Results 58
  - 5 Investigating Diffusion and Osmosis Through Living Membranes 58
  - 6 Observing the Process of Filtration 60
  - 7 Observing Phagocytosis 62
- Group Challenge** Compare and Contrast Membrane Transport Processes 62
- Review Sheet** 63

## HISTOLOGY: BASIC TISSUES OF THE BODY

**6 Classification of Tissues 67**

- 1 Examining Epithelial Tissue Under the Microscope 74
- Group Challenge 1** Identifying Epithelial Tissues 74
- 2 Examining Connective Tissue Under the Microscope 76
  - 3 Examining Nervous Tissue Under the Microscope 82
  - 4 Examining Muscle Tissue Under the Microscope 83
- Group Challenge 2** Identifying Connective Tissue 86
- Review Sheet** 87

## THE INTEGUMENTARY SYSTEM

**7 The Integumentary System 93**

- 1 Locating Structures on a Skin Model 95
  - 2 Identifying Nail Structures 98
  - 3 Comparing Hairy and Relatively Hair-Free Skin Microscopically 98
  - 4 Differentiating Sebaceous and Sweat Glands Microscopically 100
  - 5 Plotting the Distribution of Sweat Glands 100
  - 6 Taking and Identifying Inked Fingerprints 101
- Review Sheet** 103

## THE SKELETAL SYSTEM

- 8 Overview of the Skeleton: Classification and Structure of Bones and Cartilages 107**
- 1 Examining a Long Bone 111
  - 2 Examining the Effects of Heat and Hydrochloric Acid on Bones 112
  - 3 Examining the Microscopic Structure of Compact Bone 113
  - 4 Examining the Osteogenic Epiphyseal Plate 115
- [Review Sheet](#) 117

- 9 The Axial Skeleton 121**
- 1 Identifying the Bones of the Skull 122
- Group Challenge** Odd Bone Out 131
- 2 Palpating Skull Markings 133
  - 3 Examining Spinal Curvatures 134
  - 4 Examining Vertebral Structure 138
  - 5 Examining the Relationship Between Ribs and Vertebrae 139
  - 6 Examining a Fetal Skull 140
- [Review Sheet](#) 141


- 10 The Appendicular Skeleton 149**
- 1 Examining and Identifying Bones of the Appendicular Skeleton 150
  - 2 Palpating the Surface Anatomy of the Pectoral Girdle and Upper Limb 152
  - 3 Observing Pelvic Articulations 155
  - 4 Comparing Male and Female Pelves 157
  - 5 Palpating the Surface Anatomy of the Pelvic Girdle and Lower Limb 161
  - 6 Constructing a Skeleton 162
- [Review Sheet](#) 163

- 11 Articulations and Body Movements 171**
- 1 Identifying Fibrous Joints 172
  - 2 Identifying Cartilaginous Joints 172
  - 3 Examining Synovial Joint Structure 174
  - 4 Demonstrating the Importance of Friction-Reducing Structures 174
  - 5 Demonstrating Movements of Synovial Joints 176
  - 6 Demonstrating Actions at the Hip Joint 178
  - 7 Demonstrating Actions at the Knee Joint 179
  - 8 Demonstrating Actions at the Shoulder Joint 181
  - 9 Examining the Action at the TMJ 182
- Group Challenge** Articulations: “Simon Says” 184
- [Review Sheet](#) 185

## THE MUSCULAR SYSTEM

- 12 Microscopic Anatomy and Organization of Skeletal Muscle 189**
- 1 Examining Skeletal Muscle Cell Anatomy 192
  - 2 Observing the Histological Structure of a Skeletal Muscle 192
  - 3 Studying the Structure of a Neuromuscular Junction 193
- [Review Sheet](#) 195

- 13 Gross Anatomy of the Muscular System 199**
- 1 Identifying Head and Neck Muscles 201
  - 2 Identifying Muscles of the Trunk 201
  - 3 Identifying Muscles of the Upper Limb 215
  - 4 Identifying Muscles of the Lower Limb 220
- Group Challenge** Name That Muscle 224
- 5 Review of Human Musculature 226
  - 6 Making a Muscle Painting 226
- [Review Sheet](#) 229

- 14 Skeletal Muscle Physiology: Frogs and Human Subjects 237**
- 1 Observing Muscle Fiber Contraction 238
  - 2 Inducing Contraction in the Frog Gastrocnemius Muscle 240
  - 3 Demonstrating Muscle Fatigue in Humans 245
-  **4** Electromyography in a Human Subject Using BIOPAC® 246
- [Review Sheet](#) 253

## THE NERVOUS SYSTEM


- 15 Histology of Nervous Tissue 257**
- 1 Identifying Parts of a Neuron 260
  - 2 Studying the Microscopic Structure of Selected Neurons 262
  - 3 Examining the Microscopic Structure of a Nerve 264
- [Review Sheet](#) 265

- 16 Neurophysiology of Nerve Impulse: Frog Subjects 269**
- 1 Stimulating the Nerve 272
  - 2 Inhibiting the Nerve 273
  - 3 Visualizing the Compound Action Potential with an Oscilloscope 274
- [Review Sheet](#) 277

## 17 Gross Anatomy of the Brain and Cranial Nerves 279

- 1 Identifying External Brain Structures 281
  - 2 Identifying Internal Brain Structures 283
  - 3 Identifying and Testing the Cranial Nerves 288
- Group Challenge** Odd (Cranial) Nerve Out 296
- Review Sheet** 297


## 18 Electroencephalography 303

- 1 Observing Brain Wave Patterns Using an Oscilloscope or Physiograph 304
-  **2** Electroencephalography Using BIOPAC® 305
- Review Sheet** 309


## 19 The Spinal Cord and Spinal Nerves 311

- 1 Identifying Structures of the Spinal Cord 312
  - 2 Identifying Spinal Cord Tracts 315
  - 3 Identifying the Major Nerve Plexuses and Peripheral Nerves 322
- Group Challenge** Fix the Sequence 322
- Review Sheet** 323

## 20 The Autonomic Nervous System 327

- 1 Locating the Sympathetic Trunk 328
  - 2 Comparing Sympathetic and Parasympathetic Effects 330
-  **3** Exploring the Galvanic Skin Response (Electrodermal Activity) Within a Polygraph Using BIOPAC® 330
- Review Sheet** 337

## 21 Human Reflex Physiology 339

- 1 Initiating Stretch Reflexes 341
  - 2 Initiating the Crossed-Extensor Reflex 343
  - 3 Initiating the Plantar Reflex 343
  - 4 Initiating the Corneal Reflex 344
  - 5 Initiating the Gag Reflex 344
  - 6 Initiating Pupillary Reflexes 345
  - 7 Initiating the Ciliospinal Reflex 345
  - 8 Initiating the Salivary Reflex 345
  - 9 Testing Reaction Time for Intrinsic and Learned Reflexes 346
-  **10** Measuring Reaction Time Using BIOPAC® 347
- Review Sheet** 349

## 22 General Sensation 353

- 1 Studying the Structure of Selected Sensory Receptors 355
- 2 Determining the Two-Point Threshold 356
- 3 Testing Tactile Localization 357
- 4 Demonstrating Adaptation of Touch Receptors 357
- 5 Demonstrating Adaptation of Temperature Receptors 357

- 6 Demonstrating the Phenomenon of Referred Pain 358
- Review Sheet** 359

## 23 Special Senses: Anatomy of the Visual System 361

- 1 Identifying Accessory Eye Structures 363
  - 2 Identifying Internal Structures of the Eye 363
  - 3 Studying the Microscopic Anatomy of the Retina 364
  - 4 Predicting the Effects of Visual Pathway Lesions 368
- Review Sheet** 369

## 24 Special Senses: Visual Tests and Experiments 373

- 1 Demonstrating the Blind Spot 373
  - 2 Determining Near Point of Accommodation 374
  - 3 Testing Visual Acuity 375
  - 4 Testing for Astigmatism 376
  - 5 Testing for Color Blindness 376
  - 6 Testing for Depth Perception 377
  - 7 Demonstrating Reflex Activity of Intrinsic and Extrinsic Eye Muscles 377
  - 8 Conducting an Ophthalmoscopic Examination 378
- Review Sheet** 379

## 25 Special Senses: Hearing and Equilibrium 383

- 1 Identifying Structures of the Ear 384
  - 2 Examining the Ear with an Otoscope (Optional) 386
  - 3 Examining the Microscopic Structure of the Cochlea 387
  - 4 Conducting Laboratory Tests of Hearing 387
  - 5 Audiometry Testing 390
  - 6 Examining the Microscopic Structure of the Crista Ampullaris 391
  - 7 Conducting Laboratory Tests on Equilibrium 391
- Review Sheet** 395

## 26 Special Senses: Olfaction and Taste 399

- 1 Microscopic Examination of the Olfactory Epithelium 401
  - 2 Microscopic Examination of Taste Buds 402
  - 3 Stimulating Taste Buds 402
  - 4 Examining the Combined Effects of Smell, Texture, and Temperature on Taste 402
  - 5 Assessing the Importance of Taste and Olfaction in Odor Identification 404
  - 6 Demonstrating Olfactory Adaptation 404
- Review Sheet** 405

## THE ENDOCRINE SYSTEM

### 27 Functional Anatomy of the Endocrine Glands 407

- 1 Identifying the Endocrine Organs 408
- 2 Examining the Microscopic Structure of Endocrine Glands 412

**Group Challenge** Odd Hormone Out 414

**Review Sheet** 415

### 28 Endocrine Wet Labs and Human Metabolism 419

- 1 Determining the Effect of Pituitary Hormones on the Ovary 420
- 2 Observing the Effects of Hyperinsulinism 421

**Group Challenge** Thyroid Hormone Case Studies 422

**Review Sheet** 423

## THE CIRCULATORY SYSTEM

### 29 Blood 425

- 1 Determining the Physical Characteristics of Plasma 428
- 2 Examining the Formed Elements of Blood Microscopically 428
- 3 Conducting a Differential WBC Count 431
- 4 Determining the Hematocrit 432
- 5 Determining Hemoglobin Concentration 434
- 6 Determining Coagulation Time 435
- 7 Typing for ABO and Rh Blood Groups 436
- 8 Observing Demonstration Slides 438
- 9 Measuring Plasma Cholesterol Concentration 438

**Review Sheet** 439

### 30 Anatomy of the Heart 445

- 1 Using the Heart Model to Study Heart Anatomy 448
- 2 Tracing the Path of Blood Through the Heart 449
- 3 Using the Heart Model to Study Cardiac Circulation 450
- 4 Examining Cardiac Muscle Tissue Anatomy 451

**Review Sheet** 455

### 31 Conduction System of the Heart and Electrocardiography 459

**1A** Recording ECGs Using a Standard ECG Apparatus 463

 **1B** Electrocardiography Using BIOPAC® 464

**Review Sheet** 469

### 32 Anatomy of Blood Vessels 471

- 1 Examining the Microscopic Structure of Arteries and Veins 473
- 2 Locating Arteries on an Anatomical Chart or Model 480
- 3 Identifying the Systemic Veins 484
- 4 Identifying Vessels of the Pulmonary Circulation 485


**Group Challenge** Fix the Blood Trace 486

**5** Tracing the Pathway of Fetal Blood Flow 486

**6** Tracing the Hepatic Portal Circulation 488



**Review Sheet** 489

### 33 Human Cardiovascular Physiology: Blood Pressure and Pulse Determinations 495

- 1 Auscultating Heart Sounds 498
  - 2 Palpating Superficial Pulse Points 499
-  **3** Measuring Pulse Using BIOPAC® 500
- 4 Taking an Apical Pulse 502
  - 5 Using a Sphygmomanometer to Measure Arterial Blood Pressure Indirectly 502
  - 6 Estimating Venous Pressure 503
  - 7 Observing the Effect of Various Factors on Blood Pressure and Heart Rate 504
  - 8 Examining the Effect of Local Chemical and Physical Factors on Skin Color 506

**Review Sheet** 509

### 34 Frog Cardiovascular Physiology 515

- 1 Investigating the Automaticity and Rhythmicity of Heart Muscle 516
-  **2** Recording Baseline Frog Heart Activity 518
- 3 Investigating the Refractory Period of Cardiac Muscle Using the Physiograph 521
-  **4** Assessing Physical and Chemical Modifiers of Heart Rate 521
- 5 Investigating the Effect of Various Factors on the Microcirculation 523

**Review Sheet** 525

### 35 The Lymphatic System and Immune Response 529

- 1 Identifying the Organs of the Lymphatic System 531
- 2 Studying the Microscopic Anatomy of a Lymph Node, the Spleen, and a Tonsil 532

**Group Challenge** Compare and Contrast Lymphoid Organs and Tissues 534

**3** Using the Ouchterlony Technique to Identify Antigens 535

**Review Sheet** 537


## THE RESPIRATORY SYSTEM

### 36 Anatomy of the Respiratory System 541

- 1 Identifying Respiratory System Organs 547
- 2 Demonstrating Lung Inflation in a Sheep Pluck 547
- 3 Examining Prepared Slides of Trachea and Lung Tissue 547

Review Sheet 549

### 37 Respiratory System Physiology 553

- 1 Operating the Model Lung 554
- 2 Auscultating Respiratory Sounds 556
- 3 Measuring Respiratory Volumes Using Spirometers 557
- 4 Measuring the FVC and FEV<sub>1</sub> 563
-  5 Measuring Respiratory Volumes Using BIOPAC® 563
- 6 Visualizing Respiratory Variations 567
- 7 Demonstrating the Reaction Between Carbon Dioxide (in Exhaled Air) and Water 569
- 8 Observing the Operation of Standard Buffers 570
- 9 Exploring the Operation of the Carbonic Acid-Bicarbonate Buffer System 570

Review Sheet 571

## THE DIGESTIVE SYSTEM

### 38 Anatomy of the Digestive System 577

- 1 Identifying Alimentary Canal Organs 578
- 2 Studying the Histologic Structure of the Stomach and the Gastroesophageal Junction 583
- 3 Observing the Histologic Structure of the Small Intestine 586
- 4 Examining the Histologic Structure of the Large Intestine 588
- 5 Identifying Types of Teeth 589
- 6 Studying Microscopic Tooth Anatomy 590
- 7 Examining Salivary Gland Tissue 590
- 8 Examining the Histology of the Liver 591

Review Sheet 593

### 39 Digestive System Processes: Chemical and Physical 599

- 1 Assessing Starch Digestion by Salivary Amylase 600
- 2 Assessing Protein Digestion by Trypsin 603
- 3 Demonstrating the Emulsification Action of Bile and Assessing Fat Digestion by Lipase 604

- 4 Reporting Results and Conclusions 605
- Group Challenge Odd Enzyme Out 605
- 5 Observing Movements and Sounds of the Digestion System 606
  - 6 Viewing Segmental and Peristaltic Movements 607
- Review Sheet 609

## THE URINARY SYSTEM

### 40 Anatomy of the Urinary System 613

- 1 Identifying Urinary System Organs 615
  - 2 Studying Nephron Structure 618
  - 3 Studying Bladder Structure 621
- Group Challenge Urinary System Sequencing 622
- Review Sheet 623

### 41 Urinalysis 627

- 1 Analyzing Urine Samples 629
  - 2 Analyzing Urine Sediment Microscopically (Optional) 632
- Review Sheet 633

## THE REPRODUCTIVE SYSTEM, DEVELOPMENT, AND HEREDITY

### 42 Anatomy of the Reproductive System 635

- 1 Identifying Male Reproductive Organs 636
  - 2 Penis 639
  - 3 Seminal Gland 640
  - 4 Epididymis 640
  - 5 Identifying Female Reproductive Organs 640
  - 6 Wall of the Uterus 643
  - 7 Uterine Tube 643
- Review Sheet 645

### 43 Physiology of Reproduction: Gametogenesis and the Female Cycles 651

- 1 Identifying Meiotic Phases and Structures 653
  - 2 Examining Events of Spermatogenesis 653
  - 3 Examining Meiotic Events Microscopically 655
  - 4 Examining Oogenesis in the Ovary 656
  - 5 Comparing and Contrasting Oogenesis and Spermatogenesis 656
  - 6 Observing Histological Changes in the Endometrium During the Menstrual Cycle 658
- Review Sheet 661

## 44 Survey of Embryonic Development 665

- 1 Microscopic Study of Sea Urchin Development 666
  - 2 Examining the Stages of Human Development 666
  - 3 Identifying Fetal Structures 669
  - 4 Studying Placental Structure 670
- [Review Sheet](#) 671

## 45 Principles of Heredity 675

- 1 Working Out Crosses Involving Dominant and Recessive Genes 676
- 2 Working Out Crosses Involving Incomplete Dominance 677
- 3 Working Out Crosses Involving Sex-Linked Inheritance 678
- 4 Exploring Probability 679
- 5 Using Phenotype to Determine Genotype 679
- 6 Using Agarose Gel Electrophoresis to Identify Normal Hemoglobin, Sickle Cell Anemia, and Sickle Cell Trait 681

**Group Challenge** Odd Phenotype Out 682

[Review Sheet](#) 683

## SURFACE ANATOMY

### 46 Surface Anatomy Roundup 687

- 1 Palpating Landmarks of the Head 688
- 2 Palpating Landmarks of the Neck 690
- 3 Palpating Landmarks of the Trunk 692
- 4 Palpating Landmarks of the Abdomen 694
- 5 Palpating Landmarks of the Upper Limb 696
- 6 Palpating Landmarks of the Lower Limb 699

[Review Sheet](#) 703

## CAT DISSECTION EXERCISES

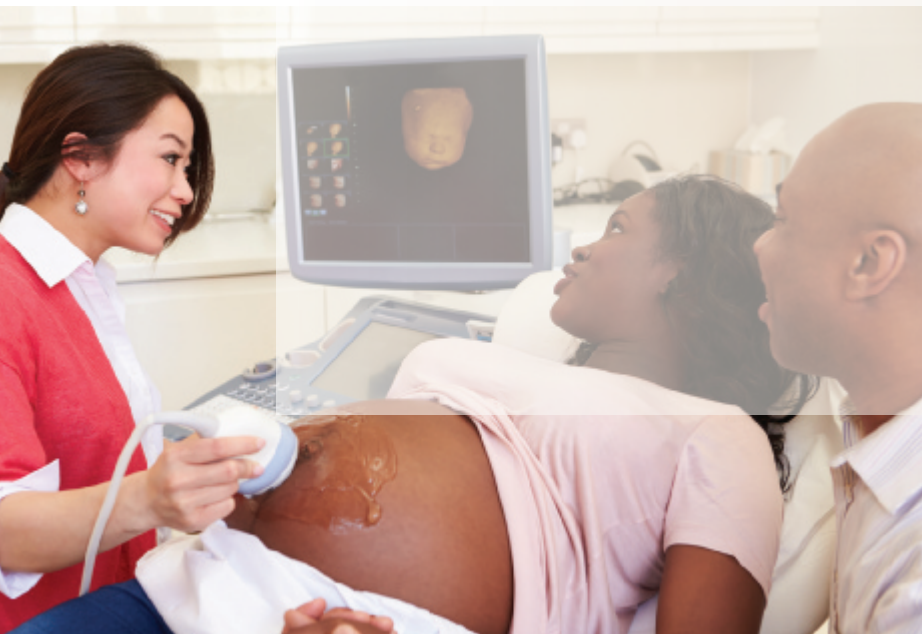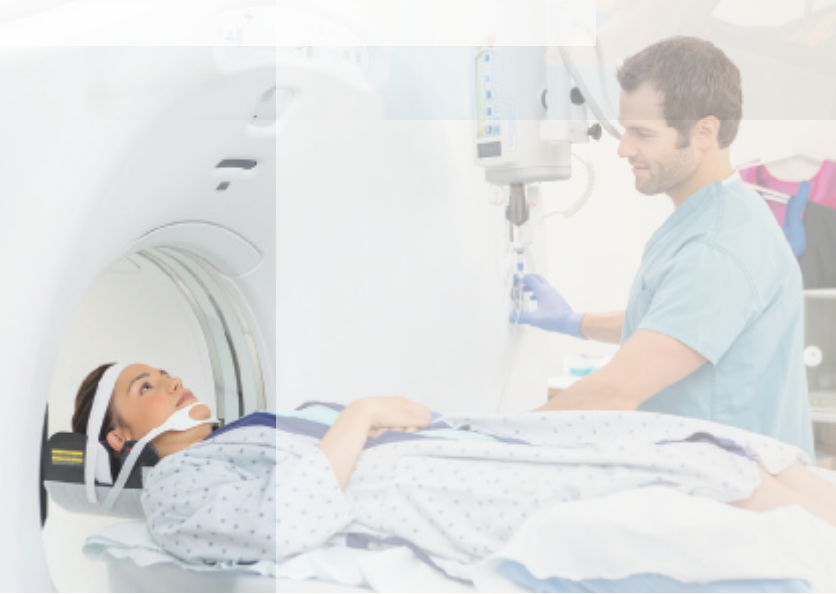- 1 Dissection and Identification of Cat Muscles 705
- 2 Dissection of Cat Spinal Nerves 723
- 3 Identification of Selected Endocrine Organs of the Cat 729
- 4 Dissection of the Blood Vessels of the Cat 733
- 5 The Main Lymphatic Ducts of the Cat 743
- 6 Dissection of the Respiratory System of the Cat 745
- 7 Dissection of the Digestive System of the Cat 749
- 8 Dissection of the Urinary System of the Cat 755
- 9 Dissection of the Reproductive System of the Cat 759

## PHYSIOEX™ 9.1 COMPUTER SIMULATIONS

- 1 Cell Transport Mechanisms and Permeability PEx-3
- 2 Skeletal Muscle Physiology PEx-17
- 3 Neurophysiology of Nerve Impulses PEx-35
- 4 Endocrine System Physiology PEx-59
- 5 Cardiovascular Dynamics PEx-75
- 6 Cardiovascular Physiology PEx-93
- 7 Respiratory System Mechanics PEx-105
- 8 Chemical and Physical Processes of Digestion PEx-119
- 9 Renal System Physiology PEx-131
- 10 Acid-Base Balance PEx-149
- 11 Blood Analysis PEx-161
- 12 Serological Testing PEx-177

**Credits** BM-1

**Index** BM-3



**ELAINE MARIEB** is the most trusted name in all of A&P. More than 3 million healthcare professionals started their careers with one of Elaine Marieb's Anatomy & Physiology texts.

**Now, it's your turn.**



# Tools to Help You

**NEW!**

**Why This Matters** shows you why the lab activity is important by relating it to a real-life or clinical example. In the Review Sheets, corresponding Why This Matters questions help you evaluate your understanding.



74 Exercise 6

## Activity 1

### Examining Epithelial Tissue Under the Microscope

Obtain slides of simple squamous, simple cuboidal, simple columnar, stratified squamous (nonkeratinized), pseudostratified ciliated columnar, stratified cuboidal, stratified columnar, and transitional epithelia. Examine each carefully, and notice how the epithelial cells fit closely together to form intact sheets of cells, a necessity for a tissue that forms linings or the coverings of membranes. Scan each epithelial type for modifications for specific functions, such as cilia (motile cell projections that help to move substances along the cell surface), and microvilli, which increase the surface area for absorption. Also be alert for goblet cells, which secrete lubricating mucus. Compare your observations with the descriptions and photomicrographs in Figure 6.3.

While working, check the questions in the Review Sheet at the end of this exercise. A number of the questions there refer to some of the observations you are asked to make during your microscopic study.

#### WHY THIS MATTERS | Buccal Swabs

A buccal, or cheek, swab is a method used to collect stratified squamous cells from the oral cavity. The cells contain DNA that can be used for DNA fingerprinting or tissue typing. DNA fingerprinting can be used in criminal investigations, and tissue typing can be used to match a recipient with a donor for organ transplant, especially a bone marrow transplant. The buccal swab procedure involves using a cotton-tipped applicator to scrape the inside of the mouth in the buccal region and remove cells at the surface. This noninvasive procedure provides an easy way to obtain the DNA profile of an individual, a unique molecular "signature."

6

**NEW!**

The new workbook-style design makes it easy to see where sections, lab activities, and drawing activities begin and end.

## Group Challenge 1

### Identifying Epithelial Tissues

Following your observations of epithelial tissues under the microscope, obtain an envelope for each group that contains images of various epithelial tissues. With your lab manual closed, remove one image at a time and identify the epithelium. One member of the group will function as the verifier, whose job is to make sure that the identification is correct.

After you have correctly identified all of the images, sort them into groups to help you remember them. (*Hint:* You could sort them according to cell shape or number of layers of epithelial cells.)

Now, carefully go through each group and try to list one place in the body where the tissue is found and one function for it. After you have correctly listed the locations, take your lists and draw some general conclusions about where epithelial tissues are found in the body. Then compare and contrast the functions of the various epithelia. Finally, identify the tissues described in the **Group Challenge 1** chart, and list several locations in the body.


Group Challenge 1: Epithelial Tissue IDs

Magnified appearance	Tissue type	Locations in the body
<ul style="list-style-type: none"> <li>Apical surface has dome-shaped cells (flattened cells may also be mixed in)</li> <li>Multiple layers of cells are present</li> </ul>		
<ul style="list-style-type: none"> <li>Cells are mostly columnar</li> <li>Not all cells reach the apical surface</li> <li>Nuclei are located at different levels</li> <li>Cilia are located at the apical surface</li> </ul>		
<ul style="list-style-type: none"> <li>Apical surface has flattened cells with very little cytoplasm</li> <li>Cells are not layered</li> </ul>		
<ul style="list-style-type: none"> <li>Apical surface has square cells with a round nucleus</li> <li>Cells are not layered</li> </ul>		

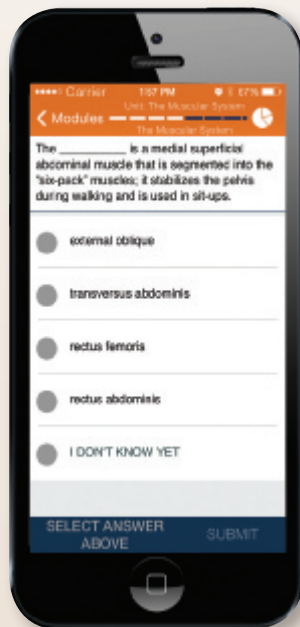
# Succeed in the Lab

**NEW!**

**Prepare for lab by watching pre-lab videos on your smartphone, tablet, or computer.** Short pre-lab videos will give you some background information on the lab, explain what materials you will be using, help you see the connections between the content you learn in the classroom and the experiment, and give you the opportunity to check your understanding—all before you even step foot in the lab.

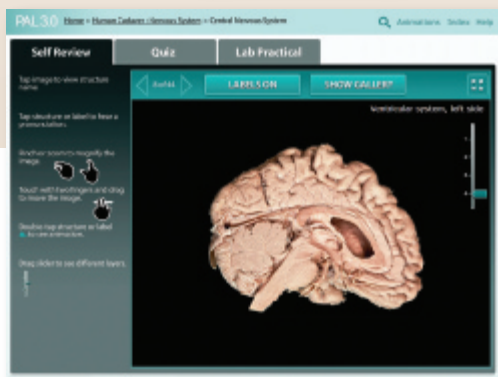


Prepare for lab: Watch the Pre-lab Video  
[MasteringA&P®](#)>Study Area>Pre-Lab Videos

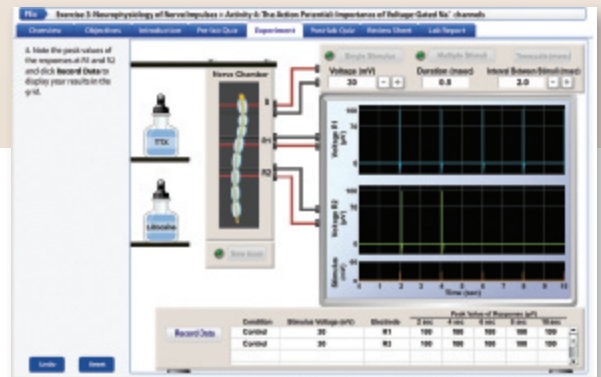


**NEW!**

**Dynamic Study Modules** offer a mobile-friendly, personalized reading experience of the chapter content. As you answer questions to master the chapter content, you receive detailed feedback with text and art from the lab manual itself. The Dynamic Study Modules help you acquire, retain, and recall information faster and more efficiently than ever before.



**Practice Anatomy Lab™ (PAL™) 3.0** is a virtual anatomy study and practice tool that gives you 24/7 access to the most widely used lab specimens, including the human cadaver, anatomical models, histology, cat, and fetal pig. PAL 3.0 is easy to use and includes built-in audio pronunciations, rotatable bones, and simulated fill-in-the-blank lab practical exams.



**PhysioEx™ 9.1** is an easy-to-use lab simulation program that allows you to repeat labs as often as you like, perform experiments without animals, and conduct experiments that are difficult to perform in a wet lab environment because of time, cost, or safety concerns. The online format with easy step-by-step instructions includes everything you need in one convenient place.

# Acknowledgments

We wish to thank the following reviewers for their contribution to this edition: Matthew Abbott, Des Moines Area Community College; Lynne Anderson, Meridian Community College; Christopher W. Brooks, Central Piedmont Community College; Brandi Childress, Georgia Perimeter College; Christopher D'Arcy, Cayuga Community College; Mary E. Dawson, Kingsborough Community College; Karen Eastman, Chattanooga State Community College; Michele Finn, Monroe Community College; Lisa Flick, Monroe Community College; Abigail M. Goosie, Walters State Community College; Samuel Hirt, Auburn University; Shahdi Jalilvand, Tarrant County College—Southeast; Tiffany B. McFalls-Smith, Elizabethtown Community & Technical College; Melinda Miller, Pearl River Community College; Todd Miller, Hunter College of CUNY; Susan Mitchell, Onondaga Community College; Erin Morrey, Georgia Perimeter College; Jill Y. O'Malley, Erie Community College—City; Suzanne Oppenheimer, College of Western Idaho; Suzanne Pundt, The University of Texas at Tyler; Mark Schmidt, Clark State Community College; Teresa Stegall-Faulk, Middle Tennessee State University; Bonnie J. Tarricone, Ivy Tech Community College.

Special thanks to Susan Mitchell for her authorial contributions to this lab manual over the years.

Thanks also to Josephine Rogers of the University of Cincinnati, the original author of the pre-lab quizzes.

The excellence of PhysioEx 9.1 reflects the expertise of Peter Zao, Timothy Stabler, Lori Smith, Andrew Lokuta, Greta Peterson, Nina Zanetti, and Edwin Griff. They generated the ideas behind the activities and simulations. Credit also goes to the team at BinaryLabs, Inc., for their expert programming and design.

Continued thanks to colleagues and friends at Pearson who worked with us in the production of this edition, especially Serina Beuparlant, Editor-in-Chief; Brooke Suchomel, Senior Acquisitions Editor; Lisa Clark, Development Editor; and

Shannon Cutt, Program Manager. Applause also to Lauren Hill who managed MasteringA&P, and Aimee Pavy for her work on PhysioEx 9.1. Many thanks to Amanda J.S. Kaufmann who did a super job as video production manager of the new pre-lab videos. Additional thanks go to Cheryl Chi and the group at Roaring Mouse Productions, who provided their special skills to the video production team. Many thanks to Stacey Weinberger for her manufacturing expertise. Finally, our Senior Marketing Manager, Allison Rona, has efficiently kept us in touch with the pulse of the market.

Kudos also to Michele Mangelli and her production team, who did their usual great job. Janet Vail, Production Editor for this project, got the job done in jig time. David Novak acted as Art and Photo Coordinator, and Kristin Piljay conducted photo research. Our fabulous interior and cover designs were created by tani hasegawa. Sally Peyrefitte brought her experience to copyediting the text.

We are grateful to the team at BIOPAC, especially to Jocelyn Kremer and Mike Mullins, who were extremely helpful in making sure we had the latest updates and answering all of our questions.



Elaine N. Marieb  
Lori A. Smith  
Anatomy and Physiology  
Pearson Education  
1301 Sansome Street  
San Francisco, CA 94111

## EXERCISE

## 1

# The Language of Anatomy

## Objectives

- Describe the anatomical position, and explain its importance.
- Use proper anatomical terminology to describe body regions, orientation and direction, and body planes.
- Name the body cavities, and indicate the important organs in each.
- Name and describe the serous membranes of the ventral body cavities.
- Identify the abdominopelvic quadrants and regions on a torso model or image.

## Materials

- Human torso model (dissectible)
- Human skeleton
- Demonstration: sectioned and labeled kidneys (three separate kidneys uncut or cut so that [a] entire, [b] transverse sectional, and [c] longitudinal sectional views are visible)
- Gelatin-spaghetti molds
- Scalpel
- Post-it® Notes

## Pre-Lab Quiz

1. Circle True or False. In anatomical position, the body is lying down.
2. Circle the correct underlined term. With regard to surface anatomy, abdominal / axial refers to the structures along the center line of the body.
3. The term *superficial* refers to a structure that is:
  - a. attached near the trunk of the body
  - b. toward or at the body surface
  - c. toward the head
  - d. toward the midline
4. The \_\_\_\_\_ plane runs longitudinally and divides the body into right and left sides.
 

a. frontal	c. transverse
b. sagittal	d. ventral
5. Circle the correct underlined terms. The dorsal body cavity can be divided into the cranial / thoracic cavity, which contains the brain, and the sural / vertebral cavity, which contains the spinal cord.

## MasteringA&P®

For related exercise study tools, go to the Study Area of **MasteringA&P**. There you will find:

- Practice Anatomy Lab **PAL**
- PhysioEx **PEx**
- A&PFlix **A&PFlix**
- Practice quizzes, Histology Atlas, eText, Videos, and more!

Most of us are naturally curious about our bodies. This curiosity is apparent even in infants, who are fascinated with their own waving hands or their mother's nose. Unlike an infant, however, an anatomy student must learn to observe and identify the dissectible body structures formally.

A student new to any science is often overwhelmed at first by the terminology used in that subject. The study of anatomy is no exception. But without this specialized terminology, confusion is inevitable. For example, what do *over*, *on top of*, *above*, and *behind* mean in reference to the human body? Anatomists have an accepted set of reference terms that are universally understood. These allow body structures to be located and identified precisely with a minimum of words.

This exercise presents some of the most important anatomical terminology used to describe the body and introduces you to basic concepts of **gross anatomy**, the study of body structures visible to the naked eye.

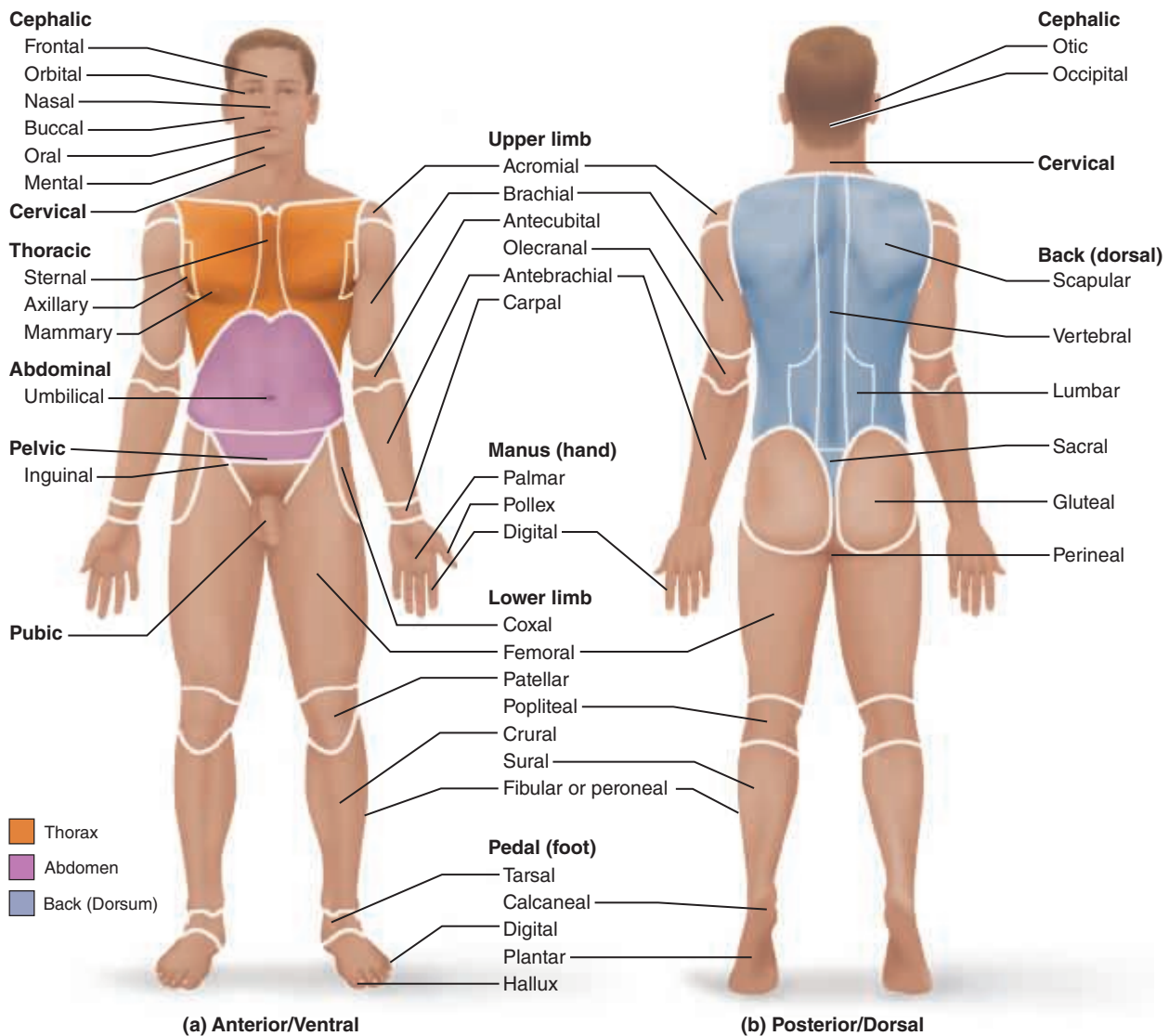
## Anatomical Position

When anatomists or doctors refer to specific areas of the human body, the picture they keep in mind is a universally accepted standard position called the **anatomical position**. It is essential to understand this position because much of the directional terminology used in this book refers to the body in this position, regardless of the position the body happens to be in. In the anatomical position, the human body is erect, with the feet only slightly apart, head and toes pointed forward,

and arms hanging at the sides with palms facing forward (**Figure 1.1a**).

Assume the anatomical position, and notice that it is not particularly comfortable. The hands are held unnaturally forward rather than hanging with palms toward the thighs.

Check the box when you have completed this task.



**Figure 1.1** Surface anatomy. (a) Anatomical position. (b) Heels are raised to illustrate the plantar surface of the foot.

## Surface Anatomy

Body surfaces provide a wealth of visible landmarks for study. There are two major divisions of the body:

**Axial:** Relating to head, neck, and trunk, the axis of the body

**Appendicular:** Relating to limbs and their attachments to the axis

### Anterior Body Landmarks

Note the following regions in Figure 1.1a:

**Abdominal:** Anterior body trunk region inferior to the ribs

**Acromial:** Point of the shoulder

**Antebrachial:** Forearm

**Antecubital:** Anterior surface of the elbow

**Axillary:** Armpit

**Brachial:** Arm

**Buccal:** Cheek

**Carpal:** Wrist

**Cephalic:** Head

**Cervical:** Neck region

**Coxal:** Hip

**Crural:** Leg

**Digital:** Fingers or toes

**Femoral:** Thigh

**Fibular (peroneal):** Side of the leg

**Frontal:** Forehead

**Hallux:** Great toe

**Inguinal:** Groin area

**Mammary:** Breast region

**Manus:** Hand

**Mental:** Chin

**Nasal:** Nose

**Oral:** Mouth

**Orbital:** Bony eye socket (orbit)

**Palmar:** Palm of the hand

**Patellar:** Anterior knee (kneecap) region

**Pedal:** Foot

**Pelvic:** Pelvis region

**Pollex:** Thumb

**Pubic:** Genital region

**Sternal:** Region of the breastbone

**Tarsal:** Ankle

**Thoracic:** Chest

**Umbilical:** Navel

### Posterior Body Landmarks

Note the following body surface regions in Figure 1.1b:

**Acromial:** Point of the shoulder

**Brachial:** Arm

**Calcaneal:** Heel of the foot

**Cephalic:** Head

**Dorsum:** Back

**Femoral:** Thigh

**Gluteal:** Buttocks or rump

**Lumbar:** Area of the back between the ribs and hips; the loin

**Manus:** Hand

**Occipital:** Posterior aspect of the head or base of the skull

**Olecranal:** Posterior aspect of the elbow

**Otic:** Ear

**Pedal:** Foot

**Perineal:** Region between the anus and external genitalia

**Plantar:** Sole of the foot

**Popliteal:** Back of the knee

**Sacral:** Region between the hips (overlying the sacrum)

**Scapular:** Scapula or shoulder blade area

**Sural:** Calf or posterior surface of the leg

**Vertebral:** Area of the spinal column

### Activity 1

#### Locating Body Regions

Locate the anterior and posterior body landmarks on yourself, your lab partner, and a human torso model.

## Body Orientation and Direction

Study the terms below, referring to **Figure 1.2** on p. 4 for a visual aid. Notice that certain terms have different meanings, depending on whether they refer to a four-legged animal (quadruped) or to a human (biped).

**Superior/inferior** (*above/below*): These terms refer to placement of a structure along the long axis of the body. For example, the nose is superior to the mouth, and the abdomen is inferior to the chest.

**Anterior/posterior** (*front/back*): In humans, the most anterior structures are those that are most forward—the face, chest, and abdomen. Posterior structures are those toward the backside of the body. For instance, the spine is posterior to the heart.

**Medial/lateral** (*toward the midline/away from the midline or median plane*): The sternum (breastbone) is medial to the ribs; the ear is lateral to the nose.

The terms of position just described assume the person is in the anatomical position. The next four term pairs are more absolute. They apply in any body position, and they consistently have the same meaning in all vertebrate animals.

**Cephalad (cranial)/caudal** (*toward the head/toward the tail*): In humans, these terms are used interchangeably with *superior* and *inferior*, but in four-legged animals they are synonymous with *anterior* and *posterior*, respectively.

**Ventral/dorsal** (*belly side/backside*): These terms are used chiefly in discussing the comparative anatomy of animals, assuming the animal is standing. In humans, the terms *ventral* and *dorsal* are used interchangeably with the terms *anterior* and *posterior*, but in four-legged animals, *ventral* and *dorsal* are synonymous with *inferior* and *superior*, respectively.

**Proximal/distal** (*nearer the trunk or attached end/farther from the trunk or point of attachment*): These terms are

used primarily to locate various areas of the body limbs. For example, the fingers are distal to the elbow; the knee is proximal to the toes. However, these terms may also be used to indicate regions (closer to or farther from the head) of internal tubular organs.

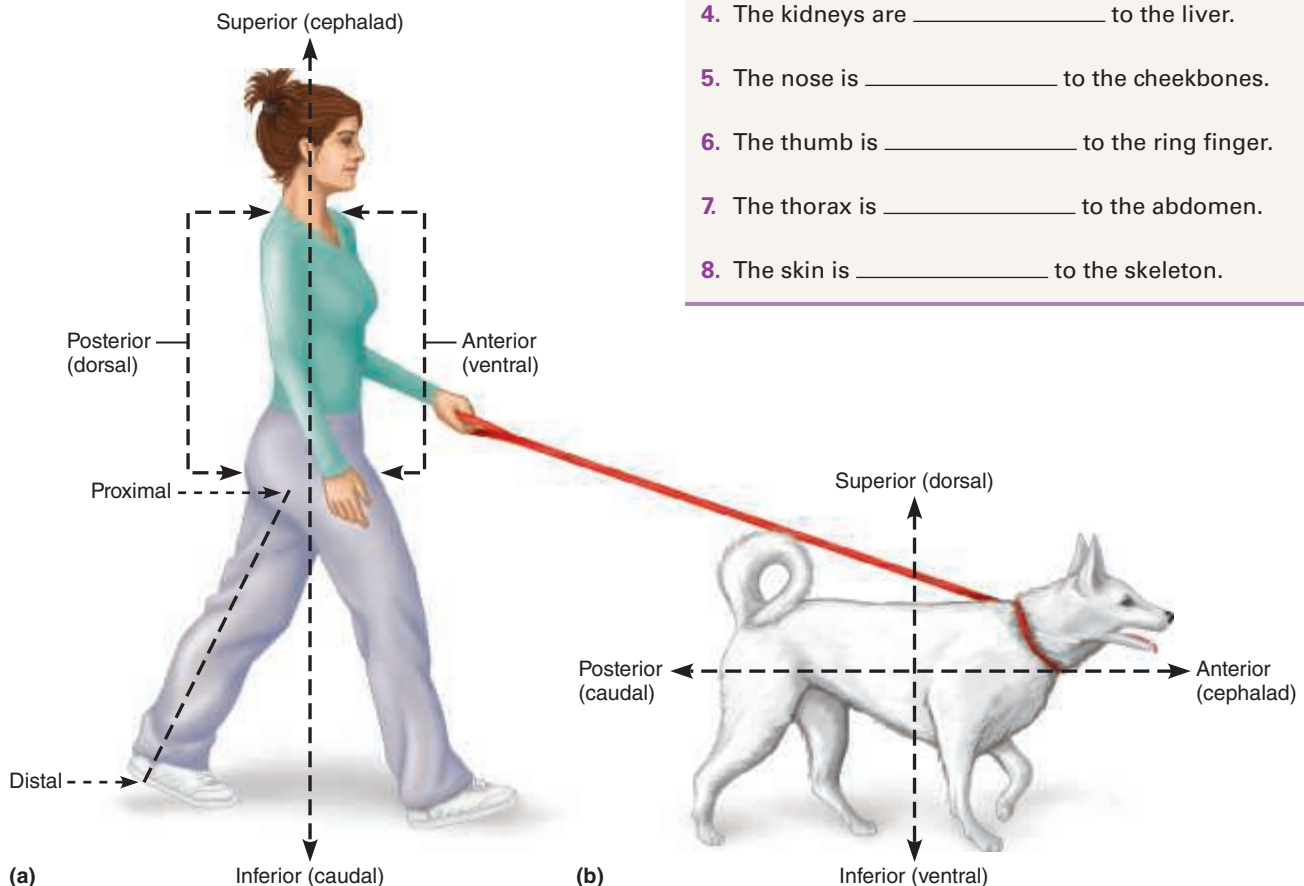
**Superficial (external)/deep (internal)** (*toward or at the body surface/away from the body surface*): For example, the skin is superficial to the skeletal muscles, and the lungs are deep to the rib cage.

## Activity 2

### Practicing Using Correct Anatomical Terminology

Use a human torso model, a human skeleton, or your own body to specify the relationship between the following structures when the body is in the anatomical position.

1. The wrist is \_\_\_\_\_ to the hand.
2. The trachea (windpipe) is \_\_\_\_\_ to the spine.
3. The brain is \_\_\_\_\_ to the spinal cord.
4. The kidneys are \_\_\_\_\_ to the liver.
5. The nose is \_\_\_\_\_ to the cheekbones.
6. The thumb is \_\_\_\_\_ to the ring finger.
7. The thorax is \_\_\_\_\_ to the abdomen.
8. The skin is \_\_\_\_\_ to the skeleton.



**Figure 1.2** Anatomical terminology describing body orientation and direction. (a) With reference to a human. (b) With reference to a four-legged animal.

## Body Planes and Sections

The body is three-dimensional, and in order to observe its internal structures, it is often necessary to make a **section**, or cut. When the section is made through the body wall or through an organ, it is made along an imaginary surface or line called a **plane**. Anatomists commonly refer to three planes (**Figure 1.3**), or sections, that lie at right angles to one another.

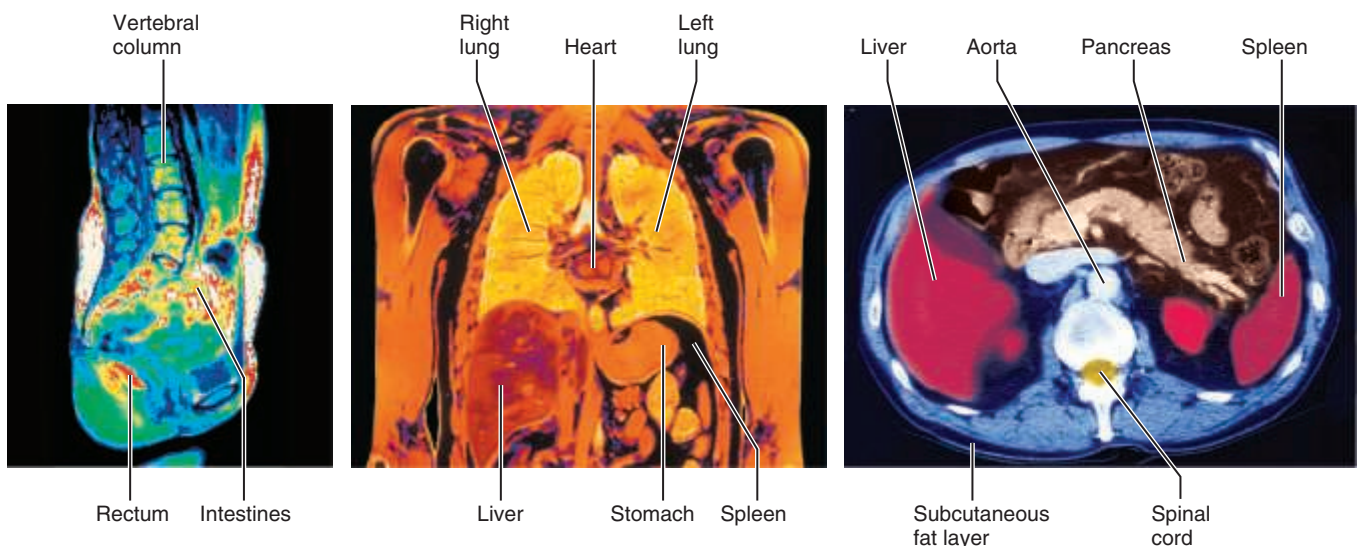
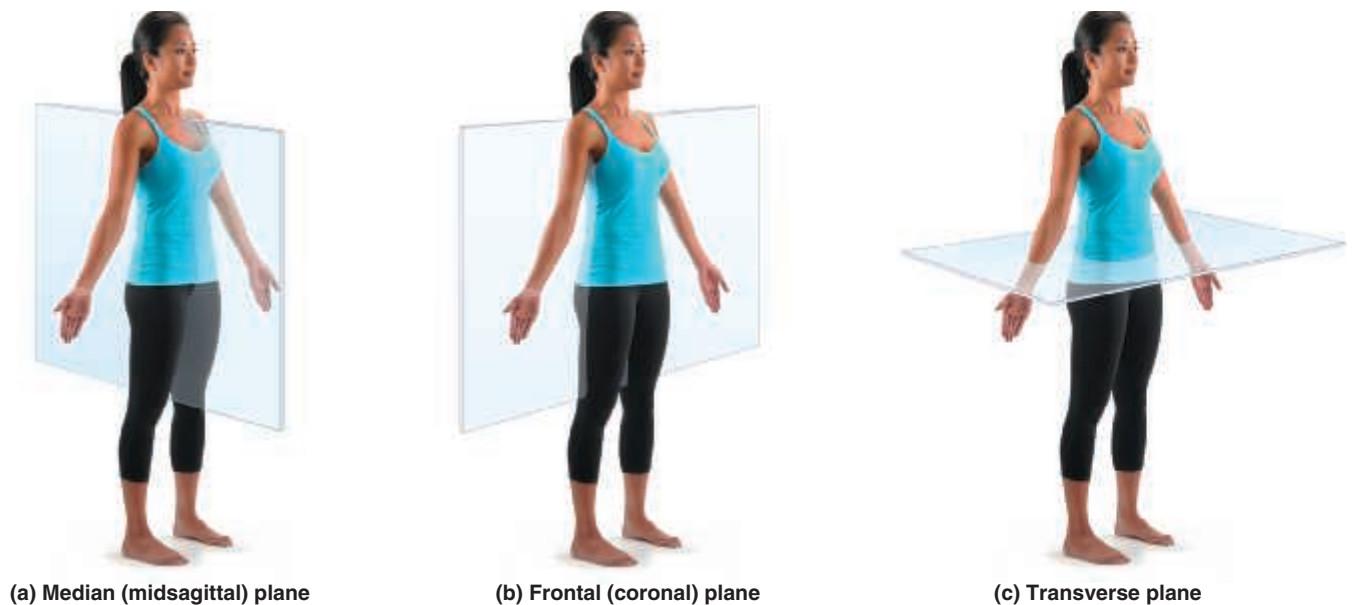
**Sagittal plane:** A sagittal plane runs longitudinally and divides the body into right and left parts. If it divides the body into equal parts, right down the midline of the body, it is called a **median**, or **midsagittal**, plane.

**Frontal plane:** Sometimes called a **coronal plane**, the frontal plane is a longitudinal plane that divides the body (or an organ) into anterior and posterior parts.

**Transverse plane:** A transverse plane runs horizontally, dividing the body into superior and inferior parts. When organs are sectioned along the transverse plane, the sections are commonly called **cross sections**.

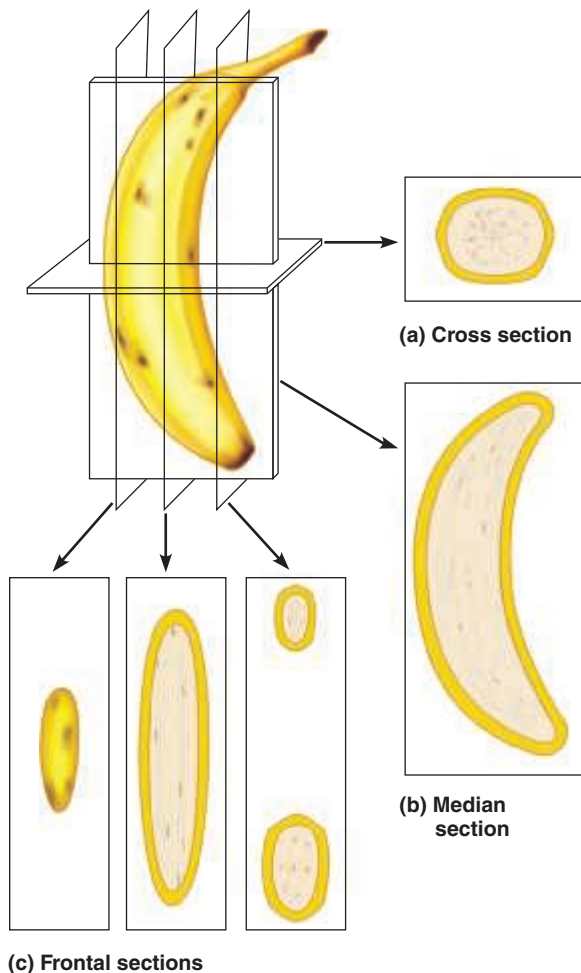
On microscope slides, the abbreviation for a longitudinal section (sagittal or frontal) is l.s. Cross sections are abbreviated x.s. or c.s.

A median or frontal plane section of any nonspherical object, be it a banana or a body organ, provides quite a different view from a cross section (**Figure 1.4**, p. 6).



**Figure 1.3** Planes of the body with corresponding magnetic resonance imaging (MRI) scans. Note the transverse section is an inferior view.





**Figure 1.4** Objects can look odd when viewed in section. This banana has been sectioned in three different planes (a–c), and only in one of these planes (b) is it easily recognized as a banana. If one cannot recognize a sectioned organ, it is possible to reconstruct its shape from a series of successive cuts, as from the three serial sections in (c).

## Body Cavities

The axial portion of the body has two large cavities that provide different degrees of protection to the organs within them (Figure 1.5).

### Dorsal Body Cavity

The dorsal body cavity can be subdivided into the **cranial cavity**, which lies within the rigid skull and encases the brain, and the **vertebral (or spinal) cavity**, which runs through the bony vertebral column to enclose the delicate spinal cord. Because the spinal cord is a continuation of the brain, these cavities are continuous with each other.


### Ventral Body Cavity

Like the dorsal cavity, the ventral body cavity is subdivided. The superior **thoracic cavity** is separated from the rest of the ventral cavity by the dome-shaped diaphragm. The heart and lungs, located in the thoracic cavity, are protected by the


## Activity 3

### Observing Sectioned Specimens

1. Go to the demonstration area and observe the transversely and longitudinally cut organ specimens (kidneys). Pay close attention to the different structural details in the samples; you will need to draw these views in the Review Sheet at the end of this exercise.
2. After completing instruction 1, obtain a gelatin-spaghetti mold and a scalpel, and take them to your laboratory bench. (Essentially, this is just cooked spaghetti added to warm gelatin, which is then allowed to gel.)
3. Cut through the gelatin-spaghetti mold along any plane, and examine the cut surfaces. You should see spaghetti strands that have been cut transversely (x.s.) and some cut longitudinally.
4. Draw the appearance of each of these spaghetti sections below, and verify the accuracy of your section identifications with your instructor.



Transverse cut

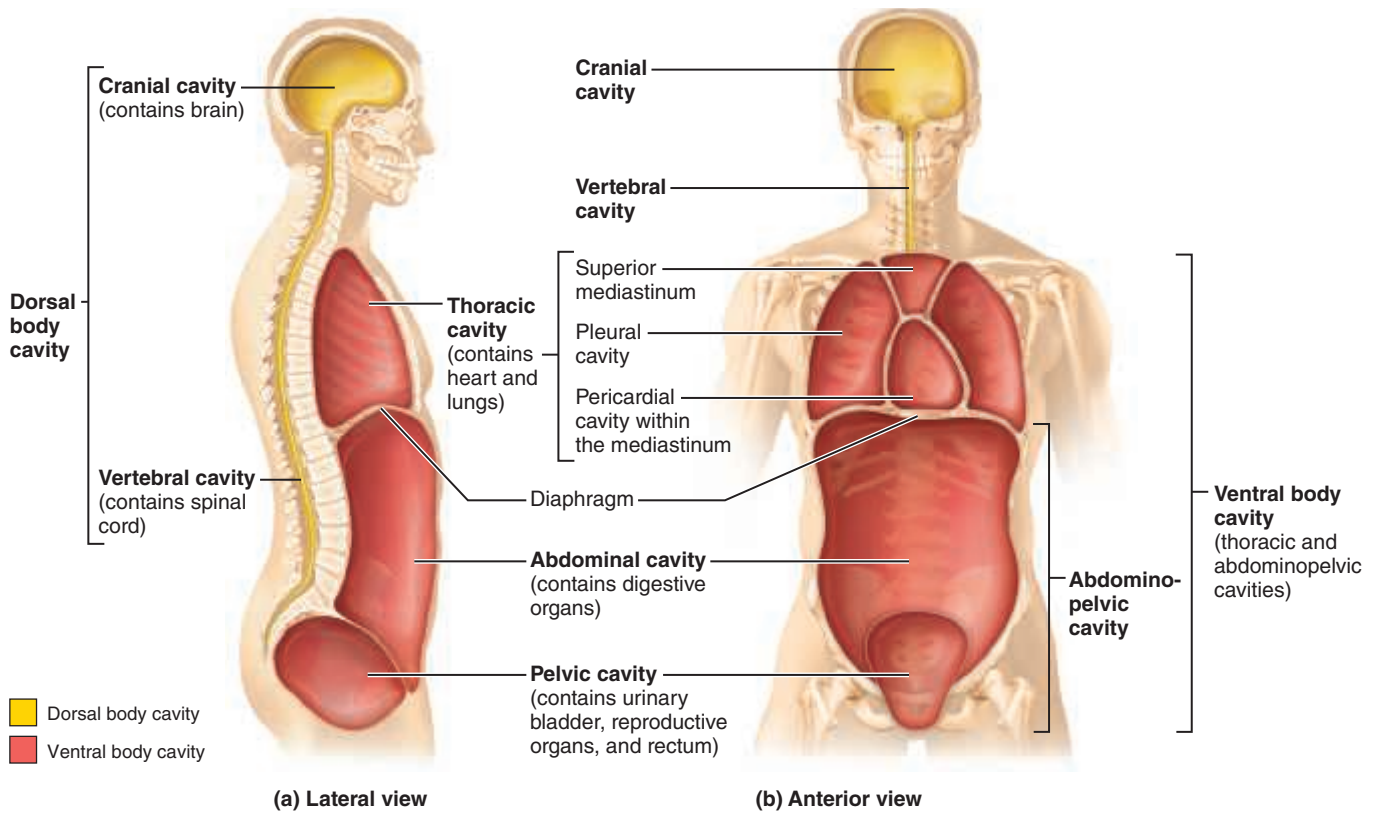


Longitudinal cut

bony rib cage. The cavity inferior to the diaphragm is often referred to as the **abdominopelvic cavity**. Although there is no further physical separation of the ventral cavity, some describe the abdominopelvic cavity as two areas: a superior **abdominal cavity**, the area that houses the stomach, intestines, liver, and other organs, and an inferior **pelvic cavity**, the region that is partially enclosed by the bony pelvis and contains the reproductive organs, bladder, and rectum. Notice in Figure 1.5a that the abdominal and pelvic cavities are not aligned with each other in a plane because the pelvic cavity is tipped forward.

### Serous Membranes of the Ventral Body Cavity

The walls of the ventral body cavity and the outer surfaces of the organs it contains are covered with an exceedingly thin, double-layered membrane called the **serosa**, or **serous membrane**. The part of the membrane lining the cavity walls is referred to as the **parietal serosa**, and it is continuous with a

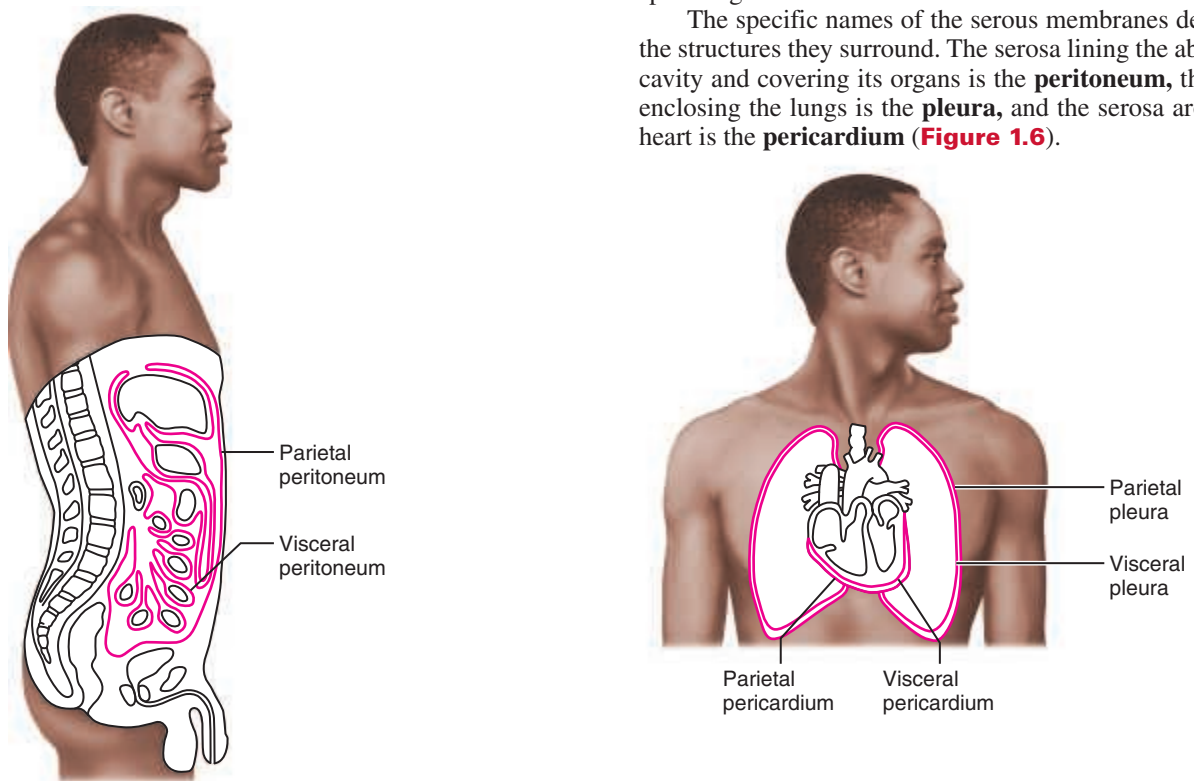


**Figure 1.5** Dorsal and ventral body cavities and their subdivisions.

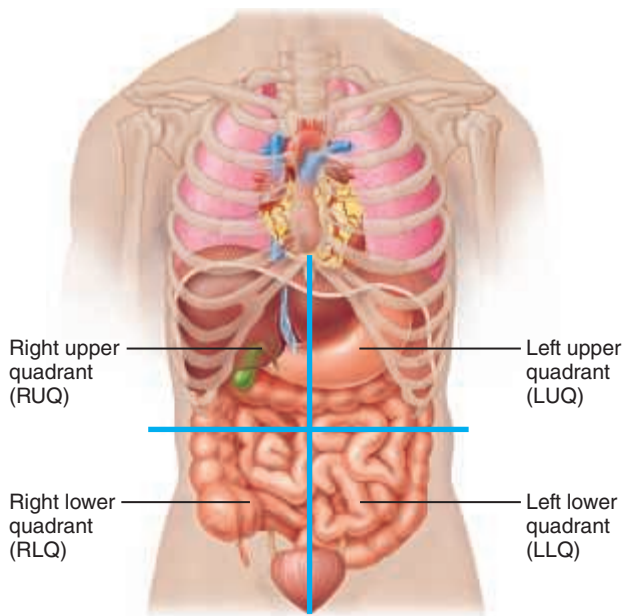
similar membrane, the **visceral serosa**, covering the external surface of the organs within the cavity. These membranes produce a thin lubricating fluid that allows the visceral organs

to slide over one another or to rub against the body wall with minimal friction. Serous membranes also compartmentalize the various organs to prevent infection in one organ from spreading to others.

The specific names of the serous membranes depend on the structures they surround. The serosa lining the abdominal cavity and covering its organs is the **peritoneum**, the serosa enclosing the lungs is the **pleura**, and the serosa around the heart is the **pericardium** (**Figure 1.6**).



**Figure 1.6** Serous membranes of the ventral body cavities.



**Figure 1.7** Abdominopelvic quadrants. Superficial organs all shown in each quadrant.

### Abdominopelvic Quadrants and Regions

Because the abdominopelvic cavity is quite large and contains many organs, it is helpful to divide it up into smaller areas for discussion or study.

Most physicians and nurses use a scheme that divides the abdominal surface and the abdominopelvic cavity into four approximately equal regions called **quadrants**. These quadrants are named according to their relative position—that is, *right upper quadrant*, *right lower quadrant*, *left upper quadrant*, and *left lower quadrant* (**Figure 1.7**). Note that the terms *left* and *right* refer to the left and right side of

### Activity 4

#### Identifying Organs in the Abdominopelvic Cavity

Examine the human torso model to respond to the following questions.

Name two organs found in the left upper quadrant.

\_\_\_\_\_ and \_\_\_\_\_

Name two organs found in the right lower quadrant.

\_\_\_\_\_ and \_\_\_\_\_

What organ (Figure 1.7) is divided into identical halves by the median plane? \_\_\_\_\_

the body in the figure, not the left and right side of the art on the page.

A different scheme commonly used by anatomists divides the abdominal surface and abdominopelvic cavity into nine separate regions by four planes (**Figure 1.8**). As you read through the descriptions of these nine regions, locate them in Figure 1.8, and note the organs contained in each region.

**Umbilical region:** The centermost region, which includes the umbilicus (navel)

**Epigastric region:** Immediately superior to the umbilical region; overlies most of the stomach

**Hypogastric (pubic) region:** Immediately inferior to the umbilical region; encompasses the pubic area

**Iliac, or inguinal, regions:** Lateral to the hypogastric region and overlying the superior parts of the hip bones

**Lumbar regions:** Between the ribs and the flaring portions of the hip bones; lateral to the umbilical region

**Hypochondriac regions:** Flanking the epigastric region laterally and overlying the lower ribs

### Activity 5

#### Locating Abdominal Surface Regions

Locate the regions of the abdominal surface on a human torso model and on yourself.

### Other Body Cavities

Besides the large, closed body cavities, there are several types of smaller body cavities (**Figure 1.9**). Many of these are in the head, and most open to the body exterior.

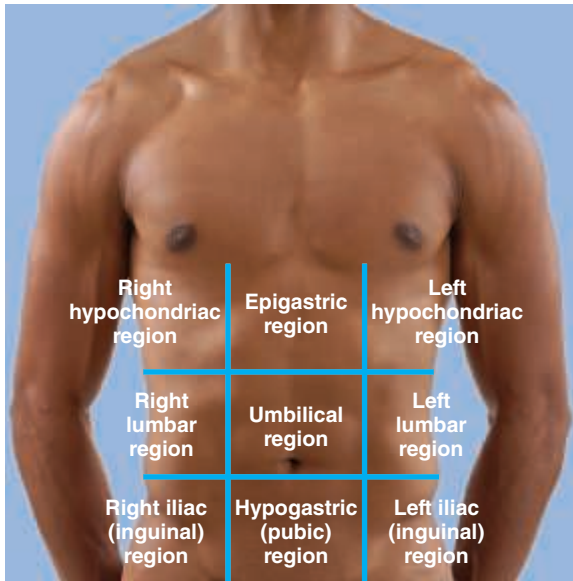
**Oral cavity:** The oral cavity, commonly called the *mouth*, contains the tongue and teeth. It is continuous with the rest of the digestive tube, which opens to the exterior at the anus.

**Nasal cavity:** Located within and posterior to the nose, the nasal cavity is part of the passages of the respiratory system.

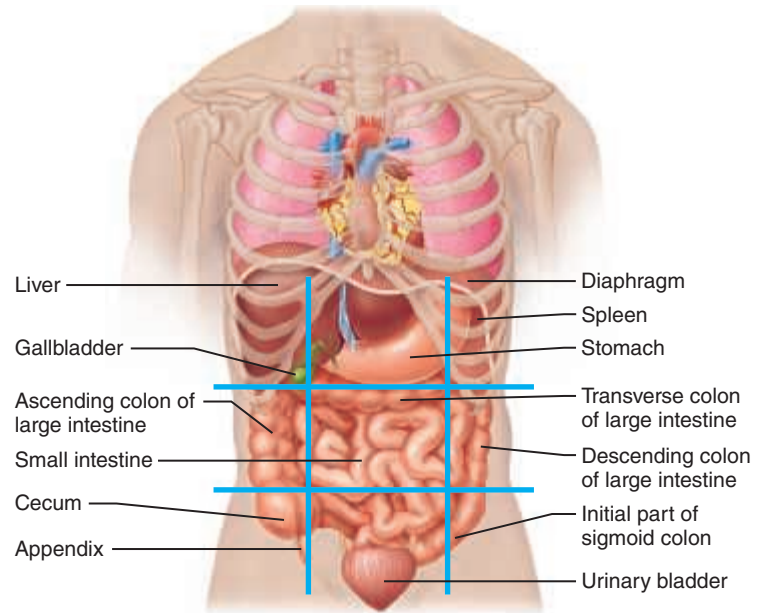
**Orbital cavities:** The orbital cavities (orbits) in the skull house the eyes and present them in an anterior position.

**Middle ear cavities:** Each middle ear cavity lies just medial to an eardrum and is carved into the bony skull. These cavities contain tiny bones that transmit sound vibrations to the hearing receptors in the inner ears.

**Synovial cavities:** Synovial cavities are joint cavities—they are enclosed within fibrous capsules that surround the freely movable joints of the body, such as those between the vertebrae and the knee and hip joints. Like the serous membranes of the ventral body cavity, membranes lining the synovial cavities secrete a lubricating fluid that reduces friction as the enclosed structures move across one another.

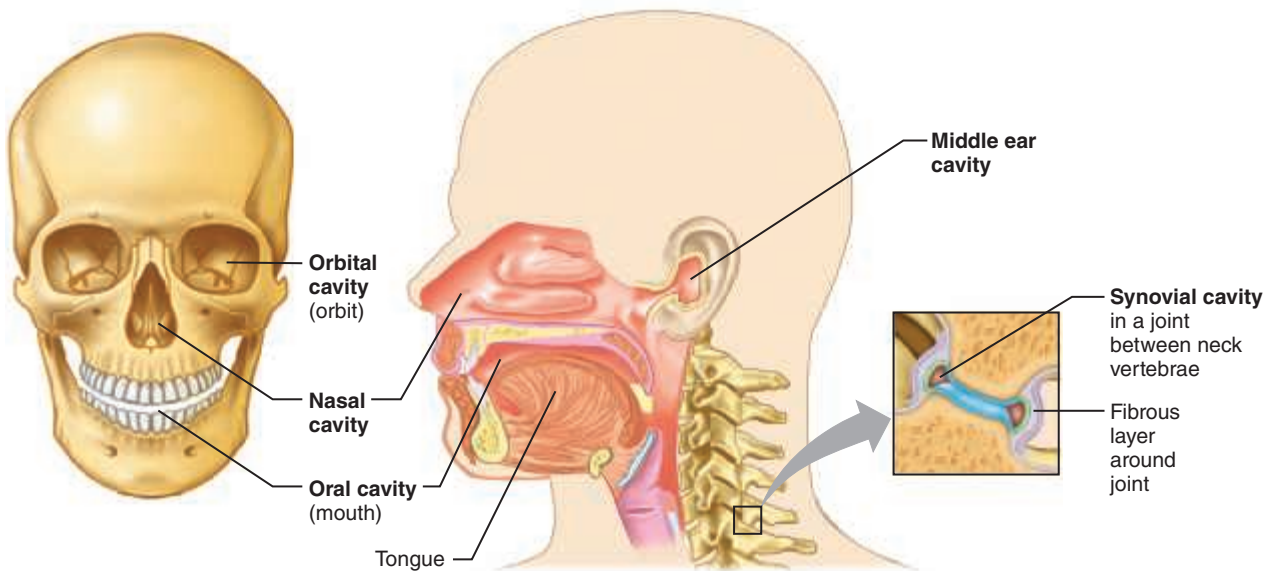


(a)



(b)

**Figure 1.8 Abdominopelvic regions.** Nine regions delineated by four planes. (a) The superior horizontal plane is just inferior to the ribs; the inferior horizontal plane is at the superior aspect of the hip bones. The vertical planes are just medial to the nipples. (b) Superficial organs are shown in each region.



**Figure 1.9 Other body cavities.** The oral, nasal, orbital, and middle ear cavities are located in the head and open to the body exterior. Synovial cavities are found in joints between many bones, such as the vertebrae of the spine, and at the knee, shoulder, and hip.



## Group Challenge

### The Language of Anatomy

Working in groups of three, complete the tasks described below.

For questions 1–4, each student within a group will assume a different role: facilitator, subject, or recorder. (Remind the subject to stand in the anatomical position.)

The facilitator will write each term on a separate Post-it Note. For each term, discuss within your group where on the subject to place the Post-it. Once your group members have come to consensus, the facilitator will stick the Post-it on the subject on the appropriate body landmark. After all of the Post-it Notes have been placed, the group will discuss the order in which the terms should be recorded. Then the recorder will write down the terms in the appropriate order.

1. Arrange the following terms from superior to inferior: cervical, coxal, crural, femoral, lumbar, mental, nasal, plantar, sternal, and tarsal. \_\_\_\_\_

\_\_\_\_\_

\_\_\_\_\_

\_\_\_\_\_

2. Arrange the following terms from proximal to distal: antebrachial, antecubital, brachial, carpal, digital, and palmar. \_\_\_\_\_

\_\_\_\_\_

3. Arrange the following terms from medial to lateral: acromial, axillary, buccal, otic, pollex, and umbilical.

\_\_\_\_\_

\_\_\_\_\_

4. Arrange the following terms from distal to proximal: calcaneal, femoral, hallux, plantar, popliteal, and sural.

\_\_\_\_\_

\_\_\_\_\_

5. Name a plane that you could use to section a four-legged chair and still be able to sit in the chair without falling over. \_\_\_\_\_

\_\_\_\_\_

6. Name the abdominopelvic region that is both medial and inferior to the right lumbar region.

\_\_\_\_\_

7. Name the type of inflammation (think “-itis”) that is typically accompanied by pain in the lower right quadrant.

\_\_\_\_\_

# REVIEW SHEET

## The Language of Anatomy

Name \_\_\_\_\_ LabTime/Date \_\_\_\_\_

### Surface Anatomy

1. Match each of the numbered descriptions with the related term in the key, and record the key letter or term in front of the description.

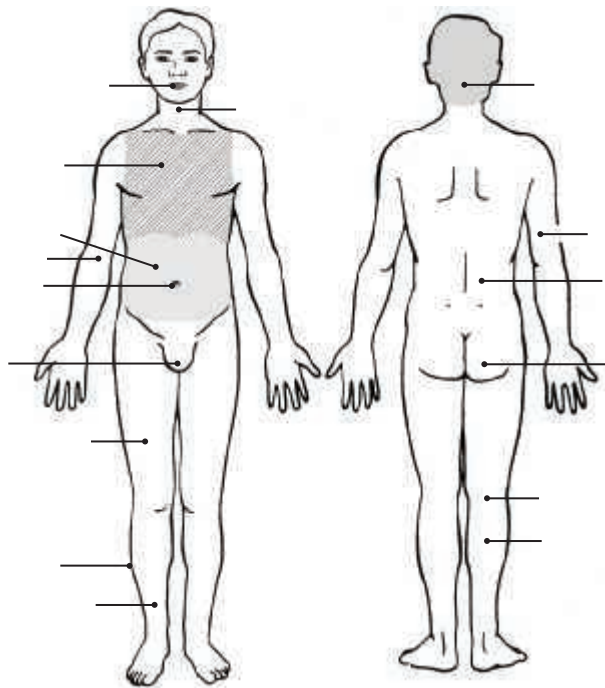
Key: a. buccal                      c. cephalic                      e. patellar  
       b. calcaneal                  d. digital                        f. scapular

\_\_\_\_\_ 1. cheek                      \_\_\_\_\_ 4. anterior aspect of knee  
 \_\_\_\_\_ 2. fingers                      \_\_\_\_\_ 5. heel of foot  
 \_\_\_\_\_ 3. shoulder blade region                      \_\_\_\_\_ 6. head

2. Indicate the following body areas on the accompanying diagram by placing the correct key letter at the end of each line.

Key:

a. abdominal  
 b. antecubital  
 c. brachial  
 d. cervical  
 e. crural  
 f. femoral  
 g. fibular  
 h. gluteal  
 i. lumbar  
 j. occipital  
 k. oral  
 l. popliteal  
 m. pubic  
 n. sural  
 o. thoracic  
 p. umbilical



3. For each term in the key of question 2 above, determine which of the two major body divisions it belongs to. Insert the appropriate key letters on the answer blanks.

\_\_\_\_\_ 1. appendicular                      \_\_\_\_\_ 2. axial

### Body Orientation, Direction, Planes, and Sections

4. Describe completely the standard human anatomical position. \_\_\_\_\_

5. Define *section*. \_\_\_\_\_
6. Several incomplete statements appear below. Correctly complete each statement by choosing the appropriate anatomical term from the key. Record the key letters and/or terms on the correspondingly numbered blanks below. Some terms are used more than once.

Key: a. anterior      d. inferior      g. posterior      j. superior  
 b. distal          e. lateral      h. proximal      k. transverse  
 c. frontal          f. medial      i. sagittal

In the anatomical position, the face and palms are on the 1 body surface; the buttocks and shoulder blades are on the 2 body surface; and the top of the head is the most 3 part of the body. The ears are 4 and 5 to the shoulders and 6 to the nose. The heart is 7 to the vertebral column (spine) and 8 to the lungs. The elbow is 9 to the fingers but 10 to the shoulder. The abdominopelvic cavity is 11 to the thoracic cavity and 12 to the spinal cavity. In humans, the dorsal surface can also be called the 13 surface; however, in quadruped animals, the dorsal surface is the 14 surface.

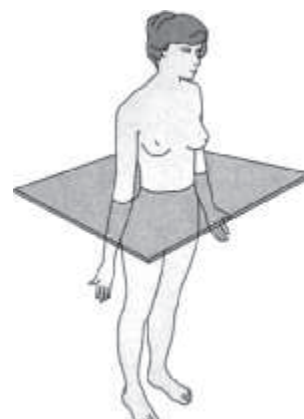
If an incision cuts the heart into right and left parts, the section is a 15 section; but if the heart is cut so that superior and inferior portions result, the section is a 16 section. You are told to cut a dissection animal along two planes so that both kidneys are observable in each section. The two sections that can meet this requirement are the 17 and 18 sections. A section that demonstrates the continuity between the spinal and cranial cavities is a 19 section.

- |          |           |           |
|----------|-----------|-----------|
| 1. _____ | 8. _____  | 14. _____ |
| 2. _____ | 9. _____  | 15. _____ |
| 3. _____ | 10. _____ | 16. _____ |
| 4. _____ | 11. _____ | 17. _____ |
| 5. _____ | 12. _____ | 18. _____ |
| 6. _____ | 13. _____ | 19. _____ |
| 7. _____ |           |           |



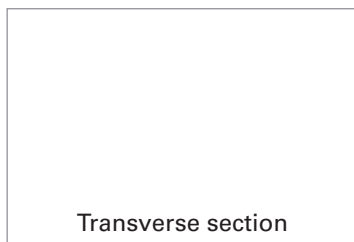
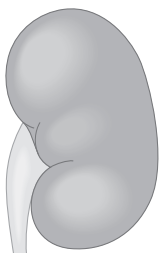
7. Correctly identify each of the body planes by inserting the appropriate term on the answer line below the drawing.



(a) \_\_\_\_\_ (b) \_\_\_\_\_ (c) \_\_\_\_\_

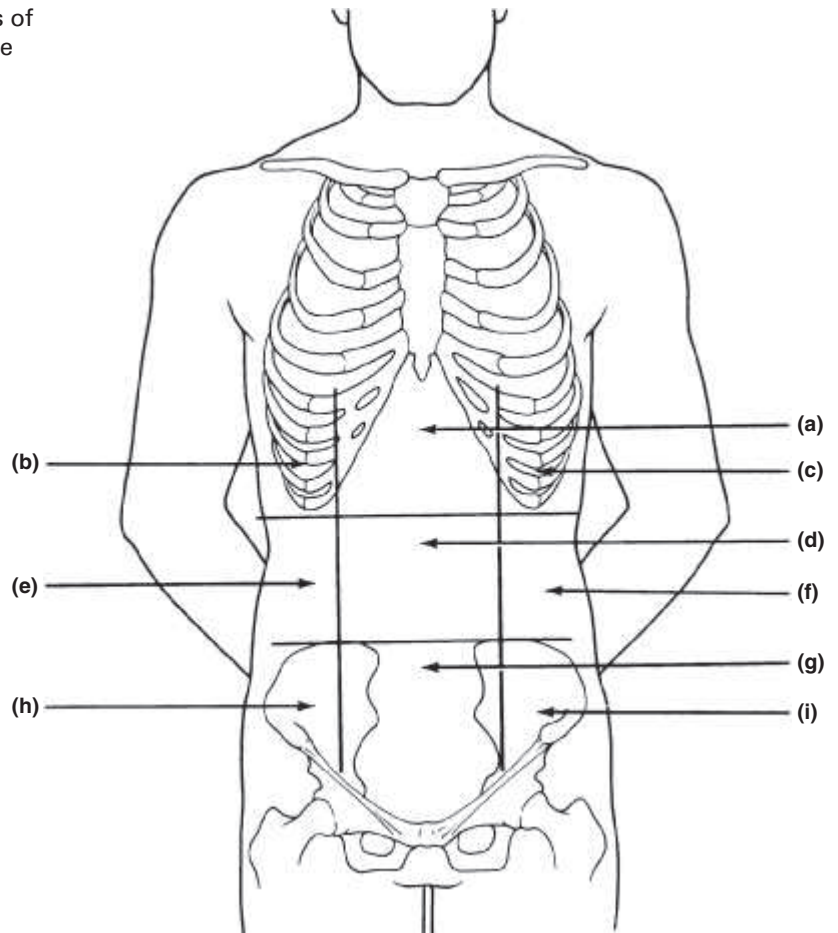


8. Draw a kidney as it appears when sectioned in each of the three different planes.



9. Correctly identify each of the nine regions of the abdominopelvic cavity by inserting the appropriate term for each letter indicated in the drawing.

- a. \_\_\_\_\_
- b. \_\_\_\_\_
- c. \_\_\_\_\_
- d. \_\_\_\_\_
- e. \_\_\_\_\_
- f. \_\_\_\_\_
- g. \_\_\_\_\_
- h. \_\_\_\_\_
- i. \_\_\_\_\_



## Body Cavities

10. Which body cavities would have to be opened for the following types of surgery or procedures? (Insert the letter of key choice in the same-numbered blank. More than one choice applies.)

Key: a. abdominopelvic      c. dorsal      e. thoracic  
 b. cranial                  d. spinal      f. ventral

- |  |  |
|--|--|
| _____ 1. surgery to remove a cancerous lung lobe | _____ 4. appendectomy                                  |
| _____ 2. removal of the uterus, or womb          | _____ 5. stomach ulcer operation                       |
| _____ 3. removal of a brain tumor                | _____ 6. delivery of pre-operative "saddle" anesthesia |

11. Name the muscle that subdivides the ventral body cavity. \_\_\_\_\_

12. What are the bony landmarks of the abdominopelvic cavity? \_\_\_\_\_

13. Which body cavity provides the least protection to its internal structures? \_\_\_\_\_

14. What is the function of the serous membranes of the body? \_\_\_\_\_



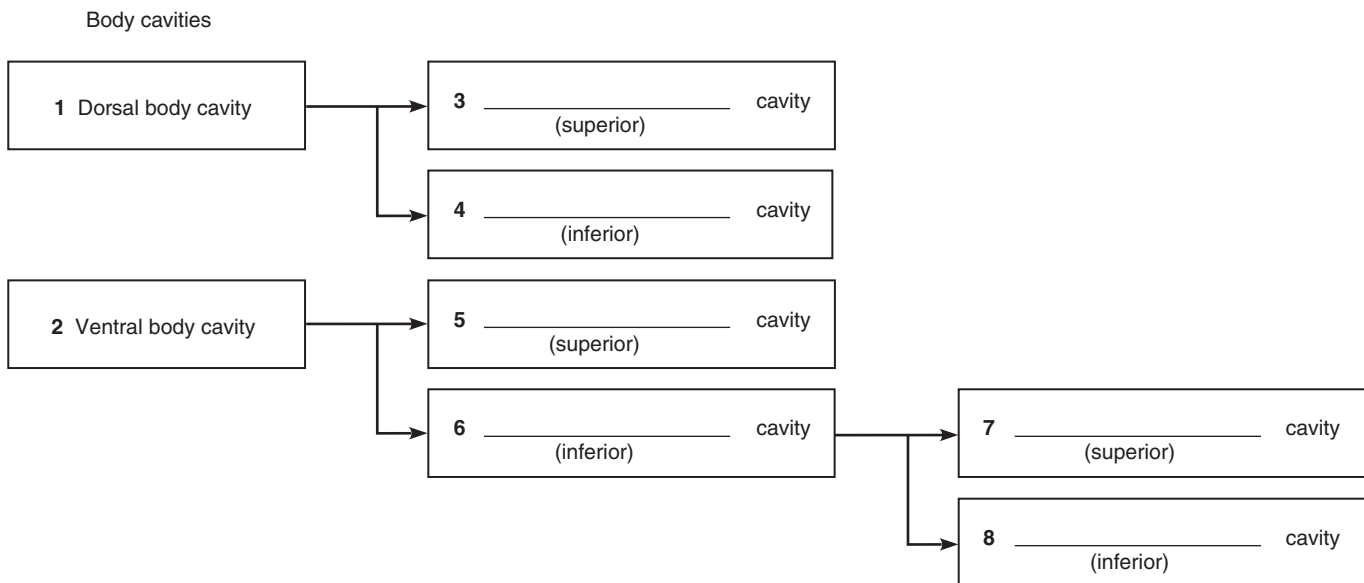
15. Using the key choices, identify the small body cavities described below.

- Key: a. middle ear cavity                      c. oral cavity                      e. synovial cavity  
 b. nasal cavity                                  d. orbital cavity

- \_\_\_\_\_ 1. holds the eyes in an anterior-facing position                      \_\_\_\_\_ 4. contains the tongue  
 \_\_\_\_\_ 2. houses three tiny bones involved in hearing                      \_\_\_\_\_ 5. surrounds a joint  
 \_\_\_\_\_ 3. contained within the nose

16. On the incomplete flowchart provided below:

- Fill in the cavity names that belong in boxes 3–8.
- Then, using either the name of the cavity or the box numbers, identify the descriptions in the list that follows.



- \_\_\_\_\_ a. contained within the skull and vertebral column  
 \_\_\_\_\_ b. houses female reproductive organs  
 \_\_\_\_\_ c. the most protective body cavity  
 \_\_\_\_\_ d. its name means "belly"  
 \_\_\_\_\_ e. contains the heart  
 \_\_\_\_\_ f. contains the small intestine  
 \_\_\_\_\_ g. bounded by the ribs  
 \_\_\_\_\_ h. its walls are muscular

# Organ Systems Overview

## Objectives

- Name the human organ systems, and indicate the major functions of each.
- List several major organs of each system, and identify them in a dissected rat, human cadaver or cadaver image, or a dissectible human torso model.
- Name the correct organ system for each organ when presented with a list of organs studied in the laboratory.

## Materials

- Freshly killed or preserved rat (predissected by instructor as a demonstration or for student dissection [one rat for every two to four students]) or predissected human cadaver
- Dissection trays
- Twine or large dissecting pins
- Scissors
- Probes
- Forceps
- Disposable gloves
- Human torso model (dissectible)

## Pre-Lab Quiz

1. Name the structural and functional unit of all living things. \_\_\_\_\_
2. The small intestine is an example of a(n) \_\_\_\_\_, because it is composed of two or more tissue types that perform a particular function for the body.
  - a. epithelial tissue
  - b. muscular tissue
  - c. organ
  - d. organ system
3. The \_\_\_\_\_ system is responsible for maintaining homeostasis of the body via rapid transmission of electrical signals.
4. The kidneys are part of the \_\_\_\_\_ system.
5. The thin muscle that separates the thoracic and abdominal cavities is the \_\_\_\_\_.

The basic unit or building block of all living things is the **cell**. Cells fall into four different categories according to their structures and functions. These categories correspond to the four tissue types: epithelial, muscular, nervous, and connective. A **tissue** is a group of cells that are similar in structure and function. An **organ** is a structure composed of two or more tissue types that performs a specific function for the body. For example, the small intestine, which digests and absorbs nutrients, is made up of all four tissue types.

An **organ system** is a group of organs that act together to perform a particular body function. For example, the organs of the digestive system work together to break down foods and absorb the end products into the bloodstream in order to provide nutrients and fuel for all the body's cells. In all, there are 11 organ systems, described in **Table 2.1** on p. 16. The lymphatic system also encompasses a *functional system* called the immune system, which is composed of an army of mobile *cells* that protect the body from foreign substances.

Read through this summary of the body's organ systems (Table 2.1) before beginning your rat dissection or examination of the predissected human cadaver. If a human cadaver is not available, Figures 2.3–2.6 will serve as a partial replacement.

## MasteringA&P®

For related exercise study tools, go to the Study Area of **MasteringA&P**. There you will find:

- Practice Anatomy Lab **PAL**
- Practice quizzes, Histology Atlas, eText, Videos, and more!
- A&PFlix **A&PFlix**
- PhysioEx **PEX**

**Table 2.1** Overview of Organ Systems of the Body

Organ system	Major component organs	Function
Integumentary (Skin)	Epidermal and dermal regions; cutaneous sense organs and glands	<ul style="list-style-type: none"> <li>Protects deeper organs from mechanical, chemical, and bacterial injury, and from drying out</li> <li>Excretes salts and urea</li> <li>Aids in regulation of body temperature</li> <li>Produces vitamin D</li> </ul>
Skeletal	Bones, cartilages, tendons, ligaments, and joints	<ul style="list-style-type: none"> <li>Body support and protection of internal organs</li> <li>Provides levers for muscular action</li> <li>Cavities provide a site for blood cell formation</li> </ul>
Muscular	Muscles attached to the skeleton	<ul style="list-style-type: none"> <li>Primary function is to contract or shorten; in doing so, skeletal muscles allow locomotion (running, walking, etc.), grasping and manipulation of the environment, and facial expression</li> <li>Generates heat</li> </ul>
Nervous	Brain, spinal cord, nerves, and sensory receptors	<ul style="list-style-type: none"> <li>Allows body to detect changes in its internal and external environment and to respond to such information by activating appropriate muscles or glands</li> <li>Helps maintain homeostasis of the body via rapid transmission of electrical signals</li> </ul>
Endocrine	Pituitary, thymus, thyroid, parathyroid, adrenal, and pineal glands; ovaries, testes, and pancreas	<ul style="list-style-type: none"> <li>Helps maintain body homeostasis, promotes growth and development; produces chemical messengers called hormones that travel in the blood to exert their effect(s) on various target organs of the body</li> </ul>
Cardiovascular	Heart, blood vessels, and blood	<ul style="list-style-type: none"> <li>Primarily a transport system that carries blood containing oxygen, carbon dioxide, nutrients, wastes, ions, hormones, and other substances to and from the tissue cells where exchanges are made; blood is propelled through the blood vessels by the pumping action of the heart</li> <li>Antibodies and other protein molecules in the blood protect the body</li> </ul>
Lymphatic/Immunity	Lymphatic vessels, lymph nodes, spleen, thymus, tonsils, and scattered collections of lymphoid tissue	<ul style="list-style-type: none"> <li>Picks up fluid leaked from the blood vessels and returns it to the blood</li> <li>Cleanses blood of pathogens and other debris</li> <li>Houses lymphocytes that act via the immune response to protect the body from foreign substances</li> </ul>
Respiratory	Nasal passages, pharynx, larynx, trachea, bronchi, and lungs	<ul style="list-style-type: none"> <li>Keeps the blood continuously supplied with oxygen while removing carbon dioxide</li> <li>Contributes to the acid-base balance of the blood via its carbonic acid–bicarbonate buffer system</li> </ul>
Digestive	Oral cavity, esophagus, stomach, small and large intestines, and accessory structures including teeth, salivary glands, liver, and pancreas	<ul style="list-style-type: none"> <li>Breaks down ingested foods to smaller particles, which can be absorbed into the blood for delivery to the body cells</li> <li>Undigested residue removed from the body as feces</li> </ul>
Urinary	Kidneys, ureters, bladder, and urethra	<ul style="list-style-type: none"> <li>Rids the body of nitrogen-containing wastes including urea, uric acid, and ammonia, which result from the breakdown of proteins and nucleic acids</li> <li>Maintains water, electrolyte, and acid-base balance of blood</li> </ul>
Reproductive	<p>Male: testes, prostate gland, scrotum, penis, and duct system, which carries sperm to the body exterior</p> <p>Female: ovaries, uterine tubes, uterus, mammary glands, and vagina</p>	<ul style="list-style-type: none"> <li>Provides germ cells called sperm for perpetuation of the species</li> <li>Provides germ cells called eggs; the female uterus houses the developing fetus until birth; mammary glands provide nutrition for the infant</li> </ul>



## DISSECTION AND IDENTIFICATION

### The Organ Systems of the Rat

Many of the external and internal structures of the rat are quite similar in structure and function to those of the human. So, a study of the gross anatomy of the rat should help you understand our own physical structure. The following instructions include directions for dissecting and observing a rat. In addition, the descriptions of the organs (Activity 4, Examining the Ventral Body Cavity, which begins on p. 18) also apply to superficial observations of

a previously dissected human cadaver. The general instructions for observing external structures also apply to human cadaver observations. The photographs in Figures 2.3 to 2.6 will provide visual aids.


Note that four organ systems (integumentary, skeletal, muscular, and nervous) will not be studied at this time, because they require microscopic study or more detailed dissection.

## Activity 1

### Observing External Structures

1. If your instructor has provided a pre-dissected rat, go to the demonstration area to make your observations. Alternatively, if you and/or members of your group will be dissecting the specimen, obtain a preserved or freshly killed rat, a dissecting tray, dissecting pins or twine, scissors, probe, forceps, and disposable gloves, and bring them to your laboratory bench.

If a pre-dissected human cadaver is available, obtain a probe, forceps, and disposable gloves before going to the demonstration area.

 2. Don the gloves before beginning your observations. This precaution is particularly important when handling freshly killed animals, which may harbor pathogens.

3. Observe the major divisions of the body—head, trunk, and extremities. If you are examining a rat, compare these divisions to those of humans.

## Activity 2

### Examining the Oral Cavity

Examine the structures of the oral cavity. Identify the teeth and tongue. Observe the extent of the hard palate (the portion underlain by bone) and the soft palate (immediately posterior to the hard palate, with no bony support). Notice that the posterior end of the oral cavity leads into the throat, or pharynx, a passageway used by both the digestive and respiratory systems.

## Activity 3

### Opening the Ventral Body Cavity

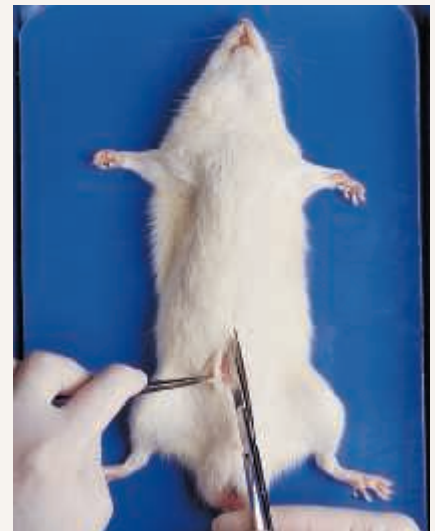1. Pin the animal to the wax of the dissecting tray by placing its dorsal side down and securing its extremities to the wax with large dissecting pins as shown in **Figure 2.1a**.

*Text continues on next page. →*

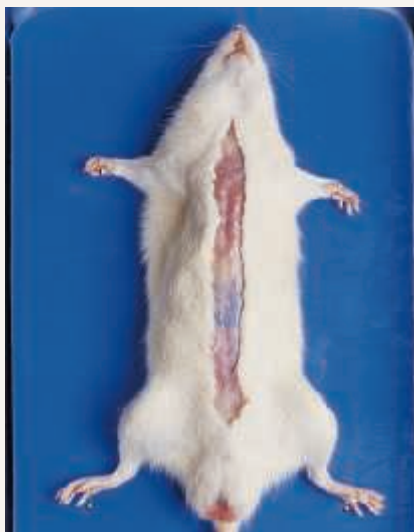**Figure 2.1** Rat dissection: Securing for dissection and the initial incision. (a) Securing the rat to the dissection tray with dissecting pins. (b) Using scissors to make the incision on the median line of the abdominal region. (c) Completed incision from the pelvic region to the lower jaw. (d) Reflection (folding back) of the skin to expose the underlying muscles.



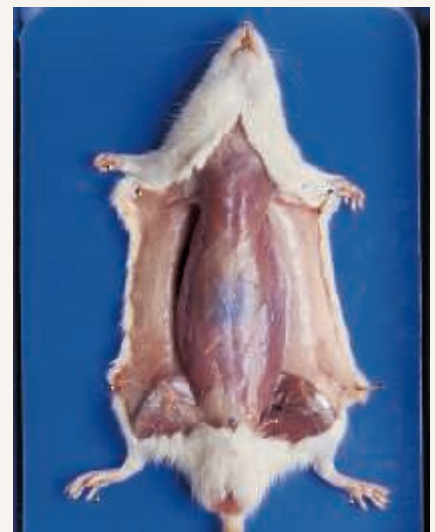(a)



(b)



(c)

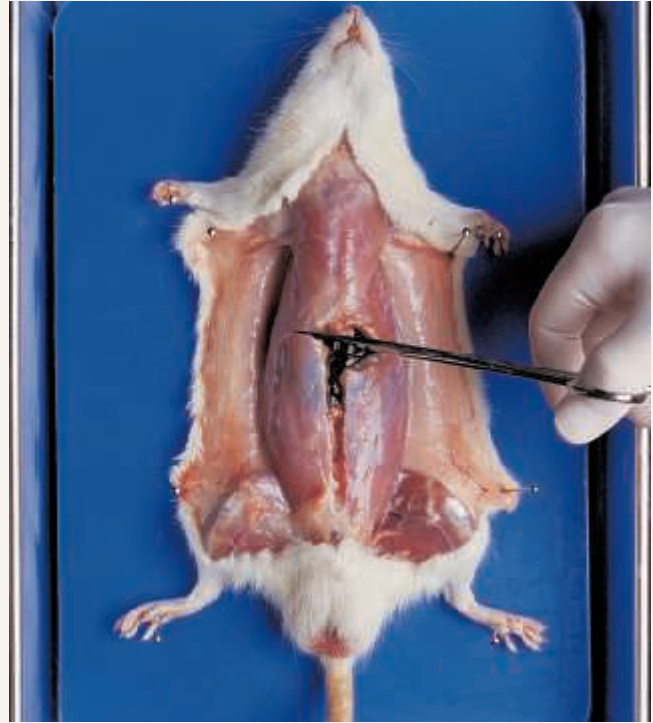

(d)

If the dissecting tray is not waxed, you will need to secure the animal with twine as follows. (Your instructor may prefer this method in any case.) Obtain the roll of twine. Make a loop knot around one upper limb, pass the twine under the tray, and secure the opposing limb. Repeat for the lower extremities.

2. Lift the abdominal skin with a forceps, and cut through it with the scissors (Figure 2.1b). Close the scissor blades, and insert them flat under the cut skin. Moving in a cephalad direction, open and close the blades to loosen the skin from the underlying connective tissue and muscle. Now, cut the skin along the body midline, from the pubic region to the lower jaw (Figure 2.1c). Finally, make a lateral cut about halfway down the ventral surface of each limb. Complete the job of freeing the skin with the scissor tips, and pin the flaps to the tray (Figure 2.1d). The underlying tissue that is now exposed is the skeletal musculature of the body wall and limbs. Notice that the muscles are packaged in sheets of pearly white connective tissue (fascia), which protect the muscles and bind them together.

3. Carefully cut through the muscles of the abdominal wall in the pubic region, avoiding the underlying organs. Remember, to *dissect* means “to separate” — not mutilate! Now, hold and lift the muscle layer with a forceps and cut through the muscle layer from the pubic region to the bottom of the rib cage. Make two lateral cuts at the base of the rib cage (Figure 2.2). A thin membrane attached to the inferior boundary of the rib cage should be obvious; this is the **diaphragm**, which separates the thoracic and abdominal cavities. Cut the diaphragm where it attaches to the ventral ribs to loosen the rib cage. Cut through the rib cage on either side. You can now lift the ribs to view the



**Figure 2.2** Rat dissection. Making lateral cuts at the base of the rib cage.

contents of the thoracic cavity. Cut across the flap, at the level of the neck, and remove the rib cage.

## Activity 4

### Examining the Ventral Body Cavity

1. Starting with the most superficial structures and working deeper, examine the structures of the thoracic cavity. Refer to **Figure 2.3**, which shows the superficial organs, as you work. Choose the appropriate view depending on whether you are examining a rat (a) or a human cadaver (b).

**Thymus:** An irregular mass of glandular tissue overlying the heart (not illustrated in the human cadaver photograph).

With the probe, push the thymus to the side to view the heart.

**Heart:** Medial oval structure enclosed within the pericardium (serous membrane sac).

**Lungs:** Lateral to the heart on either side.

Now observe the throat region to identify the trachea.

**Trachea:** Tubelike “windpipe” running medially down the throat; part of the respiratory system.

Follow the trachea into the thoracic cavity; notice where it divides into two branches. These are the bronchi.

**Bronchi:** Two passageways that plunge laterally into the tissue of the two lungs.

To expose the esophagus, push the trachea to one side.

**Esophagus:** A food chute; the part of the digestive system that transports food from the pharynx (throat) to the stomach.

**Diaphragm:** A thin muscle attached to the inferior boundary of the rib cage; separates the thoracic and abdominopelvic cavities.

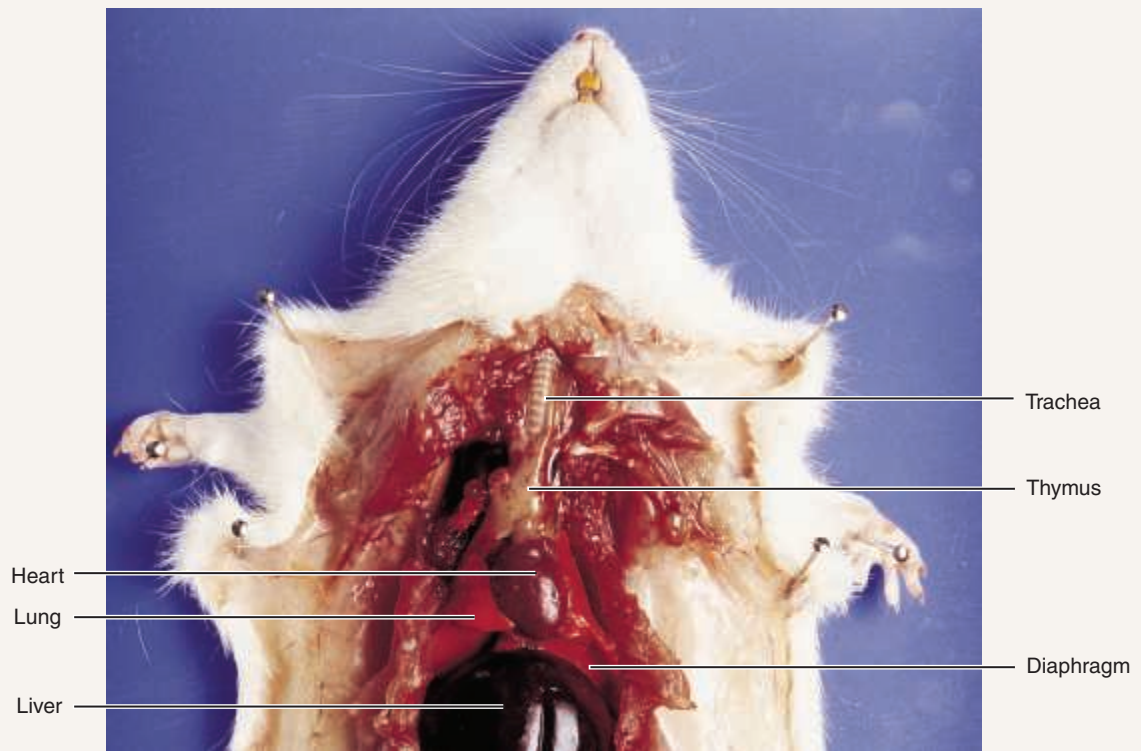
Follow the esophagus through the diaphragm to its junction with the stomach.

**Stomach:** A curved organ important in food digestion and temporary food storage.

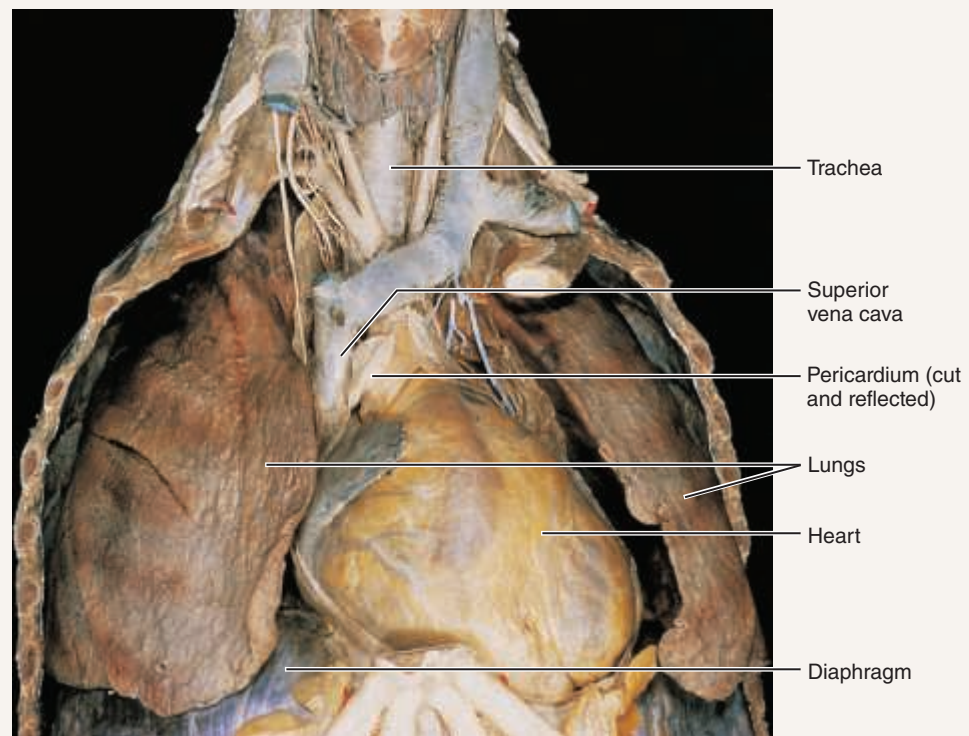
2. Examine the superficial structures of the abdominopelvic cavity. Lift the **greater omentum**, an extension of the peritoneum (serous membrane) that covers the abdominal viscera. Continuing from the stomach, trace the rest of the digestive tract (**Figure 2.4**, p. 20).

**Small intestine:** Connected to the stomach and ending just before the saclike cecum.

**Large intestine:** A large muscular tube connected to the small intestine and ending at the anus.



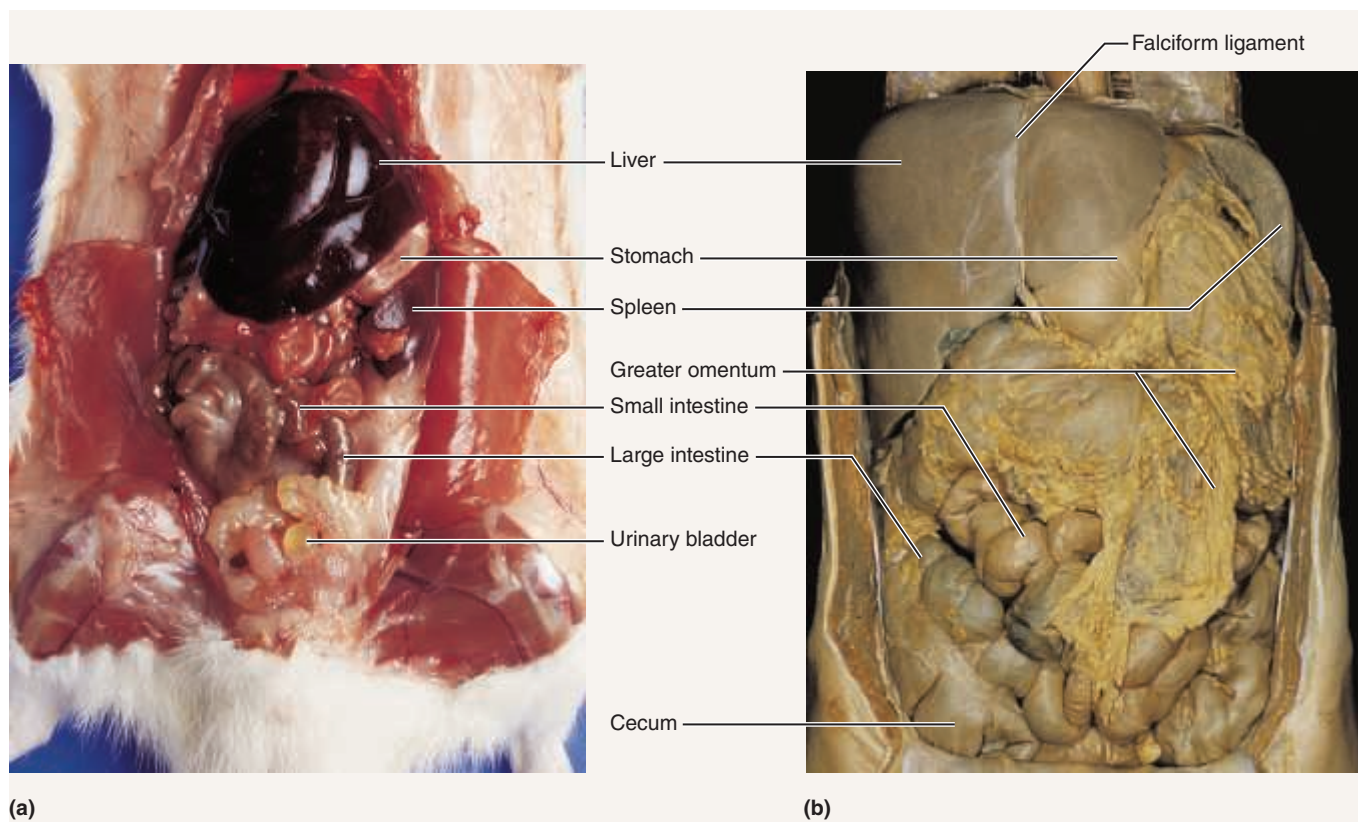
(a)



(b)

**Figure 2.3** Superficial organs of the thoracic cavity. (a) Dissected rat. (b) Human cadaver.

Text continues on next page. →



**Figure 2.4 Abdominal organs.** (a) Dissected rat, superficial view. (b) Human cadaver, superficial view.

**Cecum:** The initial portion of the large intestine.

Follow the course of the large intestine to the rectum, which is partially covered by the urinary bladder (**Figure 2.5**).

**Rectum:** Terminal part of the large intestine; continuous with the anal canal.

**Anus:** The opening of the digestive tract (through the anal canal) to the exterior.

Now lift the small intestine with the forceps to view the mesentery.

**Mesentery:** An apronlike serous membrane; suspends many of the digestive organs in the abdominal cavity. Notice that it is heavily invested with blood vessels and, more likely than not, riddled with large fat deposits.

Locate the remaining abdominal structures.

**Pancreas:** A diffuse gland; rests dorsal to and in the mesentery between the first portion of the small intestine and the stomach. You will need to lift the stomach to view the pancreas.

**Spleen:** A dark red organ curving around the left lateral side of the stomach; considered part of the lymphatic system and often called the red blood cell graveyard.

**Liver:** Large and brownish red; the most superior organ in the abdominal cavity, directly beneath the diaphragm.

**3.** To locate the deeper structures of the abdominopelvic cavity, move the stomach and the intestines to one side with the probe.

Examine the posterior wall of the abdominal cavity to locate the two kidneys (**Figure 2.5**).

**Kidneys:** Bean-shaped organs; retroperitoneal (behind the peritoneum).

**Adrenal glands:** Large endocrine glands that sit on top of each kidney; considered part of the endocrine system.

Carefully strip away part of the peritoneum with forceps and attempt to follow the course of one of the ureters to the bladder.

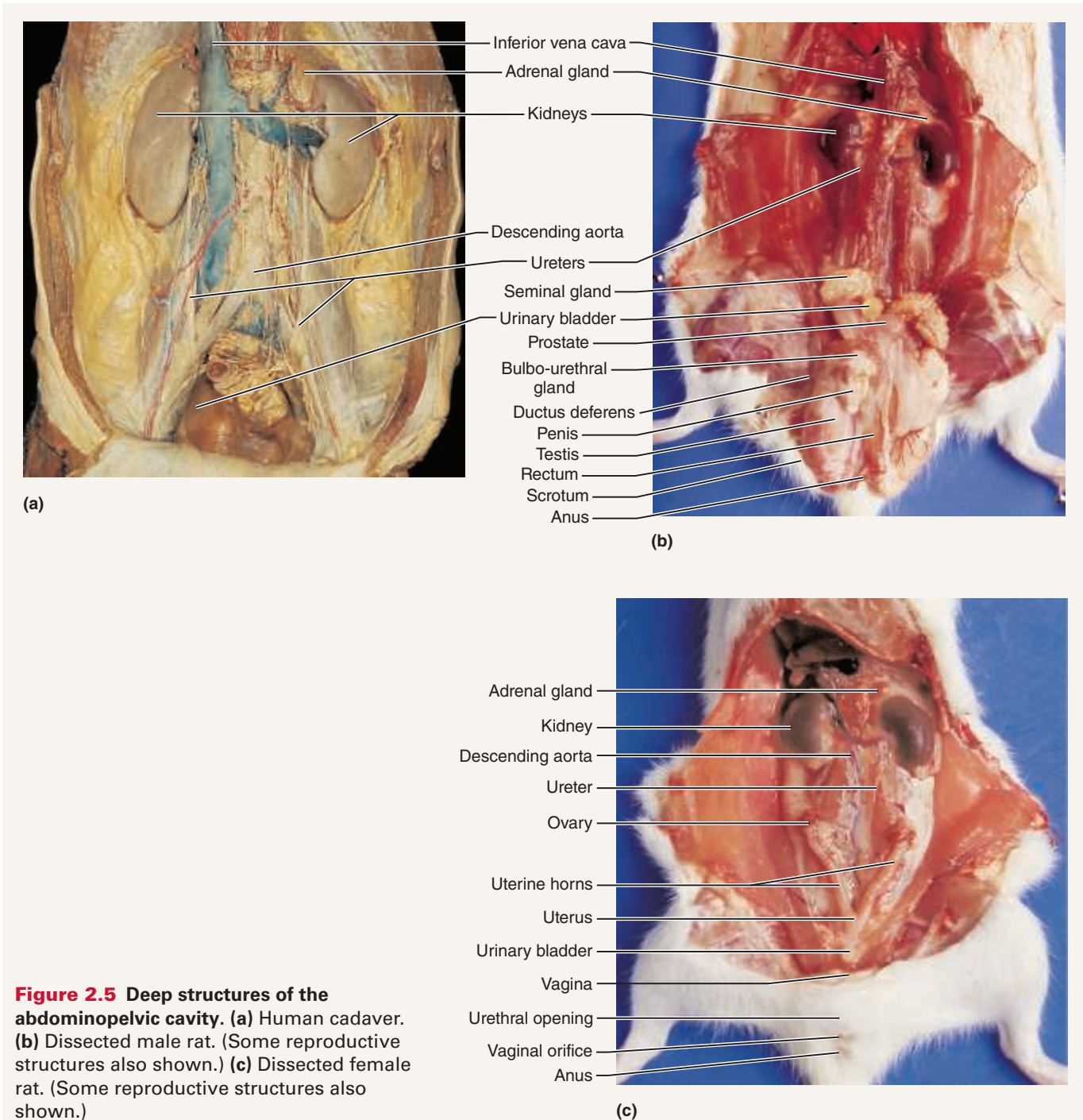
**Ureter:** Tube running from the indented region of a kidney to the urinary bladder.

**Urinary bladder:** The sac that serves as a reservoir for urine.

**4.** In the midline of the body cavity lying between the kidneys are the two principal abdominal blood vessels. Identify each.

**Inferior vena cava:** The large vein that returns blood to the heart from the lower body regions.

**Descending aorta:** Deep to the inferior vena cava; the largest artery of the body; carries blood away from the heart down the midline of the body.



**Figure 2.5** Deep structures of the abdominopelvic cavity. (a) Human cadaver. (b) Dissected male rat. (Some reproductive structures also shown.) (c) Dissected female rat. (Some reproductive structures also shown.)

5. You will perform only a brief examination of reproductive organs. If you are working with a rat, first determine if the animal is a male or female. Observe the ventral body surface beneath the tail. If a saclike scrotum and an opening for the anus are visible, the animal is a male. If three body openings—urethral, vaginal, and anal—are present, it is a female.

#### Male Rat

Make a shallow incision into the **scrotum**. Loosen and lift out one oval **testis**. Exert a gentle pull on the testis to identify the slender **ductus deferens**, or **vas deferens**,

which carries sperm from the testis superiorly into the abdominal cavity and joins with the urethra. The urethra runs through the penis and carries both urine and sperm out of the body. Identify the **penis**, extending from the bladder to the ventral body wall. Figure 2.5b indicates other glands of the male rat's reproductive system, but they need not be identified at this time.

#### Female Rat

Inspect the pelvic cavity to identify the Y-shaped **uterus** lying against the dorsal body wall and superior to the

Text continues on next page. →