Rare Tumors and Tumor-like Conditions in Urological Pathology

Antonio Lopez-Beltran
Carmen L. Menendez
Rodolfo Montironi
Liang Cheng

Springer

Rare Tumors and Tumor-like Conditions in Urological Pathology

Antonio Lopez-Beltran
Carmen L. Menendez
Rodolfo Montironi
Liang Cheng

Rare Tumors and Tumor-like Conditions in Urological Pathology

Springer

Antonio Lopez-Beltran, MD, PhD
Department of Surgery and Pathology
University of Cordoba Faculty
of Medicine
Cordoba
Spain

Carmen L. Menendez, MD
Pathology Department
Hospital de Cabueñes
Gijón
Spain

Rodolfo Montironi, MD
Department of Biomedical
Sciences and Public Health
Polytechnic University of the Marche
Region (Ancona)
Torrette
Italy

Liang Cheng, MD
Department of Pathology
Indiana University School of Medicine
Indianapolis, Indiana
USA

ISBN 978-3-319-10252-8 ISBN 978-3-319-10253-5 (eBook)
DOI 10.1007/978-3-319-10253-5
Springer Cham Heidelberg New York Dordrecht London

Library of Congress Control Number: 2014953767

© Springer International Publishing Switzerland 2015
This work is subject to copyright. All rights are reserved by the Publisher, whether the whole or part of the material is concerned, specifically the rights of translation, reprinting, reuse of illustrations, recitation, broadcasting, reproduction on microfilms or in any other physical way, and transmission or information storage and retrieval, electronic adaptation, computer software, or by similar or dissimilar methodology now known or hereafter developed. Exempted from this legal reservation are brief excerpts in connection with reviews or scholarly analysis or material supplied specifically for the purpose of being entered and executed on a computer system, for exclusive use by the purchaser of the work. Duplication of this publication or parts thereof is permitted only under the provisions of the Copyright Law of the Publisher's location, in its current version, and permission for use must always be obtained from Springer. Permissions for use may be obtained through RightsLink at the Copyright Clearance Center. Violations are liable to prosecution under the respective Copyright Law.
The use of general descriptive names, registered names, trademarks, service marks, etc. in this publication does not imply, even in the absence of a specific statement, that such names are exempt from the relevant protective laws and regulations and therefore free for general use.
While the advice and information in this book are believed to be true and accurate at the date of publication, neither the authors nor the editors nor the publisher can accept any legal responsibility for any errors or omissions that may be made. The publisher makes no warranty, express or implied, with respect to the material contained herein.

Printed on acid-free paper

Springer is part of Springer Science+Business Media (www.springer.com)

Contents

1 Renal Tumors and Tumor-Like Conditions 1
1.1 Basic Anatomy and Histology 2
1.2 Overview 2
1.3 Familial Renal Cancer 4
1.3.1 Von Hippel-Lindau (VHL) Clear Cell Renal Cell Carcinoma (RCC) 4
1.3.2 Hereditary Papillary RCC 4
1.3.3 Hereditary Leiomyomatosis RCC 4
1.3.4 Birt-Hogg-Dube Syndrome 5
1.4 Renal Cell Carcinoma 6
1.4.1 Clear Cell RCC 6
1.4.2 Multilocular Cystic Clear Cell Renal Cell Neoplasm of Low Malignant Potential 6
1.4.3 Papillary RCC 9
1.4.4 Chromophobe RCC 11
1.4.5 Hybrid Oncocytic Chromophobe Tumor (HOCT) . . . 12
1.4.6 Collecting Duct Carcinoma 14
1.4.7 Renal Medullary Carcinoma 16
1.4.8 Mucinous, Tubular and Spindle Cell Carcinoma . . . 16
1.4.9 Renal Cell Carcinoma After Neuroblastoma 20
1.4.10 RCC with Sarcomatoid or Rhabdoid Differentiation 20
1.4.11 Renal Cell Carcinoma, Unclassified 21
1.5 Proposed New and Emerging Epithelial Renal Tumors 22
1.5.1 Tubulocystic Renal Cell Carcinoma 22
1.5.2 Acquired Cystic Disease-Associated RCC 22
1.5.3 Clear Cell Papillary (Tubulo-Papillary) RCC 23
1.5.4 MiT Family Translocation RCC 25
1.5.5 Thyroid-Like Follicular Renal Cell Carcinoma 27
1.5.6 Succinic Dehydrogenase B Deficiency Associated Renal Cell Carcinoma 27
1.5.7 ALK-Translocation Renal Cell Carcinoma 28
1.5.8 Renal Cell Carcinoma with Smooth Muscle Stroma 28

1.5.9 Tuberous Sclerosis-Associated Renal Cell Carcinoma . . . 29
1.6 Benign Tumors . . . 30
1.6.1 Papillary Adenoma . . . 30
1.6.2 Metanephric Tumors . . . 30
1.6.3 Renal Oncocytoma . . . 30
1.7 Percutaneous Biopsy of Renal Tumours . . . 33
1.8 Cystic Nephroma and Mixed Epithelial and Stromal Tumors . . . 34
1.9 Soft Tissue Tumors . . . 37
1.9.1 Medullary Fibroma . . . 37
1.9.2 Juxtaglomerular Cell Tumor . . . 38
1.9.3 Glomus Tumor . . . 39
1.9.4 Angiomyolipoma . . . 39
1.9.5 Epithelioid Angiomyolipoma . . . 40
1.9.6 Leiomyoma . . . 41
1.9.7 Lipoma . . . 41
1.9.8 Hemangioma . . . 42
1.9.9 Lymphangioma . . . 42
1.9.10 Schwannoma . . . 43
1.9.11 Solitary Fibrous Tumor . . . 43
1.9.12 Leiomyosarcoma . . . 43
1.9.13 Angiosarcoma . . . 44
1.9.14 Liposarcoma . . . 44
1.9.15 Rhabdomyosarcoma . . . 45
1.9.16 Malignant Fibrous Histiocytoma . . . 45
1.9.17 Hemangiopericytoma . . . 45
1.9.18 Hemangioblastoma . . . 46
1.9.19 Osteosarcoma . . . 46
1.9.20 Other Soft Tissue Tumors . . . 47
1.10 Wilms' Tumor and Other Renal Neoplasms in Children . . . 48
1.10.1 Nephrogenic Rests and Nephroblastomatosis . . . 48
1.10.2 Nephroblastoma (Wilms' Tumor) . . . 48
1.10.3 Cystic Partially Differentiated Nephroblastoma . . . 49
1.10.4 Congenital Mesoblastic Nephroma (CMN) . . . 50
1.10.5 Clear Cell Sarcoma of Kidney . . . 52
1.10.6 Rhabdoid Tumor of Kidney . . . 52
1.10.7 Neuroblastoma . . . 52
1.10.8 Primitive Neuroectodermal Tumor (PNET) . . . 52
1.10.9 Desmoplastic Small Round Cell Tumor . . . 52
1.10.10 Synovial Sarcoma . . . 53
1.10.11 Ossifying Renal Tumor of Infancy . . . 54
1.11 Other Rare Tumors and Tumor-Like Conditions . . . 54
1.11.1 Neuroendocrine Tumors . . . 54
1.11.2 Hematopoietic and Lymphoid Tumors . . . 54
1.11.3 Germ Cell Tumors . . . 54
1.11.4 Other Rare Epithelial Tumors and Renal Cell Carcinoma in Children . . . 55
1.11.5 Tumor-Like Conditions . . . 55

1.12 Secondary Tumors 56
Suggested Reading 56

2 Tumors and Tumor-Like Conditions of Urinary Bladder, Renal Pelvis, Ureter and Urethra 63
2.1 Introduction 63
2.1.1 Basic Anatomy and Histology 63
2.2 Urinary Bladder 68
2.2.1 Urothelial Carcinoma 68
2.2.2 Flat Intraepithelial Lesions 68
2.2.3 Urothelial Carcinoma 84
2.2.4 Benign Urothelial Neoplasms 122
2.2.5 Glandular Neoplasms 128
2.2.6 Squamous Cell Neoplasms 135
2.2.7 Neuroendocrine Tumors 139
2.2.8 Soft Tissue Tumors 148
2.2.9 Malignant Melanoma 166
2.2.10 Germ Cell Tumors 167
2.2.11 Hematologic Malignancies 167
2.2.12 Tumor-Like Conditions 168
2.2.13 Metastatic Tumors and Secondary Extension 176
2.2.14 Metastatic Urothelial Carcinoma 176
2.3 The Renal Pelvis and Ureter 177
2.4 The Urethra 181
Suggested Reading 187

3 The Prostate and Seminal Vesicles 195
3.1 Basic Anatomy and Histology 196
3.1.1 The Prostate 196
3.1.2 The Seminal Vesicles and Ejaculatory Ducts 201
3.2 Adenocarcinoma of the Prostate 202
3.2.1 Preneoplastic Lesions and Conditions 202
3.3 Diagnostic Criteria for Prostate Adenocarcinoma 214
3.3.1 Histologic Features of Prostate Cancer 215
3.4 Rare Histologic Subtypes of Prostatic Carcinoma 224
3.4.1 Pseudohyperplastic Adenocarcinoma 224
3.4.2 Foamy Gland Adenocarcinoma 225
3.4.3 Atrophic Adenocarcinoma 226
3.4.4 Adenocarcinoma with Glomeruloid Features 228
3.4.5 Mucinous and Signet Ring Cell Adenocarcinoma 228
3.4.6 Oncocytic Adenocarcinoma 229
3.4.7 Lymphoepithelioma-Like Carcinoma of the Prostate 230
3.4.8 Prostatic Ductal Adenocarcinoma 232
3.4.9 Intraductal Carcinoma 237
3.4.10 Small Cell Carcinoma 239
3.4.11 Sarcomatoid Carcinoma (Carcinosarcoma) 241
3.4.12 PIN-Like Carcinoma 243
3.4.13 Pleomorphic Giant Cell Carcinoma 244

3.5 Gleason Grading of Prostate Cancer 247
3.5.1 Gleason Patterns. 248
3.5.2 Reporting Gleason Scores in Prostate Needle Biopsies 250
3.5.3 Reporting Gleason Scores in Radical Prostatectomies 251
3.5.4 Grading Variants and Variations of Adenocarcinoma of the Prostate 252
3.5.5 Correlation Between Needle Biopsy and RP Gleason Scores 252
3.5.6 Pathology of the Prostate After Treatment. 254
3.6 Pathologic Prognosis of Prostate Cancer 261
3.6.1 Prostate Biopsy 261
3.6.2 Prognostic Factors After Radical Prostatectomy . . . 266
3.7 Basic Molecular Pathology of Prostate Cancer 271
3.8 Rare Forms of Prostatic Tumours 274
3.9 Tumors and Tumor-Like Conditions of the Prostate Stroma 288
3.10 Miscellaneous Primary Tumours of the Prostate 298
3.11 Secondary Tumours Involving the Prostate 298
3.12 Seminal Vesicles 302
Suggested Reading 306

4 Testis and Paratesticular Structures 311
4.1 Basic Anatomy and Histology 312
4.2 Classification of Tumors and Tumor-Like Conditions. 313
4.2.1 Germ Cell Tumors 314
4.2.2 Intratubular Germ Cell Neoplasia, Unclassified (IGCNU) 315
4.2.3 Germ Cell Tumors of One Histologic Type. 316
4.2.4 Seminoma 316
4.2.5 Spermatocytic Seminoma 320
4.3 Non-seminomatous Germ Cell Tumors (NSGCTs). 322
4.3.1 Embryonal Carcinoma 322
4.4 Yolk Sac Tumor 326
4.4.1 Pathology 326
4.4.2 Immunohistochemistry 327
4.4.3 Genetics 330
4.5 Polyembryoma 331
4.6 Choriocarcinoma and Other Types of Throphoblastic Neoplasia 331
4.6.1 Pathology 331
4.6.2 Morphologic Variants. 332
4.6.3 Immunohistochemistry 333
4.6.4 Genetics 334
4.7 Teratoma 334
4.7.1 Pathology 334
4.7.2 Variants 334
4.7.3 Genetics 335

4.8 Burned Out GCTs 335
4.9 Tumors of More than One Histologic Type (Mixed Forms) 335
4.9.1 Pathology 336
4.9.2 Prognostic Factors 337
4.10 Tumors of Sex Cord/Gonadal Stroma 338
4.11 Benign and Malignant Leydig Cell Tumors 339
4.11.1 Pathology of Benign Tumors 339
4.11.2 Pathology of Malignant Tumors 339
4.11.3 Genetics 342
4.12 Benign and Malignant Sertoli Cell Tumors 342
4.12.1 Pathology of Benign Tumors 342
4.12.2 Pathology of Malignant Tumors 346
4.12.3 Genetics 346
4.13 Large Cell Calcifying Sertoli Cell Tumor (LCCST) 346
4.13.1 Pathology 346
4.14 Granulosa Cell Tumor of Adult Type 347
4.15 Granulosa Cell Tumor of Juvenile Type 347
4.16 Thecoma–Fibroma Type Tumors 347
4.17 Mixed or Incompletely Differentiated (Undifferentiated) Gonadal Stromal Tumors 348
4.18 Mixed Germ Cell/Sex Cord Stromal Tumor 348
4.18.1 Gonadoblastoma 348
4.18.2 Germ Cell Sex Cord/Gonadal Stromal Tumor, Unclassified 350
4.19 Other Tumors of the Testis 350
4.19.1 Carcinoid 350
4.19.2 Nephroblastoma 350
4.19.3 Lymphoma and Plasmacytoma 350
4.19.4 Leukemia 351
4.20 Other Rare Tumors 352
4.21 Testicular Metastases 353
4.22 Tumors of the Paratesticular Region 355
4.23 Tumors of Ovarian (Müllerian) Epithelial Types 355
4.24 Tumors of Collecting Ducts and Rete Testis 355
4.24.1 Adenoma 355
4.24.2 Adenocarcinoma of Rete Testis 355
4.25 Epithelial Tumors of the Epididymis 356
4.25.1 Papillary Cystadenoma of the Epididymis 356
4.25.2 Adenocarcinoma of the Epididymis 357
4.25.3 Adenomatoid Tumor 358
4.26 Mesothelioma of the Tunica Vaginalis Testis 358
4.26.1 Pathology 359
4.27 Melanotic Neuroectodermal Tumor of Infancy 360
4.28 Desmoplastic Small Round Cell Tumor 360
4.29 Soft Tissue Tumors of the Spermatic Cord 361
4.30 Tumor-Like Conditions 362
4.30.1 Intratesticular Hemorrhage 362
4.30.2 Segmental Testicular Infarction 362

4.30.3 Organized Testicular Hematocele 362
4.30.4 Inflammatory Lesions 362
4.31 Meconium Periorchitis 363
4.32 Sperm Granuloma 364
4.33 Sclerosing Lipogranuloma 364
4.34 Cysts 364
4.34.1 Epidermoid Cyst 364
4.34.2 Tubular Ectasia of the Rete Testis 364
4.34.3 Epididymal Cysts and Spermatoceles 364
4.34.4 Spermatic Cord Cysts 365
4.35 Ectopic Tissues 365
4.35.1 Ectopic Adrenocortical Tissue 365
4.35.2 Splenic-Gonadal Fusion 365
4.35.3 Lipomatosis Testis 365
4.36 Testicular Appendages 366
4.37 Other Tumor-Like Lesions 366
4.37.1 Fibrous Pseudotumor 366
4.37.2 Amyloidosis 366
4.37.3 Polyorchidism 366
4.37.4 Sertoli Cell Hyperplasia 366
4.37.5 Leydig Cell Hyperplasia 366
4.37.6 Hyperplasia of the Rete Testis 366
4.37.7 Cribriform Hyperplasia and Atypical Nuclei in the Epididymis 367
4.37.8 Reactive Mesothelial Hyperplasia 367
4.37.9 Vasitis/Epididymitis Nodosa 367
4.37.10 Proliferative Funiculitis 367
4.37.11 Embryonic Remnants 367
Suggested Reading 367

5 Penis and Scrotum 373
5.1 Basic Anatomy and Histology 374
5.1.1 Penis 374
5.1.2 Scrotum 374
5.2 Carcinoma of the Penis 374
5.2.1 Overview 374
5.2.2 Preneoplastic and Other Intraepithelial Lesions . 376
5.2.3 Squamous Cell Carcinoma, Usual Type 387
5.2.4 Variants of Squamous Cell Carcinoma 393
5.2.5 Other Carcinomas 409
5.3 Benign Tumors and Tumor-Like Conditions 411
5.3.1 Benign Tumors of Epithelial Origin 411
5.3.2 Benign Human Papillomavirus-Associated Lesions 411
5.3.3 Myointimoma 413
5.3.4 Other Benign Tumors 416
5.4 Malignant Soft Tissue Tumors 416
5.4.1 Kaposi Sarcoma 417
5.4.2 Leiomyosarcoma 418

5.4.3 Epithelioid Sarcoma 419
5.4.4 Other Soft Tissue Sarcomas. 419
5.5 Other Rare Tumors. 420
5.5.1 Primary Malignant Melanoma of the Penis. 420
5.5.2 Clear Cell Sarcoma (Malignant Melanoma of Soft Parts) 420
5.5.3 Lymphoma. 420
5.6 Secondary Tumors 421
5.7 Carcinoma of the Scrotum 422
5.7.1 Overview 422
5.7.2 Preneoplastic Lesions 423
5.7.3 Squamous Cell Carcinoma 423
5.8 Other Carcinomas 423
5.8.1 Basal Cell Carcinoma 423
5.8.2 Merkel Cell Carcinoma 423
5.8.3 Extramammary Paget Disease. 423
5.9 Benign Tumors and Tumor-Like Conditions. 427
5.9.1 Scrotal Calcinosis 427
5.9.2 Sclerosing Lipogranuloma of the Scrotum 429
5.9.3 Angiokeratoma 429
5.9.4 Fat Necrosis. 430
5.9.5 Verruciform Xanthoma 430
5.9.6 Spindle Cell Nodule (Inflammatory Myofibroblastic Tumor). 432
5.9.7 Epidermal Cyst 432
5.9.8 Other Benign Lesions 432
5.10 Soft Tissue Tumors 433
5.11 Other Rare Tumors. 433
5.12 Secondary Tumors 433
Suggested Reading 435

Renal Tumors and Tumor-Like Conditions

1

Contents

1.1 **Basic Anatomy and Histology** 2

1.2 **Overview** 2

1.3 **Familial Renal Cancer** 4
1.3.1 Von Hippel-Lindau (VHL) Clear Cell Renal Cell Carcinoma (RCC) 4
1.3.2 Hereditary Papillary RCC 4
1.3.3 Hereditary Leiomyomatosis RCC 4
1.3.4 Birt-Hogg-Dube Syndrome 5

1.4 **Renal Cell Carcinoma** 6
1.4.1 Clear Cell RCC 6
1.4.2 Multilocular Cystic Clear Cell Renal Cell Neoplasm of Low Malignant Potential 6
1.4.3 Papillary RCC 9
1.4.4 Chromophobe RCC 11
1.4.5 Hybrid Oncocytic Chromophobe Tumor (HOCT) 12
1.4.6 Collecting Duct Carcinoma 14
1.4.7 Renal Medullary Carcinoma 16
1.4.8 Mucinous, Tubular and Spindle Cell Carcinoma 16
1.4.9 Renal Cell Carcinoma After Neuroblastoma 20
1.4.10 RCC with Sarcomatoid or Rhabdoid Differentiation 20
1.4.11 Renal Cell Carcinoma, Unclassified 21

1.5 **Proposed New and Emerging Epithelial Renal Tumors** 22
1.5.1 Tubulocystic Renal Cell Carcinoma 22
1.5.2 Acquired Cystic Disease-Associated RCC 22
1.5.3 Clear Cell Papillary (Tubulo-Papillary) RCC 23
1.5.4 MiT Family Translocation RCC 25
1.5.5 Thyroid-Like Follicular Renal Cell Carcinoma 27
1.5.6 Succinic Dehydrogenase B Deficiency Associated Renal Cell Carcinoma 27
1.5.7 ALK-Translocation Renal Cell Carcinoma 28
1.5.8 Renal Cell Carcinoma with Smooth Muscle Stroma 28
1.5.9 Tuberous Sclerosis-Associated Renal Cell Carcinoma 29

1.6 **Benign Tumors** 30
1.6.1 Papillary Adenoma 30
1.6.2 Metanephric Tumors 30
1.6.3 Renal Oncocytoma 30

1.7 **Percutaneous Biopsy of Renal Tumours** 33

1.8 **Cystic Nephroma and Mixed Epithelial and Stromal Tumors** 34

1.9 **Soft Tissue Tumors** 37
1.9.1 Medullary Fibroma 37
1.9.2 Juxtaglomerular Cell Tumor 38
1.9.3 Glomus Tumor 39
1.9.4 Angiomyolipoma 39
1.9.5 Epithelioid Angiomyolipoma 40
1.9.6 Leiomyoma 41
1.9.7 Lipoma 41
1.9.8 Hemangioma 42
1.9.9 Lymphangioma 42
1.9.10 Schwannoma 43
1.9.11 Solitary Fibrous Tumor 43
1.9.12 Leiomyosarcoma 43
1.9.13 Angiosarcoma 44
1.9.14 Liposarcoma 44
1.9.15 Rhabdomyosarcoma 45
1.9.16 Malignant Fibrous Histiocytoma 45
1.9.17 Hemangiopericytoma 45
1.9.18 Hemangioblastoma 46
1.9.19 Osteosarcoma 46
1.9.20 Other Soft Tissue Tumors 47

A. Lopez-Beltran et al., *Rare Tumors and Tumor-like Conditions in Urological Pathology*,
DOI 10.1007/978-3-319-10253-5_1, © Springer International Publishing Switzerland 2015

1.10 **Wilms' Tumor and Other Renal Neoplasms in Children** 48
1.10.1 Nephrogenic Rests and Nephroblastomatosis 48
1.10.2 Nephroblastoma (Wilms' Tumor) 48
1.10.3 Cystic Partially Differentiated Nephroblastoma 49
1.10.4 Congenital Mesoblastic Nephroma (CMN) 50
1.10.5 Clear Cell Sarcoma of Kidney 52
1.10.6 Rhabdoid Tumor of Kidney 52
1.10.7 Neuroblastoma 52
1.10.8 Primitive Neuroectodermal Tumor (PNET) 52
1.10.9 Desmoplastic Small Round Cell Tumor 52
1.10.10 Synovial Sarcoma 53
1.10.11 Ossifying Renal Tumor of Infancy. 54
1.11 **Other Rare Tumors and Tumor-Like Conditions** 54
1.11.1 Neuroendocrine Tumors. 54
1.11.2 Hematopoietic and Lymphoid Tumors 54
1.11.3 Germ Cell Tumors 54
1.11.4 Other Rare Epithelial Tumors and Renal Cell Carcinoma in Children 55
1.11.5 Tumor-Like Conditions 55
1.12 **Secondary Tumors** 56
Suggested Reading 56

1.1 Basic Anatomy and Histology

- The kidneys are paired retroperitoneal organs that normally extend from 12th thoracic vertebra to the 3rd lumbar vertebra. The average adult kidney is 11–12 cm long. It weighs 125–170 g in men and 115–155 g in women.
- The three defined regions, upper polo, middle zone and lower pole usually reflect regions drained by three lobar veins.
- The normal adult kidney has a minimum of 10–14 lobes, each composed of medullary pyramid surrounded by a cap of cortex.
- The renal parenchyma consists of the cortex and the medulla. The cortex is the nephron-containing parenchyma. The renal medulla is divided into outer medulla and the inner medulla or papilla. The papilla protrudes into a minor calyx. Its tip has 20–70 openings of the papillary collecting ducts (Bellini ducts).
- The cortex contains glomeruli, proximal and distal convoluted tubules, connecting tubules, and the initial portion of the collecting ducts, as well as interlobular vessels, arterioles, capillaries, and lymphatics. The interstitial space is scant; it contains the peritubular capillary plexus and inconspicuous numbers of interstitial fibroblasts and reticulum cells.

1.2 Overview

- The current classification of renal cell tumors was proposed in 2004 by the World Health Organization (WHO) and has been recently updated by the International Society of Urological Pathologists (Table 1.1). It describes categories and entities based on pathological and genetic analyses. A number of emerging or provisional categories are also incorporated (Table 1.2)
- Rare new entities and morphologic variants of common categories have recently been described and represent important diagnostic challenges in daily practice.

Table 1.1 International Society of Urological Pathologists (ISUP) Vancouver modification of WHO (2004) Histologic Classification of Renal Tumors

Renal cell tumors
Papillary adenoma
Oncocytoma
Clear cell renal cell carcinoma
Multilocular cystic clear cell renal cell neoplasm of low malignant potential
Papillary renal cell carcinoma
Chromophobe renal cell carcinoma
Hybrid oncocytic chromophobe tumor
Carcinoma of the collecting ducts of Bellini
Renal medullary carcinoma
MiT family translocation renal cell carcinoma
Xp11 translocation renal cell carcinoma
t(6;11) renal cell carcinoma
Carcinoma associated with neuroblastoma
Mucinous tubular and spindle cell carcinoma
Tubulocystic renal cell carcinoma
Acquired cystic disease associated renal cell carcinoma
Clear cell (tubulo) papillary renal cell carcinoma
Hereditary leiomyomatosis renal cell carcinoma syndrome-associated renal cell carcinoma
Renal cell carcinoma, unclassified
Metanephric tumors
Metanephric adenoma
Metanephric adenofibroma
Metanephric stromal tumor
Nephroblastic tumors
Nephrogenic rests
Nephroblastoma
Cystic partially differentiated nephroblastoma
Mesenchymal tumors occurring mainly in children
Clear cell sarcoma
Rhabdoid tumor
Congenital mesoblastic nephroma
Ossifying renal tumor of infants
Mesenchymal tumors occurring mainly in adults
Leiomyosarcoma (including renal vein)
Angiosarcoma
Rhabdomyosarcoma
Malignant fibrous histiocytoma
Hemangiopericytoma
Osteosarcoma
Synovial sarcoma
Angiomyolipoma
Epithelioid angiomyolipoma
Leiomyoma

Table 1.1 (continued)

Hemangioma
Lymphangioma
Juxtaglomerular cell tumor
Renomedullary interstitial cell tumor
Schwannoma
Solitary fibrous tumor
Mixed mesenchymal and epithelial tumors
Cystic nephroma/mixed epithelial stromal tumor
Neuroendocrine tumors
Carcinoid (low-grade neuroendocrine tumor)
Neuroendocrine carcinoma (high-grade neuroendocrine tumor)
Primitive neuroectodermal tumor
Neuroblastoma
Pheochromocytoma
Hematopoietic and lymphoid tumors
Lymphoma
Leukemia
Plasmacytoma
Germ cell tumors
Teratoma
Choriocarcinoma
Metastatic tumors
Other tumors

Table 1.2 Proposed New Renal Epithelial Tumors and emerging Tumor Entities

New epithelial tumors
Tubulocystic renal cell carcinoma
Acquired cystic disease associated renal cell carcinoma
Clear cell (tubulo) papillary renal cell carcinoma
MiT family translocation renal cell carcinoma including t(6;11) renal cell carcinoma
Hereditary leiomyomatosis renal cell carcinoma syndrome associated renal cell carcinoma
Emerging tumor entities
Thyroid-like follicular renal cell carcinoma
Succinic dehydrogenase B deficiency associated renal cell carcinoma
ALK-translocation renal cell carcinoma
Other
Renal cell carcinoma with smooth muscle stroma
Tuberous Sclerosis-associated Renal Cell Carcinoma

1.3 Familial Renal Cancer

- Hereditary renal cancers show a tendency to be multiple and bilateral, may have a family history, and present at an earlier age. Known inherited syndromes that predispose to renal tumors are listed in Table 1.3.

1.3.1 Von Hippel-Lindau (VHL) Clear Cell Renal Cell Carcinoma (RCC)

- Like its sporadic counterpart, VHL clear cell RCC harbors defective VHL tumor suppressor genes. Genetic alteration in the VHL gene in the tumor can include deletion, nonsense or frame-shift mutations, mis-sense mutations or methylation.

1.3.2 Hereditary Papillary RCC

- Hereditary papillary RCC are typically bilateral, multifocal type 1 papillary RCC. Genetic alterations involve a proto-oncogene, c-MET, located at 7q31.1. Similar to what is found in sporadic papillary renal cell carcinoma, trisomy 7 and 17 are identified.

1.3.3 Hereditary Leiomyomatosis RCC

- Hereditary leiomyomatosis associated-RCC patients develop cutaneous and uterine leiomyomas and one third of patients develop RCC. It was considered as a variant of type 2 papillary RCC. The pathologic findings in this disease are caused by germline mutations in the fumarate hydratase gene located at 1q42.
- Architectural patterns are papillary, tubulopapillary, tubular, solid or mixed. The morphologic hallmark of the hereditary leiomyomatosis-RCC, is the presence of large nucleus with a very prominent eosinophilic nucleolus, surrounded by a clear halo. These tumors are associated with poor prognosis.
- It is now recognized a unique morphotype of RCC. The renal tumors have a papillary, alveolar, solid or tubular architecture with the characteristic features being a large nucleus and a prominent nucleolus, with a clear peripheral halo These tumors behave aggressively and have a poor prognosis when compared to other hereditary forms of RCC, or clear cell and papillary RCC (Fig. 1.1).

Table 1.3 Familial renal tumors

Syndrome	Gene	Tumor
Von Hippel-Lindau (VHL)	VHL (3p25)	Clear cell
Tuberous Sclerosis	TSC1, TSC2	Angiomyolipoma, clear cell, other
Familial renal carcinoma	Gene not identified	Clear cell
Constitutional chromosome 3 translocation	Responsible gene not found[a]	Clear cell
Hereditary PRCC	c-MET	Papillary type 1
Birt-Hogg-Dube (BHD)	BHD	Chromophobe[b]
Familial oncocytoma	Loss of multiple chromosomes	Oncocytoma
Hereditary leiomyomatosis RCC	FH	Papillary type 2

[a]VHL gene mutated in some families
[b]Renal oncocytomas, hybrid oncocytic and clear cell carcinomas may occur

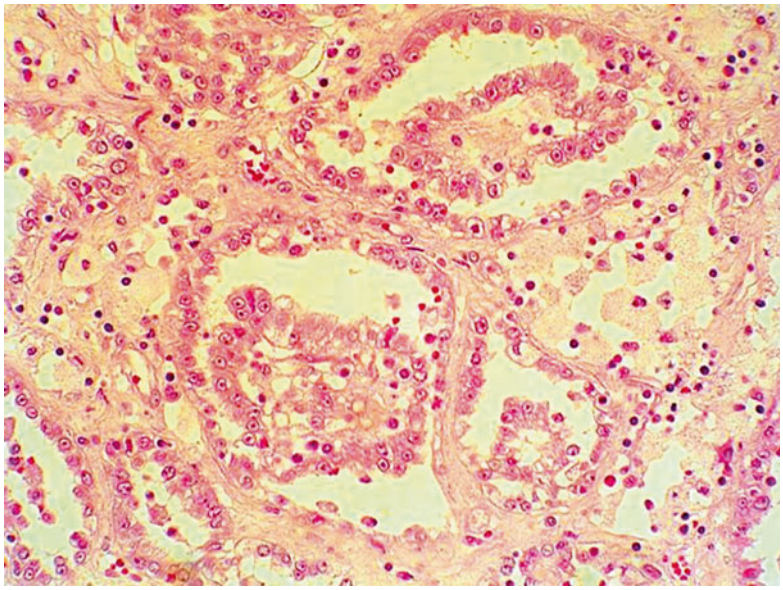

Fig. 1.1 Hereditary leiomyomatosis associated renal cell carcinoma

- HLRCC leiomyomas frequently have increased cellularity, multinucleated cells, and atypia. All cases show tumor nuclei with large orangeophilic nucleoli surrounded by a perinucleolar halo similar to the changes found in HLRCC. Occasional mitoses may be seen; however, the tumors did not fulfill the criteria for malignancy.

1.3.4 Birt-Hogg-Dube Syndrome

- Birt-Hogg-Dubé is an autosomal dominant cancer syndrome characterized by benign skin and renal tumors, and spontaneous pneumothorax. The disease related gene has been mapped to chromosome 17p11.2.
- Birt-Hogg-Dubé is characterized by a spectrum of mutations, and clinical heterogeneity among and within families. Renal epithelial tumors with hybrid features are seen in this syndrome (Figs. 1.2 and 1.3).

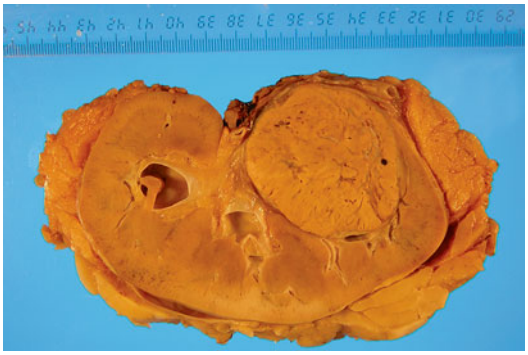

Fig. 1.2 Gross features in RCC associated with Birt-Hogg-Dubé syndrome

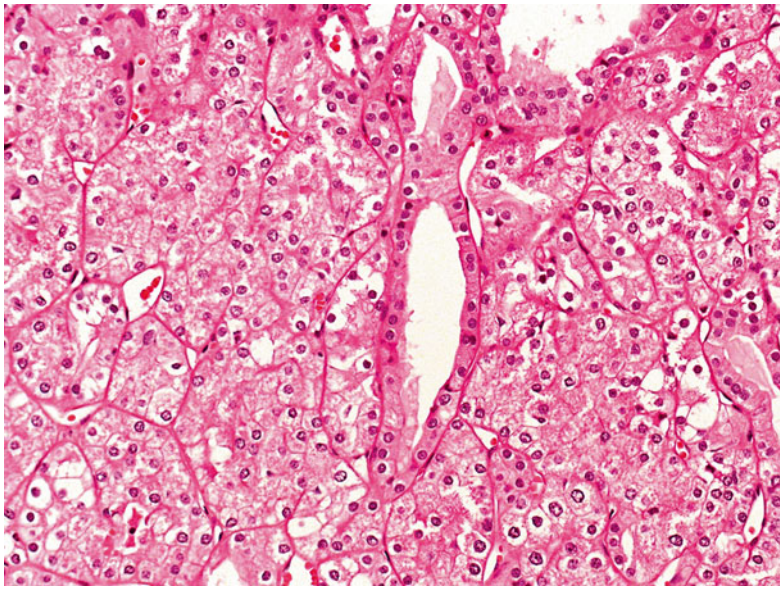

Fig. 1.3 Hybrid RCC with oncocytic and clear cells associated with Birt-Hogg-Dubé syndrome

1.4 Renal Cell Carcinoma

1.4.1 Clear Cell RCC

- Most clear cell RCC are variably sized solitary cortical neoplasms, rarely bilateral (<5 %) or multicentric (4 %), typically golden yellow. Necrosis, cystic degeneration, hemorrhage, calcification, ossification, and extension into the renal vein may occur. Clear cell tumors of any size are considered malignant.
- Microvascular invasion and microscopic tumor coagulative necrosis may be relevant predictors in low stage RCC (Table 1.4). Clear cell RCC has a worse prognosis when compared with chromophobe or papillary subtypes, and may progress into a sarcomatoid carcinoma which is an ominous prognostic sign (Figs. 1.4 and 1.5).
- The international Society of Urological Pathologists (ISUP) suggested that clear cell RCC grading should be based upon nucleolar features and not Fuhrman grading (Table 1.5). Sporadic clear cell RCC displays frequent chromosome 3p losses.
- Clear cell RCC may have acidophilic cytoplasm, hemangioblastoma-like, angioleiomyoma-like stroma or pseudo-papillary architecture but retains the characteristic 3p loss.

1.4.2 Multilocular Cystic Clear Cell Renal Cell Neoplasm of Low Malignant Potential

- The ISUP modification of the current 2004 WHO classification of kidney tumors recognizes multilocular cystic clear cell renal cell neoplasm of low malignant potential (MCNLMP) as a variant of clear cell RCC with a good prognosis.
- This is a tumor entirely composed of cysts of variable size separated from the kidney by a fibrous capsule. The cyst are lined by a single layer of clear to pale cells but occasionally shows a few small papillae. The septa are composed of fibrous tissue that may have epithelial cells with clear cytoplasm that resemble those lining the cysts (Figs. 1.6, 1.7 and 1.8).
- Cases with expansive nodules are excluded. VHL gene mutations in MCNLMP supports its classification as a type of clear cell RCC.
- No progression of MCNLMP has been reported.

Table 1.4 TNM classification of renal cell carcinoma (2010)

PrimaryTumor (T)	
TX	Primary tumor cannot be assessed
T0	No evidence of primary tumor
T1	Tumor ≤7 cm in greatest dimension, limited to the kidney
T1a	Tumor ≤4 cm in greatest dimension, limited to the kidney
T1b	Tumor >4 cm but ≤7 cm in greatest dimension, limited to the kidney
T2	Tumor >7 cm in greatest dimension, limited to the kidney
T2a	Tumor >7 cm but ≤10 cm in greatest dimension, limited to the kidney
T2b	Tumor >10 cm, limited to the kidney
T3	Tumor extends into major veins or perinephric tissues but not into the ipsilateral adrenal gland and not beyond the Gerota fascia
T3a	Tumor grossly extends into the renal vein or its segmental (muscle-containing) branches, or tumor invades perirenal and/or renal sinus fat but not beyond the Gerota fascia
T3b	Tumor grossly extends into the vena cava below the diaphragm
T3c	Tumor grossly extends into the vena cava above the diaphragm or invades the wall of the vena cava
T4	Tumor invades beyond the Gerota fascia (including contiguous extension into the ipsilateral adrenal gland)
Regional lymph nodes (N)	
NX	Regional lymph nodes cannot be assessed
N0	No regional lymph node metastasis
N1	Metastasis in regional lymph node(s)
Distant metastasis (M)	
M0	No distant metastasis
M1	Distant metastasis

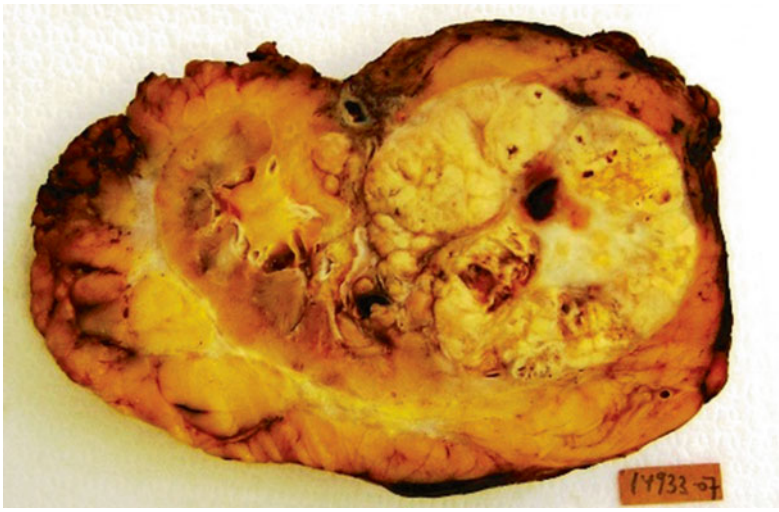

Fig. 1.4 Gross features of clear cell renal cell carcinoma

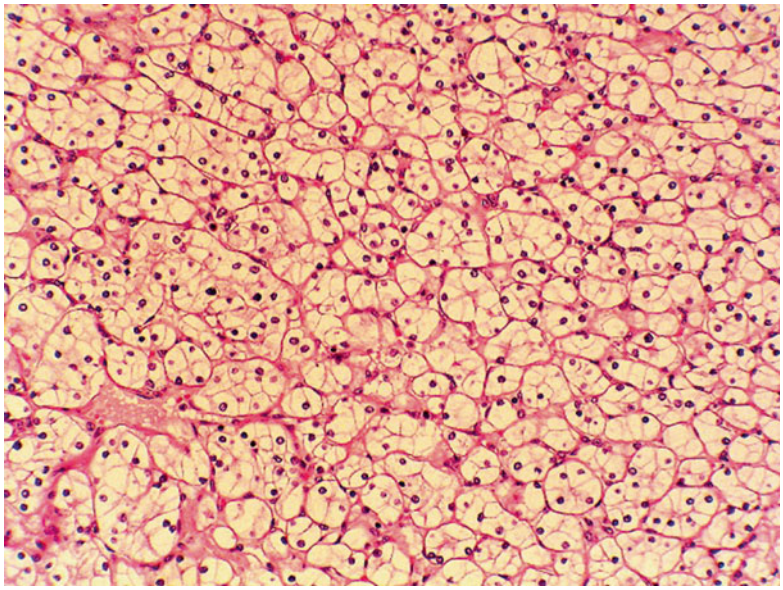

Fig. 1.5 Microscopic features of clear cell renal cell carcinoma

Table 1.5 International Society of Urological Pathology Nucleolar Grading System

Grade	Tumor description
1	Inconspicuous or absent nucleoli at 400× magnification
2	Nucleoli distinctly visible at 400× but inconspicuous or invisible at 100× magnification
3	Nucleoli distinctly visible at 100× magnification
4	Rhabdoid or sarcomatoid differentiation, or containing tumor giant cells or showing extreme nuclear pleomorphism with clumping of chromatin

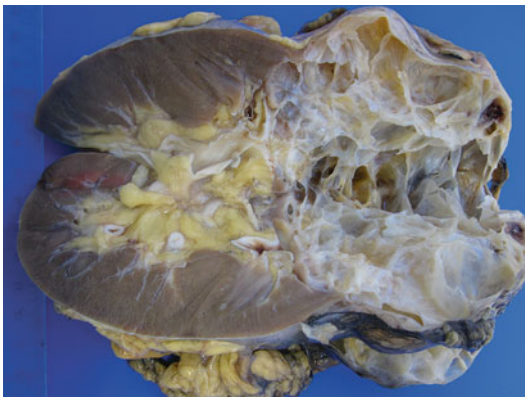

Fig. 1.6 Multilocular cystic renal cell neoplasia of low malignant potential (gross features)

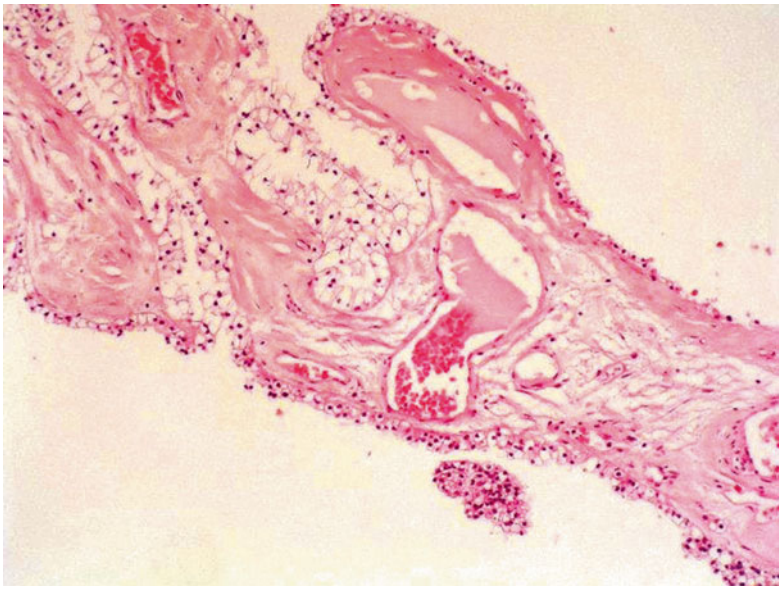

Fig. 1.7 Multilocular cystic renal cell neoplasia of low malignant potential (histologic features)

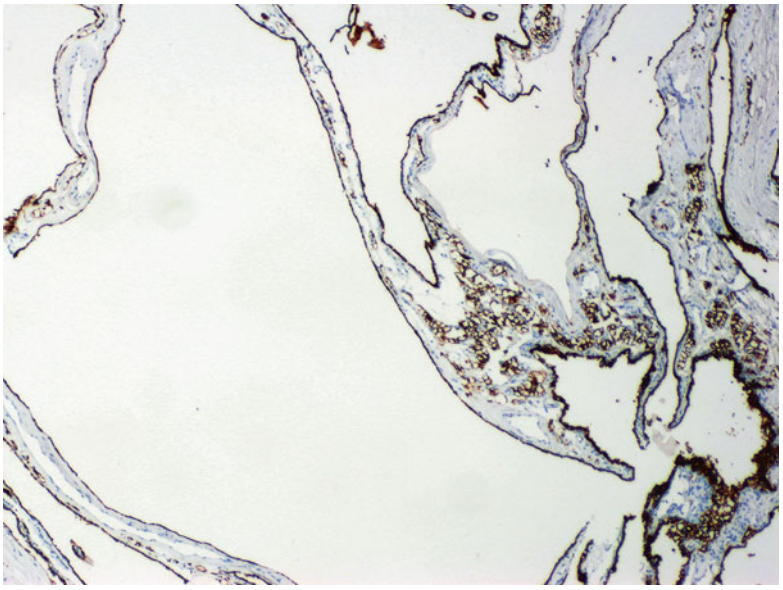

Fig. 1.8 Multilocular cystic renal cell neoplasia of low malignant potential. Expression of CAIX in the neoplastic cells

1.4.3 Papillary RCC

- Papillary RCC has a less aggressive clinical course than clear cell RCC. Papillary RCC has variable proportions of papillae and may be bilateral or multifocal with hemorrhage, necrosis or cystic degeneration. The papillae contain a fibrovascular core with aggregates of foamy macrophages, calcified concretions and frequent hemosiderin granules.
- Cellular type 1 and type 2 tumors have papillae covered by small cells with scanty cytoplasm arranged in a single layer in type1, and tumor cells of higher nuclear grade, eosinophilic cytoplasm and pseudostratified nuclei in type 2. Type 1 tumors have longer survival (Figs. 1.9, 1.10 and 1.11).
- Trisomy or tetrasomy 7, trisomy 17 and loss of chromosome Y are the cytogenetic signature. Stage, tumor proliferation and sarcomatoid change being correlated with outcome. It has been suggested that papillary RCC grading should be based upon nucleolar features and not Fuhrman grading.

Fig. 1.9 Gross features of papillary renal cell carcinoma

- Age and sex distribution of papillary RCC is similar to clear cell RCC. Recent molecular genetic studies provide evidences for the independent origin of multifocal papillary tumors in patients with papillary RCC. An oncoytic variant of papillary RCC has been reported. One patient died of metastases on follow-up (Figs. 1.12 and 1.13).

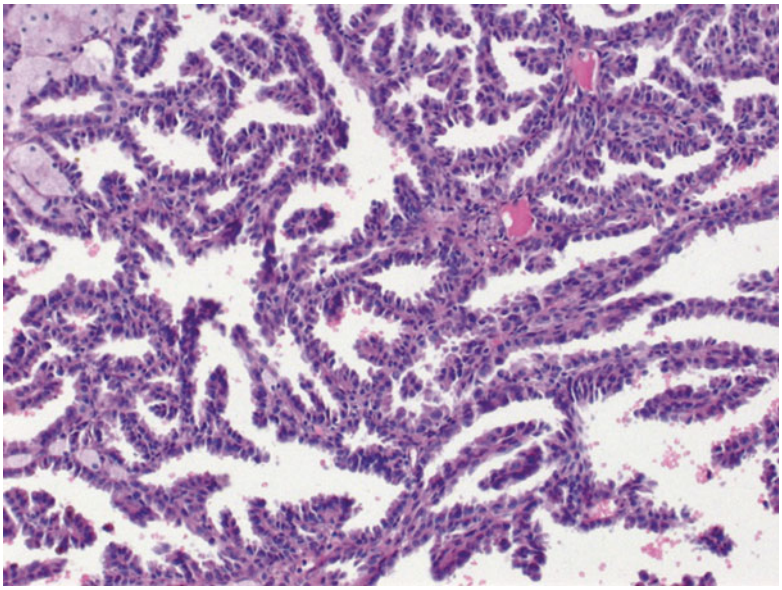

Fig. 1.10 Microscopic features of papillary carcinoma type 1

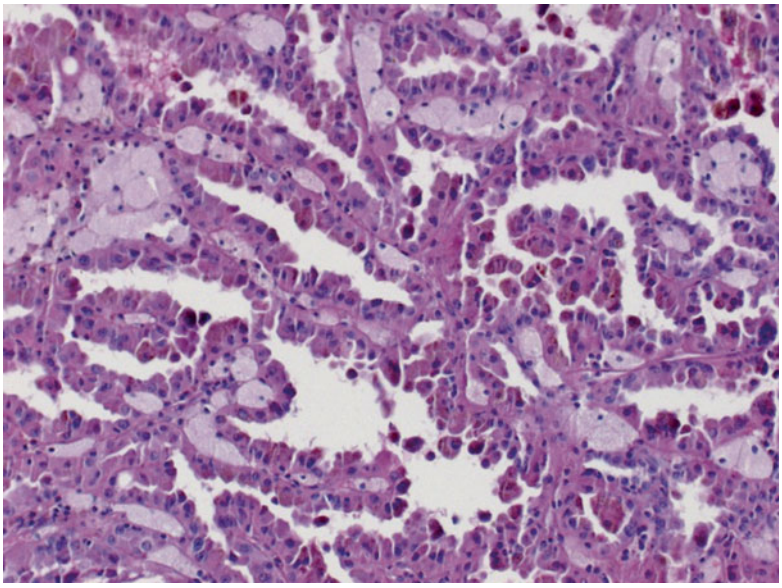

Fig. 1.11 Microscopic features of papillary carcinoma type 2

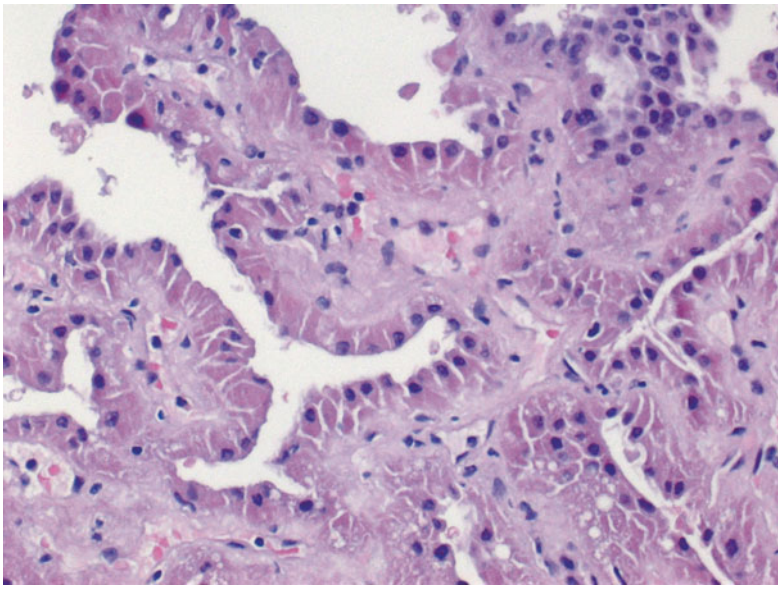

Fig. 1.12 Microscopic features of the oncocytic type of papillary carcinoma

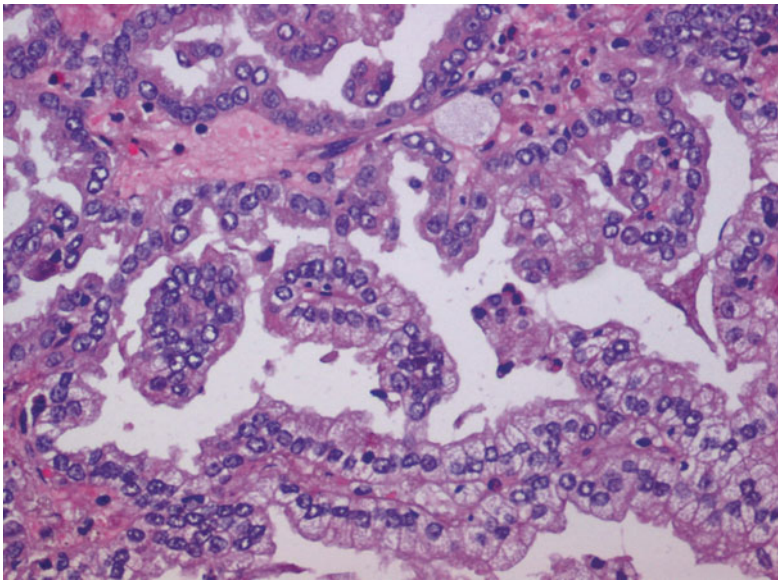

Fig. 1.13 Papillary carcinoma with focal clear cell change

1.4.4 Chromophobe RCC

- Less aggressive than other RCC, the chromophobe type is characterised by huge pale cells with reticulated cytoplasm and prominent cell membrane. It accounts for 5 % of renal epithelial tumors.
- Chromophobe RCC is solid and appears orange turning grey or sandy after fixation. The eosinophilic variant needs to be differentiated from oncocytoma. Sarcomatoid transformation is associated to aggressive disease. Diffuse cytoplasmic Hale's iron colloid stain is characteristic (Figs. 1.14, 1.15 and 1.16).

- The relationship between oncocytoma and chromophobe RCC is still unclear. Both seems to derive from the intercalated cell of the collecting duct, both have rearrangement of mitochondrial DNA, increased mitochondria in oncocytoma and numerous mitochondria-derived microvesicles in chromophobe RCC, and both are frequently observed in oncocytosis with or without Birt-Hogg-Dubé syndrome.
- There are reports of hybrid tumor composed of oncocytic and chromophobe elements. Therefore, oncocytoma might be the benign counterpart of chromophobe RCC. Loss of several chromosomes characterises chromophobe RCC. Recognising occassional occurrence of metastases and 10 % mortality is of clinical relevance.
- At diagnosis most patients are in the sixth decade, stage T1 or T2 (86 %) and similar gender incidence. Fuhrman grading is not appropriated to grade chromophome RCC with an international consensus on that chromophobe RCC should not be graded at present.

Fig. 1.14 Gross features of chromophobe renal cell carcinoma

1.4.5 Hybrid Oncocytic Chromophobe Tumor (HOCT)

- Described as tumors having a mixture of cells with the morphologic features of those seen in chromophobe RCC and renal oncocytoma (Figs. 1.17 and 1.18).
- HOCTs occur in three clinical situations: (i) being sporadic, (ii) in association with renal oncocytosis/oncocytomatosis, and (iii) in patients with the Birt-Hogg-Dubé syndrome (BHD). It seems that tumors from all three groups share similar morphologic features but that they have a differing molecular genetic background.

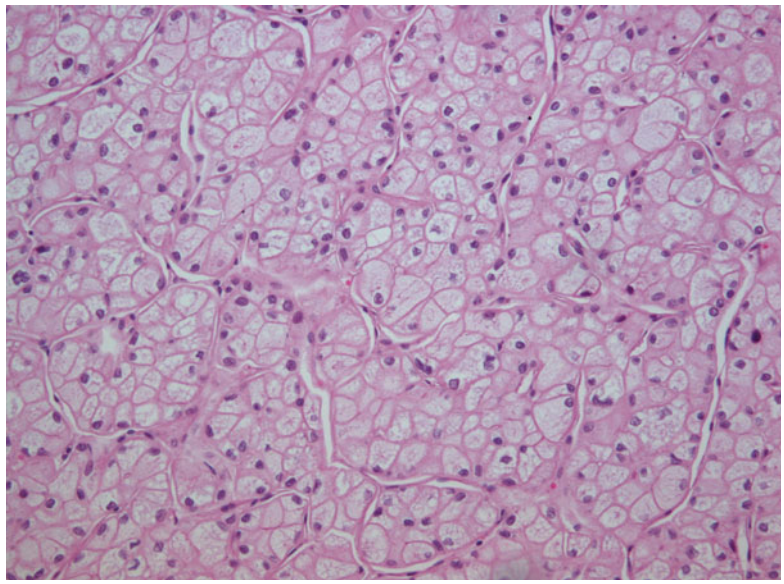

Fig. 1.15 Microscopic features of classic-type chromophobe renal cell carcinoma

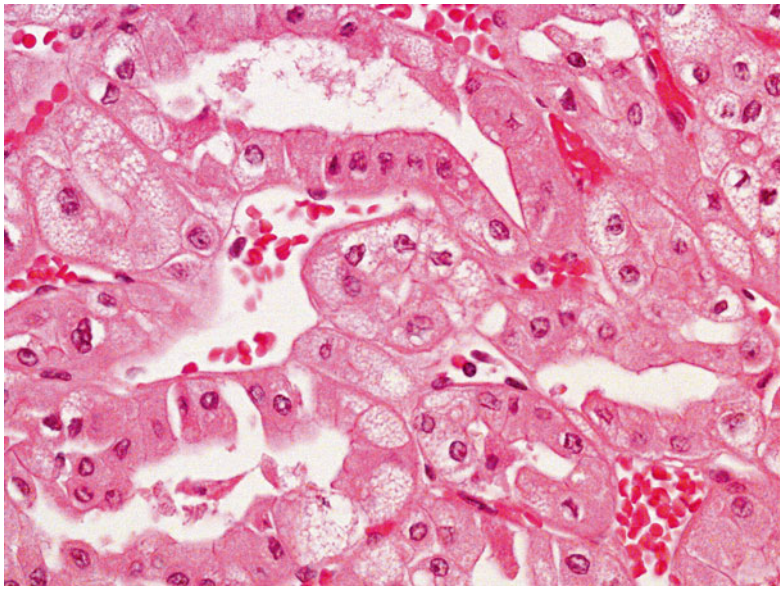

Fig. 1.16 Microscopic features of eosinophilic chromophobe renal cell carcinoma

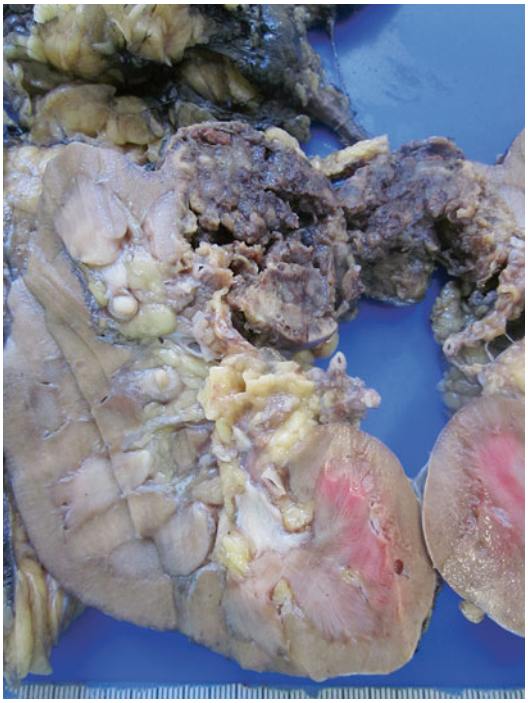

Fig. 1.17 Gross features of a case of hybrid chromophobe-oncocytoma tumor

- Sporadic HOCTs are composed of neoplastic cells predominantly arranged in a solid-alveolar pattern, with nuclei showing mild nuclear pleomorphism and abundant granular eosinophilic to oncocytic cytoplasm. Neoplastic cells have a perinuclear halo and are occasional binucleate. No raisinoid nuclei of the type seen in classic chromophobe RCC are present. Usually tumor cells resemble cells of oncocytoma with perinuclear cytoplasmic clearing, and, occasional, small tubules may be present.
- HOCTs in oncocytosis/oncocytomatosis are almost identical to those tumors that occur sporadically, being composed of sheets of cells separated by a delicate vasculature. The cells are round to polygonal with finely granular cytoplasm, and the nuclei are slightly pleomorphic and irregular with visible nucleoli. No typical raisinoid nuclei are seen, and mitotic figures are rare.
- HOCTs associated with BHD typically show three morphologic patterns: (i) an admixture of areas typical of oncocytoma and chromophobe RCC; (ii) scattered chromophobe cells in the background of a typical oncocytoma; and (iii) large eosinophilic cells with intracytoplasmic vacuoles. In these tumors, the nuclei are often more pleomorphic than other forms of HOCT and occasionally have a “raisinoid” morphology.