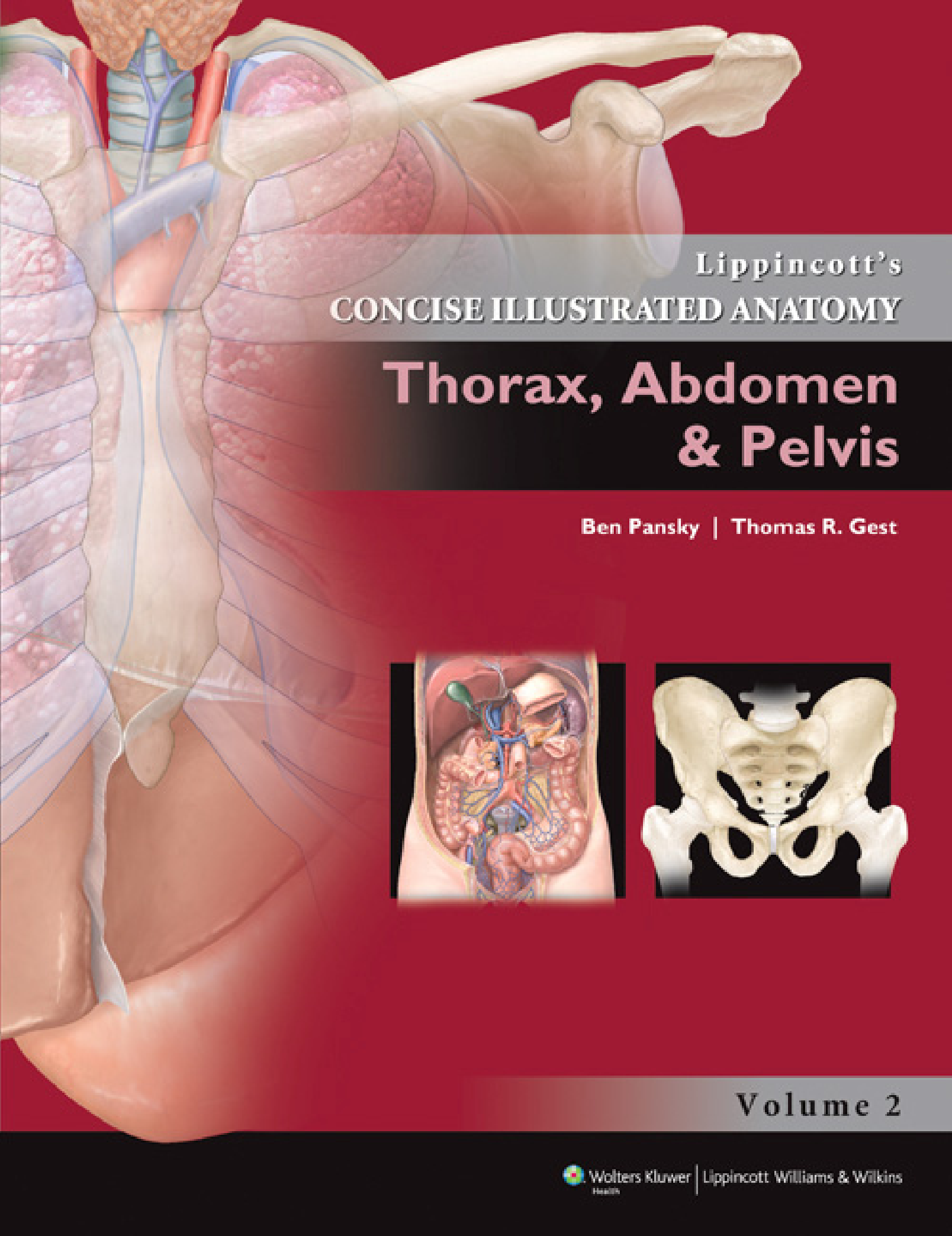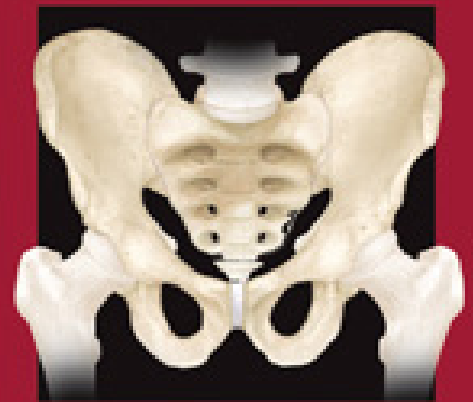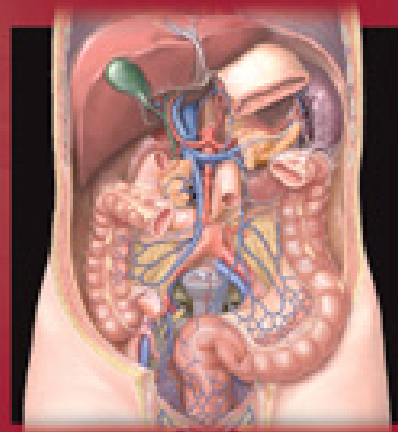


Lippincott's
CONCISE ILLUSTRATED ANATOMY

Thorax, Abdomen & Pelvis

Ben Pansky | Thomas R. Gest



Volume 2

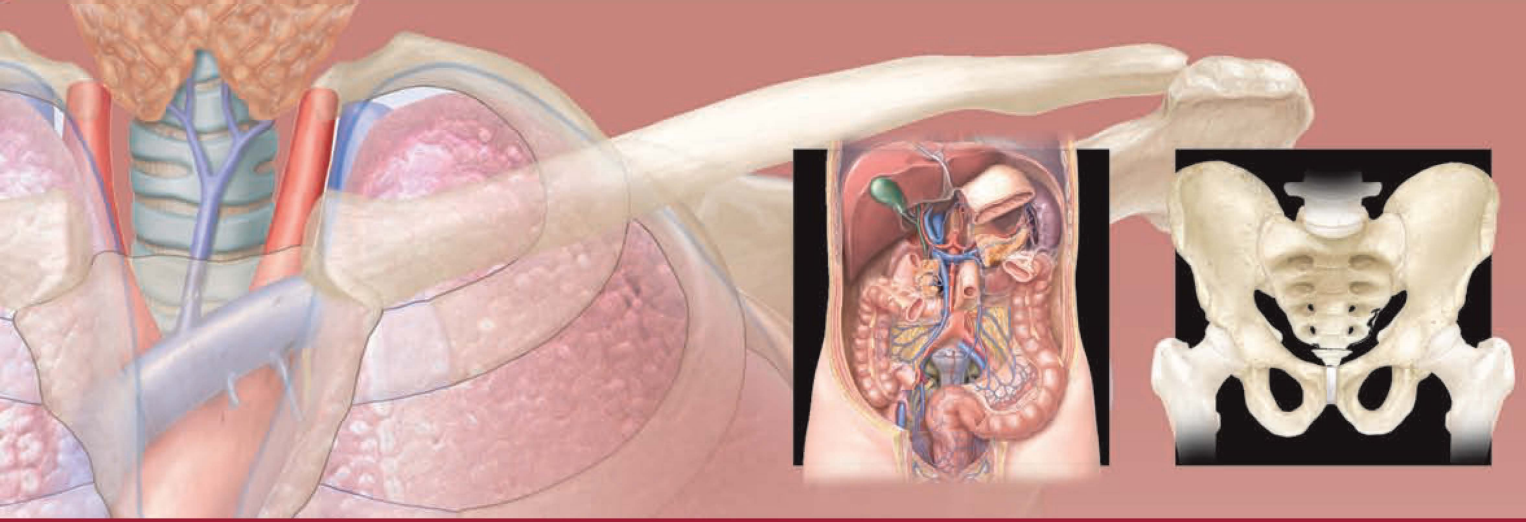
Lippincott's
CONCISE ILLUSTRATED ANATOMY:

**Thorax, Abdomen
& Pelvis**

OTHER TITLES IN THIS SERIES:

*Lippincott's Concise Illustrated Anatomy: Back, Upper
Limb & Lower Limb*

Lippincott's Concise Illustrated Anatomy: Head & Neck



Lippincott's
CONCISE ILLUSTRATED ANATOMY:

Thorax, Abdomen & Pelvis


VOLUME 2

Ben Pansky, PhD, MD

Professor Emeritus
Department of Surgery
University of Toledo College of Medicine
and Life Sciences
Toledo, Ohio

Thomas R. Gest, PhD

Professor of Anatomy
Division of Clinical Anatomy
Department of Radiology
University of South Florida Morsani College of Medicine
Tampa, Florida

 **Wolters Kluwer** | Lippincott Williams & Wilkins
Health

Philadelphia • Baltimore • New York • London
Buenos Aires • Hong Kong • Sydney • Tokyo

Acquisitions Editor: Crystal Taylor
Product Manager: Julie Montalbano
Marketing Manager: Joy Fisher Williams
Designer: Steve Druding
Compositor: SPi Global

Copyright © 2013 LIPPINCOTT WILLIAMS & WILKINS, a WOLTERS KLUWER business

351 West Camden Street
Baltimore, MD 21201

Two Commerce Square
2001 Market Street
Philadelphia, PA 19103

Printed in China

All rights reserved. This book is protected by copyright. No part of this book may be reproduced or transmitted in any form or by any means, including as photocopies or scanned-in or other electronic copies, or utilized by any information storage and retrieval system without written permission from the copyright owner, except for brief quotations embodied in critical articles and reviews. Materials appearing in this book prepared by individuals as part of their official duties as U.S. government employees are not covered by the above-mentioned copyright. To request permission, please contact Lippincott Williams & Wilkins at 2001 Market Street, Philadelphia, PA 19103, via email at permissions@lww.com, or via website at lww.com (products and services).

Library of Congress Cataloging-in-Publication Data

Pansky, Ben.

Lippincott's concise illustrated anatomy. Vol. 2, Thorax, abdomen & pelvis / Ben Pansky, Thomas R. Gest.
p. ; cm.

Concise illustrated anatomy

Thorax, abdomen & pelvis

ISBN 978-1-60913-028-2

I. Gest, Thomas R. II. Title. III. Title: Concise illustrated anatomy. IV. Title: Thorax, abdomen & pelvis.

[DNLM: 1. Thorax—anatomy & histology—Atlases. 2. Abdomen—anatomy & histology—Atlases.

3. Pelvis—anatomy & histology—Atlases. 4. Perineum—anatomy & histology—Atlases. WE 17]

612.9'4—dc23

2012009842

DISCLAIMER

Care has been taken to confirm the accuracy of the information present and to describe generally accepted practices. However, the authors, editors, and publisher are not responsible for errors or omissions or for any consequences from application of the information in this book and make no warranty, expressed or implied, with respect to the currency, completeness, or accuracy of the contents of the publication. Application of this information in a particular situation remains the professional responsibility of the practitioner; the clinical treatments described and recommended may not be considered absolute and universal recommendations.

The authors, editors, and publisher have exerted every effort to ensure that drug selection and dosage set forth in this text are in accordance with the current recommendations and practice at the time of publication. However, in view of ongoing research, changes in government regulations, and the constant flow of information relating to drug therapy and drug reactions, the reader is urged to check the package insert for each drug for any change in indications and dosage and for added warnings and precautions. This is particularly important when the recommended agent is a new or infrequently employed drug.

Some drugs and medical devices presented in this publication have Food and Drug Administration (FDA) clearance for limited use in restricted research settings. It is the responsibility of the health care provider to ascertain the FDA status of each drug or device planned for use in their clinical practice.

To purchase additional copies of this book, call our customer service department at (800) 638-3030 or fax orders to (301) 223-2320. International customers should call (301) 223-2300.

Visit Lippincott Williams & Wilkins on the Internet: <http://www.lww.com>. Lippincott Williams & Wilkins customer service representatives are available from 8:30 am to 6:00 pm, EST.

9 8 7 6 5 4 3 2 1

I dedicate this new endeavor to my dearly beloved wife **JULIE**, who will live in my loving memory forever, after our more than 50 years together, whose love, patience, understanding, encouragement and constant inspiration, supported me through the seasons of my maturation and productive life.

And to my loving son, **JONATHAN**, who grew up and matured along with me, my writings, illustrations, and stories. He is ever present by my side with love and encouragement helping me maintain the “Spark of Life and Creativity,” which has forever glowed brightly within me.

—**BEN PANSKY**

For my students, past, present, and future, who make teaching so enjoyable, and to all of the courageous body donors, past, present, and future, who teach me and my students so much more than gross anatomy through their amazingly brave and charitable gift.

—**TOM GEST**

Medical education continues to be in a constant state of change. Dedicated teachers experiment with teaching methods and curricula, always striving to refine, to define, to update, and to narrow the gap between the what, the how, and the why of what is being taught and the state of our present knowledge. Academic traditions are often quite rigid, cemented into place by a “yardstick of established time (hours),” so any effort to change becomes formidable and medical, clinical, and scientific relevance may receive secondary consideration. What the art of medicine always requires, no matter how much manipulating is done, is a strong foundation in the basic sciences. To fully appreciate and understand the complexities and nuances of variation in us all, Anatomy is the keystone in that foundation.

Lippincott’s Concise Illustrated Anatomy series presents human gross anatomy in more than a synopsis form and far less than one encounters in a massive traditional text. Each title in the series is a highly illustrated, complete, functionally oriented, clinically informative text, concerned with “living” anatomy and stressing the importance of the relationship between structure and function. Repetition only occurs as needed to emphasize particular points or to demonstrate continuity between regions.

Terminology adheres to the *Terminologia Anatomica* (1998) approved by the Federative Committee on Anatomical Nomenclature (FCAT) of the International Federation of Associations of Anatomists (IFAA). Official English-equivalent terms are used throughout this edition.

Anatomy requires one to think three-dimensionally, which is often a new concept for students and a difficult one for practitioners desiring to review. Studying and palpating a body at a dissection table may be the best way to comprehend the three-dimensional fundamentals of anatomy and the relationships of many of its parts. However, lacking the physical body, this text maintains a tradition utilized in six editions of *Review of Gross Anatomy* by Ben Pansky of being planned and written around its illustrations, which come predominantly from the highly acclaimed *Lippincott Williams & Wilkins Atlas of Anatomy* by Drs. Tank and Gest, together with a reworking of a number of illustrations from Dr. Pansky’s 6th edition of *Review of Gross Anatomy*, into beautiful, full-color illustrations closely coordinated with those of the *Atlas*.

The illustrations present anatomical images concisely in a logical sequence, making them easier and faster to use, a critical and essential need in this era of compressed anatomical curricula.

The hundreds of illustrations in full color combined with an abbreviated, outlined, but comprehensive and detailed text convey a simplified, multi-faceted, 3-dimensional aspect of the beauty and function of the human body not found in other texts.

Because the overall volume of material (in text and illustration) needed to present the true, complete reality of the human body is so massive, many texts have become larger and larger over the years. It was felt that a huge “tome” of 1,000 or more pages would be too overwhelming and formidable as well as difficult for students to tackle without great trepidation. Thus, we have decided to present 3 volumes for the 9 chapters or units of associated areas of the body—namely, Volume 1: Back, Upper Limb & Lower Limb; Volume 2: Thorax, Abdomen, & Pelvis; and Volume 3: Head & Neck. Each volume is approximately 300 pages. Thus, as one studies a respective body region, one needs to essentially carry, transport and study from a single volume at a time. Furthermore, if a student or practitioner is predominantly involved only in one or two major body areas, they may be able to concentrate on the essentials of her/his study or review (i.e., general practitioner, physical therapy, occupational therapy, nursing, orthopedics, dentistry, ophthalmology, surgery, etc.) without carrying around a large tome. They would still have the other volume(s) for reference since the body functions as a unit and one part depends on or is related to the other.

Progression from region to region, from the Back to the Upper and Lower Limbs, to the Thorax, Abdomen, and Pelvis, and to the Head and Neck, allows one to fully appreciate the continuity between the regions. The regional approach duplicates that used in many human

anatomy courses and laboratories of dissection as well as in surgical areas of concentration. However, the illustrations show some overlapping of structures to allow the student to move easily from one region to the next.

The body is discussed from its superficial layers to its deep structures, except for the osteology. Because the bones form the framework of the body and lend themselves to the attachment of soft parts, they tend to appear early in the text and are also to be studied early in most courses. This makes understanding of the relationships of the soft body parts more easily and clearly understood.

By extracting information from within the living organism, the student and practitioner are better able to describe and define both normal and abnormal states. Increasingly, sophisticated tools help them understand that continuum. At first, students of the medical arts used only observations and palpation, then they undertook dissection, and now “tools” have gained momentum, moving quickly from the stethoscopes and ophthalmoscopes to powerful X-rays and imaging technologies. To put this in perspective, X-rays were discovered at the close of the 19th century; nuclear medicine and ultrasonography were introduced in the 1950s; computed tomography (CT), positron emission tomography (PET), single-photon emission computed tomography (SPECT), digital radiography, and nuclear magnetic resonance (NMR) became available in the 1970s.

Thus, an anatomy text would be incomplete without some discussion and illustration of radiography, CT, NMR, PET, SPECT, and cross-sectional anatomy, which provide a good clinical introduction to the current state of the patient’s health. This has been included in our books since the sooner one learns to identify normal anatomy on X-ray film and computer imaging, the easier it becomes to locate and understand the changes brought on by genetics, disease, or trauma and thus, anatomy becomes a “keystone” to all of medicine and its many related fields.

Although much basic and essential clinical consideration has been presented in many areas of our texts, all clinically relevant material cannot be fully discussed for each anatomical region. However, its importance in one’s understanding of basic anatomy and how that can be altered is essential for truly appreciating what is generally “normal” before it becomes altered and creates clinical signs and symptoms.

The functional anatomy of the thorax, abdomen, and pelvis is presented in a concise manner, together with correlated clinical material, so that the student can appreciate the relevance of the anatomy to clinical practice. Special functional summaries, especially for autonomic innervation, should help the student to grasp this difficult material.

We, as educators in the Anatomical Sciences, are aware of the fact that gross anatomy is a subject quickly memorized and just as easily forgotten, unless the student or practitioner constantly reviews the material. Time can be an adversary and multiple duties are often overwhelming. It is our hope that in this series we have been concise, direct, and meaningful, without “running on and on” with excessive non-essentials, and that we have been able to create books that will guide the reader easily and thoughtfully through the very complex detail that makes up the human body and its many parts.

ACKNOWLEDGMENTS

Many thanks to those at Lippincott Williams and Wilkins who participated in the development of this textbook, including Acquisitions Editor Crystal Taylor, Product Manager Julie Montalbano, Art Director Jennifer Clements, and Designer Steve Druding. Additional thanks goes to Kelly Horvath for her editorial guidance and copyediting.

Marcelo Oliver and Body Scientific International did a superb job of converting many of Dr. Pansky's original black-and-white illustrations into full color, managing to duplicate the tone, color, and beauty of the illustrations from the *Lippincott Williams & Wilkins Atlas of Anatomy* by Drs. Tank and Gest.

Much gratitude is extended to Danelle Mooi, Secretary, Department of Surgery, and Nick Andrew Bell, Secretary, Departments of Nursing, Emergency Medicine and Staff Development, both at The University of Toledo Medical Center for their persistent encouragement, understanding, and great help to Dr. Pansky with their knowledge of the computer and digital world, which made his transgression into the realm of computers and wireless connections possible and a great learning experience.

Thanks goes to Summer Decker, PhD, Assistant Professor of Radiology, University of South Florida Morsani College of Medicine for her help in obtaining CT scans of the abdominopelvic cavity to match the cross sectional illustrations of this region.

And special thanks goes to Patrick Tank, PhD, Professor of Neurobiology and Developmental Sciences, University of Arkansas for Medical Sciences. His inspiration and hard work on the initial chapter of the initial volume of this series helped to get this project underway.

*Ben Pansky
Thomas Gest*

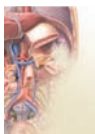Preface vii

Acknowledgments ix



Chapter 1: Thorax

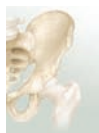1.1	Surface Anatomy of the Thoracic Wall	2
1.2	Thoracic Cage as a Whole	6
1.3	Articulations of the Thoracic Wall	11
1.4	Mammary Gland	14
1.5	Muscles and Neurovasculature of the Thoracic Wall	19
1.6	Movements of the Chest Wall in Respiration	24
1.7	Subdivisions of the Thoracic Cavity	26
1.8	Anterior Mediastinum and the Thymus Gland	28
1.9	Middle Mediastinum: Pericardial Sac and Heart	30
1.10	Heart and its Blood Supply	34
1.11	Interior of the Heart	40
1.12	Valves of the Heart	44
1.13	Conduction System of the Heart	47
1.14	Conduction System of the Heart and Electrocardiograms	50
1.15	Extrinsic Innervation of the Heart and the Cardiac Plexuses	53
1.16	Pleurae and the Surface Projections of Lungs and Pleura	58
1.17	Lungs	62
1.18	Trachea and the Bronchial Tree	68
1.19	Neurovasculature of the Lungs	73
1.20	Superior Mediastinum	76
1.21	Posterior Mediastinum	80
1.22	Thoracic Sympathetic Trunk	84
1.23	Esophagus	86
1.24	Thoracic Lymphatics	88



Chapter 2: Abdomen

2.1	Surface Anatomy of the Abdominal Wall	92
2.2	Superficial Veins, Cutaneous Nerves, and Superficial Fascia of the Abdominal Wall	95

2.3	Muscles of the Abdominal Wall	98
2.4	Abdominal Aponeuroses, Rectus Sheath, and Neurovasculature of the Abdominal Wall	101
2.5	Inguinal Canal, Spermatic Cord, and Hernia	107
2.6	Peritoneum	114
2.7	Small Intestine: Parts and Relations	120
2.8	Large Intestine: Parts and Relations	124
2.9	Small and Large Intestine: Blood Supply, Lymph Drainage, and Innervation	128
2.10	Stomach: Parts and Relations	132
2.11	Stomach: Blood Supply, Lymph Drainage, and Innervation	136
2.12	Spleen: Parts and Relations	140
2.13	Duodenum: Parts and Relations	143
2.14	Pancreas: Parts and Relations	146
2.15	Duodenum, Pancreas, and Spleen: Blood Supply, Lymph Drainage, and Innervation	149
2.16	Liver: Parts and Relations	152
2.17	Liver Lobules, Blood Supply, Innervation, and Portal Circulation	156
2.18	Gallbladder and Ducts	160
2.19	Kidney: Parts and Relations	163
2.20	Kidney: Blood Supply, Lymph Drainage, and Innervation	168
2.21	Ureters	171
2.22	Suprarenal Gland	175
2.23	Lymphatics of the Abdomen	178
2.24	Respiratory Diaphragm	182
2.25	Vessels of the Posterior Abdominal Wall	185
2.26	Nerves of the Posterior Abdominal Wall	188
2.27	Cross-sectional Anatomy of the Abdomen	194



Chapter 3: Pelvis & Perineum

3.1	Surface Anatomy of the Pelvis and Perineum	200
3.2	Bony Pelvis	206
3.3	Pelvic Viscera and Pelvic Peritoneum	212
3.4	Urinary Bladder and Urethra	216
3.5	Ductus Deferens, Seminal Vesicles, and Prostate	221
3.6	Urinary Bladder and Prostate: Blood Supply and Innervation	224
3.7	Ovary, Uterine Tubes, and Uterus: Parts and Relations	228
3.8	Vagina and Support Mechanisms of the Uterus	233
3.9	Female Genital System: Blood Supply and Innervation	236
3.10	Rectum and Anal Canal: Parts and Relations	238
3.11	Rectum and Anal Canal: Blood Supply and Innervation	242
3.12	Pelvic Wall and Pelvic Diaphragm Muscles	245

3.13	Perineum	248
3.14	Clitoris, Penis, and Testis	256
3.15	Arteries and Veins of the Pelvis and Perineum	261
3.16	Lymphatics of the Pelvis and Perineum	266
3.17	Somatic Nerves of the Pelvis and Perineum	268
3.18	Autonomic Nerves of the Pelvis and Perineum	274
3.19	Micturition	278
3.20	Defecation	282
3.21	Mechanisms of Human Sexual Response	285
3.22	Cross-sectional Anatomy of the Pelvis	288