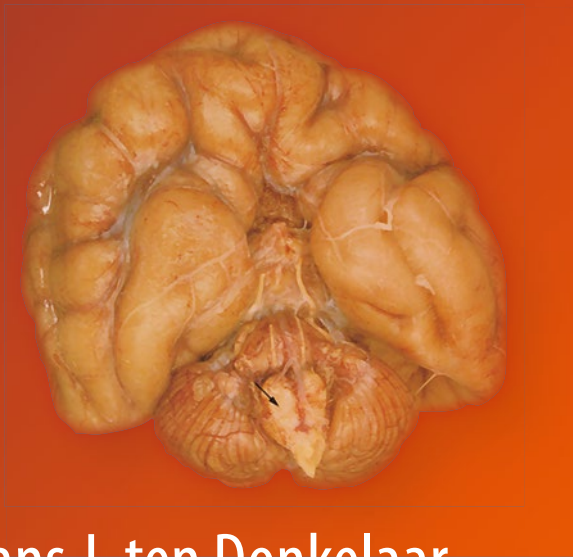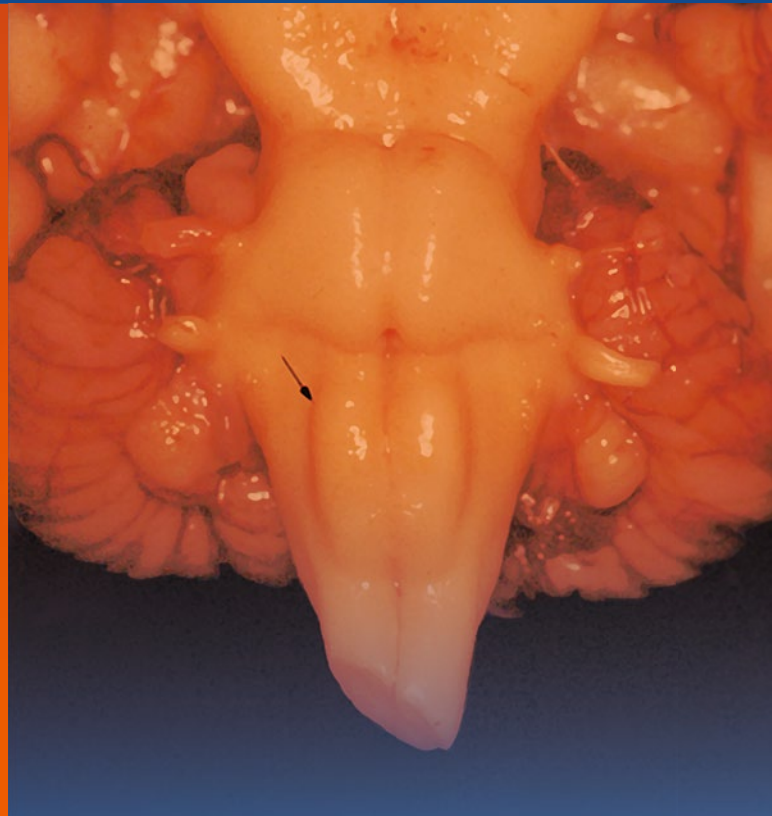




Hans J. ten Donkelaar  
Martin Lammens  
Akira Hori



# Clinical Neuroembryology

Development and Developmental Disorders  
of the Human Central Nervous System

*Second Edition*

 Springer

---

# Clinical Neuroembryology



---

Hans J. ten Donkelaar • Martin Lammens  
Akira Hori

# Clinical Neuroembryology

Development and Developmental Disorders  
of the Human Central Nervous System

Second Edition

*In co-operation with:*

Eleonora Aronica  
Mireille Bekker  
Johannes R.M. Cruysberg  
Kyoko Itoh  
Karin Kamphuis-van Ulzen  
Irene M.J. Mathijssen  
Ronald Pennings  
Willy O. Renier  
Kohei Shiota

Hans van Bokhoven  
Ton van der Vliet  
Patrick van der Voorn  
John M.G. van Vugt  
Christl Vermeij-Keers  
Pieter Wesseling  
Michèl Willemsen  
Shigehito Yamada

 Springer

Hans J. ten Donkelaar, M.D., Ph.D.  
935 Department of Neurology  
Radboud University Nijmegen Medical Centre  
Nijmegen, The Netherlands

Martin Lammens, M.D., Ph.D.  
Department of Pathology  
University Hospital Antwerpen  
Edegem, Belgium

Akira Hori, M.D., Ph.D.  
Institute of Pathology  
Medizinische Hochschule Hannover  
Hannover, Germany

Research Institute for Longevity Medicine  
Fukushima Hospital  
Toyohashi, Japan

ISBN 978-3-642-54686-0      ISBN 978-3-642-54687-7 (eBook)  
DOI 10.1007/978-3-642-54687-7  
Springer Heidelberg New York Dordrecht London

Library of Congress Control Number: 2014940543

© Springer-Verlag Berlin Heidelberg 2006, 2014

This work is subject to copyright. All rights are reserved by the Publisher, whether the whole or part of the material is concerned, specifically the rights of translation, reprinting, reuse of illustrations, recitation, broadcasting, reproduction on microfilms or in any other physical way, and transmission or information storage and retrieval, electronic adaptation, computer software, or by similar or dissimilar methodology now known or hereafter developed. Exempted from this legal reservation are brief excerpts in connection with reviews or scholarly analysis or material supplied specifically for the purpose of being entered and executed on a computer system, for exclusive use by the purchaser of the work. Duplication of this publication or parts thereof is permitted only under the provisions of the Copyright Law of the Publisher's location, in its current version, and permission for use must always be obtained from Springer. Permissions for use may be obtained through RightsLink at the Copyright Clearance Center. Violations are liable to prosecution under the respective Copyright Law.

The use of general descriptive names, registered names, trademarks, service marks, etc. in this publication does not imply, even in the absence of a specific statement, that such names are exempt from the relevant protective laws and regulations and therefore free for general use.

While the advice and information in this book are believed to be true and accurate at the date of publication, neither the authors nor the editors nor the publisher can accept any legal responsibility for any errors or omissions that may be made. The publisher makes no warranty, express or implied, with respect to the material contained herein.

Printed on acid-free paper

Springer is part of Springer Science+Business Media ([www.springer.com](http://www.springer.com))

---

## Preface to the Second Edition

Apart from a general updating of the extensive literature on developmental neurobiology, neurogenetics, imaging and developmental neuropathology between 2005 and 2013, more emphasis has been given to: (a) imaging of the embryonic brain (early prenatal diagnosis by ultrasound); (b) imaging of the fetal brain by MRI; (c) DTI studies on the development of major fibre connections such as the pyramidal tract and the corpus callosum; and (d) the impact of newer genetic techniques such as whole exome/genome sequencing. Moreover, new classifications of brain disorders have been implemented such as a new classification of midbrain-hindbrain developmental disorders and entire new families of disorders such as ciliopathies and dystroglycanopathies. Throughout the book, several new Clinical Cases have been added.

Several colleagues kindly contributed as new co-authors their expertise to this second edition, including Eleonora Aronica (Amsterdam), Mireille Bekker (Nijmegen), Kyoko Itoh (Kyoto), Karin Kamphuis-van Ulzen (Nijmegen), Irene Mathijssen (Rotterdam), Ronald Pennings and Hans van Bokhoven (Nijmegen), Patrick van der Voorn (Amsterdam) and Shigehito Yamada (Kyoto). They also contributed new Clinical Cases. For other new Clinical Cases, the help of Remke Dullemond (Rotterdam), Janet Eyre (Newcastle), Floris Groenendaal (Utrecht), Gregor Kasprian (Vienna), Hajime Miyata (Akita), Peter Nikkels (Utrecht), Tetsu Niwa (Yokohama), Andrea Poretti (Zurich), Ritsuko Pooh (Osaka), Goran Simić (Zagreb) and Marjolein Willemsen (Nijmegen) is gratefully acknowledged. New illustrations were also kindly provided by Marco Catani and Michel Thiebaut de Schotten (London), Cyrille Ferrier (Utrecht), Hao Huang (Dallas), Ole Kiehn (Stockholm), Grace Lai (New York), Anna Lavezzi (Milan) and Maria Thom (London). A long weekend with Luis Puelles in Murcia greatly helped the first author to implement new findings on the prosomeric model of the developing brain.

**Hans J. ten Donkelaar**, Nijmegen  
**Martin Lammens**, Edegem  
**Akira Hori**, Toyohashi



---

## Preface to the First Edition

The spectacular progress in developmental neurobiology, the tremendous advances in (neuro) genetics and the high resolution of the modern imaging techniques applicable to developmental disorders of the human brain and spinal cord have created a growing interest in the developmental history of the central nervous system (CNS). This new book provides a comprehensive overview of the development of the human CNS in the context of its many developmental disorders due to genetic, environmental and hypoxic/ischemic causes. The book contains three general, introductory chapters in which an overview of the development of the human brain and spinal cord, a summary of mechanisms of development as obtained in experimental studies in various invertebrates and vertebrates, and an overview of the causes of congenital malformations with some notes on prenatal diagnosis, are presented. The developmental disorders of the human brain and spinal cord are presented in a regional, more or less segmental way, starting with neurulation and the neural tube defects, and ending with developmental disorders of the cerebral cortex. These chapters are abundantly illustrated with clinical case studies with imaging data and, when available, postmortem verification of the developmental disorders involved. The book is intended for advanced medical students, and all those clinicians working with children and adults with developmental disorders of the CNS.

This book would not have been possible without the help of many colleagues in The Netherlands and from abroad. Their help is gratefully acknowledged. Most of the neuropathological material comes from the extensive collections of Drs. Akira Hori and Martin Lammens. Many cases were kindly provided by Drs. Pieter Wesseling (Nijmegen), Gerard van Noort (Enschede), and Kohei Shiota (Kyoto). Photographical assistance was provided by Mrs. Roelie de Boer-van Huizen (Nijmegen), Mrs. Chigako Uwabe (Kyoto) and Richard Rieksen (Enschede). Material for the clinical case studies was provided by many clinical colleagues, including Drs. Ellsworth C. Alvord Jr (Seattle), Harm-Gerd Blaas (Trondheim), Cor Cremers and Hans Cruysberg (Nijmegen), Mark D'hooghe (Bruges), Jennian Geddes (London), Ben Hamel (Nijmegen), Frans Hoevenaars (Nijmegen), Nomdo Jansonius (Groningen), Akiyoshi Kakita (Niigata), Max Kros (Rotterdam), Hajime Miyata (Tottori), Masashi Mizuguchi (Tokyo), Reinier Mullaart, Willy Renier and Jan Rotteveel (Nijmegen), Harvey B. Sarnat (Calgary), Ben Semmekrot (Nijmegen), Waney Squier (Oxford), Sachio Takashima (Fukuoka), Rudy van Coster and Caroline Van den Broecke (Gent), Christl Vermeij-Keers (Rotterdam), Michel Willemsen (Nijmegen), and Mieko Yoshioka (Kobe). Imaging data were kindly provided by Drs. Harm-Gerd Blaas (Trondheim), Berit Verbist (Leiden), John van Vugt and collaborators (Amsterdam), Henk Thijssen and Ton van der Vliet (Nijmegen), and Guido Wilms (Leuven). Several figures were contributed by Drs. Jo Curfs (Nijmegen), Marieke de Heer and Jeannette Hoogeboom (Rotterdam), Raoul Hennekam (Amsterdam), Jan E. Jirasek (Prague), Enrico Marani (Leiden), Loreta Medina (Murcia), Zoltán Molnár (Oxford), Ronan O'Rahilly (Villars-sur-Glâne), Annemieke Potters (Deventer), Kohei Shiota (Kyoto), Henny van Straaten (Maastricht), Michiel Vaandrager (Rotterdam), Jan Voogd (Oegstgeest), and Shigehito Yamada (Kyoto). Most of the drawings were made by Mrs. Marlu de Leeuw and Mr. Ad Gruter. Financial support was generously provided by the "Stichting Neurologie en Wetenschap" of the Department of Neurology (Head: Prof. Dr. George W.A.M. Padberg) and the Department of Pathology (Head: Prof. Dr. Han van Krieken), both of the Radboud University Nijmegen



Medical Centre, supporting the costs of the drawings. The Japan Society for the Promotion of Science granted the first author a short-term fellowship in May 2004 at the Congenital Anomaly Research Centre (Head: Prof. Dr. Kohei Shiota) of Kyoto University.

**Hans J. ten Donkelaar**, Nijmegen

**Martin Lammens**, Nijmegen

**Akira Hori**, Toyohashi

---

# Contents

<b>1 Overview of the Development of the Human Brain and Spinal Cord</b> . . . . .	1
Hans J. ten Donkelaar, Shigehito Yamada, Kohei Shiota, and Ton van der Vliet	
<b>1.1 Introduction</b> . . . . .	1
<b>1.2 Major Stages in the Development of the Human Brain and Spinal Cord</b> . . . . .	2
<b>1.3 The First 3 Weeks of Development</b> . . . . .	8
1.3.1 Implantation . . . . .	8
1.3.2 Gastrulation . . . . .	9
1.3.3 Folding of the Embryo . . . . .	10
<b>1.4 Neurulation</b> . . . . .	12
<b>1.5 Development of the Spinal Cord</b> . . . . .	14
<b>1.6 Pattern Formation of the Brain</b> . . . . .	15
<b>1.7 Early Development of the Brain</b> . . . . .	17
1.7.1 Imaging of the Embryonic Brain . . . . .	18
1.7.2 Neuromeres . . . . .	19
1.7.3 The Ganglionic Eminences . . . . .	21
<b>1.8 Fetal Development of the Brain</b> . . . . .	22
1.8.1 The Cerebellum . . . . .	22
1.8.2 The Cerebral Cortex . . . . .	25
1.8.3 Cerebral Commissures . . . . .	32
1.8.4 Imaging of the Fetal Brain . . . . .	32
<b>1.9 Development of the Meninges and Choroid Plexuses</b> . . . . .	33
<b>1.10 Development of the Blood Supply of the Brain</b> . . . . .	34
<b>1.11 Development of Fibre Tracts (Including Development of Myelination)</b> . . . . .	39
<b>References</b> . . . . .	46
<b>2 Mechanisms of Development</b> . . . . .	53
Hans J. ten Donkelaar	
<b>2.1 Introduction</b> . . . . .	53
<b>2.2 Neural Induction</b> . . . . .	54
2.2.1 The Spemann-Mangold Organizer . . . . .	54
2.2.2 The Molecular Basis of Neural Induction . . . . .	55
2.2.3 Polarity and the Establishment of the Neuraxis . . . . .	56
2.2.4 Neural Induction in Amniote Embryos . . . . .	57
2.2.5 Specific Pathways for Head Induction . . . . .	57
<b>2.3 Cell Lineage Studies and Fate Mapping</b> . . . . .	59
<b>2.4 Pattern Formation</b> . . . . .	60
2.4.1 Regionalization of the Forebrain . . . . .	65
2.4.2 The Zona Limitans Intrathalamica . . . . .	66
2.4.3 The Midbrain-Hindbrain Boundary Organizer . . . . .	66
2.4.4 Segmentation of the Hindbrain . . . . .	67

<b>2.5 Neurogenesis, Gliogenesis and Migration</b> . . . . .	69
2.5.1 Neurogenesis: Primary and Secondary Proliferative Compartments . . . . .	69
2.5.2 Gliogenesis . . . . .	72
2.5.3 Migration . . . . .	75
<b>2.6 Axon Outgrowth and Guidance</b> . . . . .	77
2.6.1 Pioneer Fibres . . . . .	77
2.6.2 The Guidance of Axons to Their Targets . . . . .	78
2.6.3 Axon Guidance at Choice Points . . . . .	81
2.6.4 Commissure Formation . . . . .	82
2.6.5 Formation of Thalamocortical and Corticofugal Projections . . . . .	83
2.6.6 Formation of Topographic Maps . . . . .	86
<b>2.7 Programmed Cell Death</b> . . . . .	89
<b>References</b> . . . . .	91
<b>3 Causes of Congenital Malformations</b> . . . . .	105
Martin Lammens, John M.G. van Vugt, Michèl Willemsen, Patrick van der Voorn, Hans van Bokhoven, and Hans J. ten Donkelaar	
<b>3.1 Introduction</b> . . . . .	105
<b>3.2 Causes of Congenital Malformations</b> . . . . .	106
3.2.1 Genetic Disorders . . . . .	106
Clinical Case 3.1. Meckel-Gruber Syndrome . . . . .	113
3.2.2 Environmental Causes . . . . .	114
Clinical Case 3.2. Cytomegalovirus Encephalopathy . . . . .	118
Clinical Case 3.3. Amnion Rupture Sequence . . . . .	119
<b>3.3 Prenatal Diagnosis</b> . . . . .	120
3.3.1 Ultrasound and Magnetic Resonance Examination . . . . .	121
3.3.2 Invasive Tests . . . . .	126
Clinical Case 3.4. Traumatic Amniocentesis . . . . .	128
3.3.3 Genetic Diagnosis . . . . .	129
<b>3.4 Inborn Errors of Metabolism Affecting the CNS</b> . . . . .	130
3.4.1 Inborn Errors of Metabolism That Mainly Affect the CNS . . . . .	131
3.4.2 Multisystem Disorders with CNS Involvement . . . . .	132
Clinical Case 3.5. Congenital Disorders of Glycosylation . . . . .	135
Clinical Case 3.6. Walker-Warburg Syndrome . . . . .	136
Clinical Case 3.7. Zellweger Syndrome . . . . .	137
<b>3.5 Myelination Disorders</b> . . . . .	139
Clinical Case 3.8. Histopathological Correlates of Radial Stripes on MR Images in Lysosomal Storage Disorders . . . . .	140
Clinical Case 3.9. X-Linked Adrenoleukodystrophy . . . . .	143
Clinical Case 3.10. Vanishing White Matter Disease . . . . .	144
<b>3.6 Vascular Disorders</b> . . . . .	145
Clinical Case 3.11. Porencephaly . . . . .	148
Clinical Case 3.12. Twin-to-Twin Transfusion . . . . .	149
Clinical Case 3.13. Punctate White Matter Lesions . . . . .	150
Clinical Case 3.14. Multicystic Leukoencephalopathy . . . . .	152
Clinical Case 3.15. Neonatal Alloimmune Thrombocytopenia . . . . .	153
Clinical Case 3.16. Vein of Galen Aneurysm . . . . .	154
<b>3.7 Congenital Tumours</b> . . . . .	155
Clinical Case 3.17. Congenital Tumours: TSC . . . . .	155
<b>3.8 Classifications of CNS Malformations</b> . . . . .	157
<b>References</b> . . . . .	158

<b>4</b>	<b>Neurulation and Neural Tube Defects</b> . . . . .	165
	Hans J. ten Donkelaar, Mireille Bekker, Willy O. Renier, Akira Hori, and Kohei Shiota	
<b>4.1</b>	<b>Introduction</b> . . . . .	165
<b>4.2</b>	<b>Primary Neurulation</b> . . . . .	166
4.2.1	Primary Neurulation in Chick and Mammalian Embryos. . . . .	166
4.2.2	Primary Neurulation in Human Embryos . . . . .	170
<b>4.3</b>	<b>Secondary Neurulation</b> . . . . .	173
<b>4.4</b>	<b>Genetic Mouse Models for Neural Tube Defects</b> . . . . .	175
<b>4.5</b>	<b>Aetiology of Human Neural Tube Defects</b> . . . . .	176
4.5.1	Genetic Basis: Neural Tube Defects as a Multifactorial Trait. . . . .	177
4.5.2	Environmental Factors . . . . .	178
<b>4.6</b>	<b>Prenatal Diagnosis and Fetal Therapy</b> . . . . .	178
Clinical Case 4.1.	Prenatal Diagnosis of NTDs . . . . .	179
<b>4.7</b>	<b>Cranial Neural Tube Defects</b> . . . . .	180
4.7.1	Anencephaly . . . . .	181
Clinical Case 4.2.	Ependyoblastomatous Exencephaly . . . . .	185
4.7.2	Encephaloceles and Cranial Meningocele. . . . .	187
Clinical Case 4.3.	Occipital Encephalocele . . . . .	190
Clinical Case 4.4.	Tectocerebellar Dysraphia . . . . .	191
Clinical Case 4.5.	Cranial Meningocele . . . . .	192
Clinical Case 4.6.	Rudimentary Occipital Meningocele. . . . .	194
<b>4.8</b>	<b>Spinal Neural Tube Defects</b> . . . . .	196
4.8.1	Myeloceles, Myelomeningocele and Spinal Meningocele . . . . .	197
Clinical Case 4.7.	The Spectrum of Deranged Neurulation . . . . .	198
4.8.2	Spinal Lipomas . . . . .	200
Clinical Case 4.8.	Spinal Lipomas . . . . .	201
4.8.3	Spina Bifida Occulta and Related Disorders. . . . .	203
4.8.4	The Tethered Spinal Cord Syndrome . . . . .	203
Clinical Case 4.9.	Tethered Spinal Cord Syndrome . . . . .	204
<b>4.9</b>	<b>The Chiari Malformations</b> . . . . .	205
<b>4.10</b>	<b>Caudal Dysgenesis</b> . . . . .	207
Clinical Case 4.10.	OEIS Complex. . . . .	210
	<b>References</b> . . . . .	211
<b>5</b>	<b>The Neural Crest and Craniofacial Malformations</b> . . . . .	219
	Hans J. ten Donkelaar, Christl Vermeij-Keers, and Irene M.J. Mathijssen	
<b>5.1</b>	<b>Introduction</b> . . . . .	219
<b>5.2</b>	<b>Induction and Epitheliomesenchymal Transformation (EMT) of the Neural Crest</b> . . . . .	220
<b>5.3</b>	<b>Derivatives of the Neural Crest</b> . . . . .	222
5.3.1	The Cranial Neural Crest . . . . .	223
5.3.2	The Trunk Neural Crest. . . . .	225
Clinical Case 5.1.	Congenital Aganglionosis . . . . .	227
<b>5.4</b>	<b>Craniofacial Development</b> . . . . .	228
5.4.1	Early Development of the Face. . . . .	228
5.4.2	Development of the Pharyngeal Arches . . . . .	230
5.4.3	Further Development of the Face . . . . .	231
5.4.4	Development of the Skull . . . . .	236

<b>5.5 Neurocristopathies</b> . . . . .	238
5.5.1 Retinoic Acid Syndrome . . . . .	239
5.5.2 Oculoauriculo-Vertebral Spectrum . . . . .	239
5.5.3 Treacher Collins Syndrome . . . . .	240
5.5.4 DiGeorge Sequence and Related Disorders . . . . .	241
5.5.5 Waardenburg Syndrome . . . . .	243
<b>5.6 Cranial Ciliopathies</b> . . . . .	243
<b>5.7 Holoprosencephaly</b> . . . . .	244
Clinical Case 5.2. Alobar Holoprosencephaly . . . . .	248
<b>5.8 Abnormal Development of the Skull with CNS Manifestations.</b> . . . . .	249
5.8.1 The Craniosynostoses . . . . .	249
Clinical Case 5.3. Prenatal Diagnosis of Apert Syndrome . . . . .	254
Clinical Case 5.4. Apert Syndrome . . . . .	255
Clinical Case 5.5. Thanatophoric Dysplasia . . . . .	256
5.8.2 Cranial Base Abnormalities . . . . .	258
<b>References</b> . . . . .	258
<b>6 Development and Developmental Disorders of the Spinal Cord</b> . . . . .	271
Hans J. ten Donkelaar, Kyoko Itoh, and Akira Hori	
<b>6.1 Introduction</b> . . . . .	271
<b>6.2 Gross Development of the Spinal Cord</b> . . . . .	272
6.2.1 A Few Notes on the Development of the Vertebral Column . . . . .	273
6.2.2 Ascensus Medullae . . . . .	274
<b>6.3 Developmental Events in Spinal Neuronal Populations</b> . . . . .	275
<b>6.4 The Specification of Cell Fates in the Spinal Cord</b> . . . . .	276
6.4.1 Specification of Neuronal Fates in the Ventral Spinal Cord . . . . .	277
Clinical Case 6.1. Spinal Muscular Atrophy . . . . .	280
Clinical Case 6.2. Hypoplasia of the Spinal Cord in a Case of Lethal Congenital Contracture Syndrome . . . . .	281
6.4.2 Patterning Cell Types in the Dorsal Spinal Cord . . . . .	282
<b>6.5 Development of Dorsal Root Projections</b> . . . . .	283
<b>6.6 Development of Spinal Ascending Projections</b> . . . . .	286
<b>6.7 Development of Descending Projections to the Spinal Cord</b> . . . . .	288
6.7.1 Descending Projections from the Brain Stem . . . . .	289
6.7.2 Development of the Pyramidal Tract in Rodents . . . . .	291
6.7.3 Development of the Pyramidal Tract in Macaque Monkeys . . . . .	293
6.7.4 Development of the Human Pyramidal Tract . . . . .	294
Clinical Case 6.3. Corticospinal System Reorganization . . . . .	297
Clinical Case 6.4. <i>LICAM</i> Mutation . . . . .	299
<b>6.8 Developmental Anomalies of the Spinal Cord</b> . . . . .	299
6.8.1 Anomalies of Histogenesis . . . . .	299
6.8.2 Duplications of the Spinal Cord . . . . .	300
Clinical Case 6.5. Diplomyelia . . . . .	301
6.8.3 Neurenteric Cysts . . . . .	302
Clinical Case 6.6. A Spinal Intradural Enterogenous Cyst . . . . .	303
6.8.4 Syringomyelia . . . . .	306
6.8.5 Abnormal Course or Absence of Fibre Tracts . . . . .	307
Clinical Case 6.7. Absence of the Pyramidal Tracts . . . . .	309
Clinical Case 6.8. Anomaly of Decussation of the Pyramidal Tract in Trisomy 18 . . . . .	312
<b>References</b> . . . . .	313

<b>7</b>	<b>Development and Developmental Disorders of the Brain Stem</b> . . . . .	321
	Hans J. ten Donkelaar, Johannes R.M. Cruysberg, Ronald Pennings, and Martin Lammens	
<b>7.1</b>	<b>Introduction</b> . . . . .	321
<b>7.2</b>	<b>Pattern Formation and Segmentation of the Brain Stem</b> . . . . .	323
7.2.1	Pattern Formation of the Brain Stem. . . . .	323
	Clinical Case 7.1. Agenesis of the Mesencephalon and Metencephalon with Cerebellar Hypoplasia . . . . .	326
7.2.2	Segmentation of the Brain Stem . . . . .	327
<b>7.3</b>	<b>Development and Developmental Disorders of the Cranial Nerves</b> . . . . .	329
7.3.1	Development of the Cranial Nerves and Their Nuclei in Rodents . . . . .	329
7.3.2	Development of Cranial Nerve Ganglia in Rodents . . . . .	331
7.3.3	Developmental and Developmental Disorders of the Human Cranial Nerves . . . . .	331
7.3.4	Congenital Cranial Dysinnervation Disorders . . . . .	332
	Clinical Case 7.2. Congenital Cranial Dysinnervation Disorders. . . . .	339
	Clinical Case 7.3. Congenital Facial Palsy . . . . .	340
	Clinical Case 7.4. Möbius Syndrome . . . . .	341
7.3.5	The Sudden Infant Death Syndrome. . . . .	343
<b>7.4</b>	<b>Development of the Auditory System</b> . . . . .	343
7.4.1	Development of the Ear. . . . .	344
7.4.2	Development of the Auditory Projections. . . . .	349
7.4.3	Developmental Disorders of the Auditory System . . . . .	350
	Clinical Case 7.5. Pendred Syndrome. . . . .	352
7.4.4	Mutated Genes Involved in Deafness . . . . .	353
	Clinical Case 7.6. Branchio-oto-renal Syndrome . . . . .	359
	Clinical Case 7.7. Usher Syndrome . . . . .	361
	<b>References</b> . . . . .	362
<b>8</b>	<b>Development and Developmental Disorders of the Human Cerebellum</b> . . . . .	371
	Hans J. ten Donkelaar, Martin Lammens, Pieter Wesseling, and Akira Hori	
<b>8.1</b>	<b>Introduction</b> . . . . .	371
<b>8.2</b>	<b>Some Notes on the Anatomy of the Cerebellum</b> . . . . .	372
8.2.1	Subdivision . . . . .	372
8.2.2	Compartmentalization. . . . .	373
8.2.3	Major Fibre Connections. . . . .	373
8.2.4	Precerebellar Nuclei . . . . .	374
<b>8.3</b>	<b>Morphogenesis of the Cerebellum</b> . . . . .	375
<b>8.4</b>	<b>Four Basic Steps in the Histogenesis of the Cerebellum</b> . . . . .	375
8.4.1	Characterization of the Cerebellar Territory . . . . .	376
	Clinical Case 8.1. Cerebellar Agenesis . . . . .	381
	Clinical Case 8.2. Rhombencephalosynapsis . . . . .	382
8.4.2	Formation of Two Proliferative Compartments. . . . .	384
8.4.3	Inward Migration of Granule Cells. . . . .	385
	Clinical Case 8.3. Medulloblastoma . . . . .	388
8.4.4	Differentiation of Cerebellar Neurons. . . . .	390
	Clinical Case 8.4. Cerebello-Cortical Heterotopia in the Dentate Nucleus . . . . .	392
<b>8.5</b>	<b>Development of the Precerebellar Nuclei</b> . . . . .	393
8.5.1	Upper Precerebellar System . . . . .	394
8.5.2	Lower Precerebellar System . . . . .	394
8.5.3	Inferior Olivary Malformations. . . . .	395

<b>8.6</b>	<b>Mouse Mutants with Cerebellar Malformation</b> . . . . .	396
<b>8.7</b>	<b>Developmental Disorders of the Cerebellum</b> . . . . .	397
8.7.1	Midline or Vermis Malformations . . . . .	399
	Clinical Case 8.5. Dandy-Walker Malformation . . . . .	403
	Clinical Case 8.6. Prenatal Diagnosis of DWM . . . . .	405
	Clinical Case 8.7. Joubert Syndrome . . . . .	406
8.7.2	Cerebellar Hypoplasia . . . . .	408
8.7.3	Pontocerebellar Hypoplasias . . . . .	409
	Clinical Case 8.8. Pontocerebellar Hypoplasia . . . . .	410
8.7.4	Cortical Dysplasias . . . . .	411
	Clinical Case 8.9. Dysplastic Cerebellum with Extreme Hydrocephalus . . . . .	411
	<b>References</b> . . . . .	412
<b>9</b>	<b>Development and Developmental Disorders of the Forebrain</b> . . . . .	421
	Hans J. ten Donkelaar, Martin Lammens, Johannes R.M. Cruysberg, Karin Kamphuis-van Ulzen, Akira Hori, and Kohei Shiota	
<b>9.1</b>	<b>Introduction</b> . . . . .	422
<b>9.2</b>	<b>Prosomeres and Pattern Formation of the Forebrain</b> . . . . .	423
<b>9.3</b>	<b>Development of the Diencephalon</b> . . . . .	426
9.3.1	Development of the Thalamus . . . . .	427
9.3.2	Development of the Hypothalamus . . . . .	433
9.3.3	Development of the Pituitary Gland . . . . .	434
9.3.4	Developmental Disorders of the Hypothalamus and the Pituitary Gland . . . . .	436
	Clinical Case 9.1 Duplication of the Pituitary Gland . . . . .	438
	Clinical Case 9.2 Pharyngosellar Pituitary . . . . .	439
	Clinical Case 9.3 Pallister-Hall Syndrome . . . . .	440
<b>9.4</b>	<b>Development of the Visual System</b> . . . . .	442
9.4.1	Development of the Eye . . . . .	442
9.4.2	Congenital Malformations of the Eye . . . . .	445
	Clinical Case 9.4 Aniridia . . . . .	449
	Clinical Case 9.5 Retinitis Pigmentosa with CNS Malformations . . . . .	450
9.4.3	Development of the Visual Projections . . . . .	450
	Clinical Case 9.6 Isolated Absence of the Optic Chiasm . . . . .	453
<b>9.5</b>	<b>Overview of the Development of the Telencephalon</b> . . . . .	453
<b>9.6</b>	<b>Development of the Rhinencephalon</b> . . . . .	461
	Clinical Case 9.7 A Remnant Olfactory Ventricle . . . . .	466
<b>9.7</b>	<b>The Prosencephalies</b> . . . . .	467
9.7.1	Aprosencephaly . . . . .	467
	Clinical Case 9.8 Aprosencephaly . . . . .	467
9.7.2	Holoprosencephaly . . . . .	470
	Clinical Case 9.9 Prenatal Diagnosis of Holoprosencephaly . . . . .	476
	Clinical Case 9.10 Holoprosencephaly with Hypertrophic Olfactory Nerves . . . . .	478
	Clinical Case 9.11 Semilobar Holoprosencephaly with a Unique Traversed Coronal Sulcus . . . . .	479
	Clinical Case 9.12 Middle Interhemispheric Variant of Holoprosencephaly . . . . .	480
9.7.3	Septo-optic Dysplasia . . . . .	482
	Clinical Case 9.13 Septo-optic Dysplasia . . . . .	483
9.7.4	Isolated Arhinencephaly . . . . .	483