Mei Zhang *Editor*

Atlas of Human Body Ultrasound Scanning

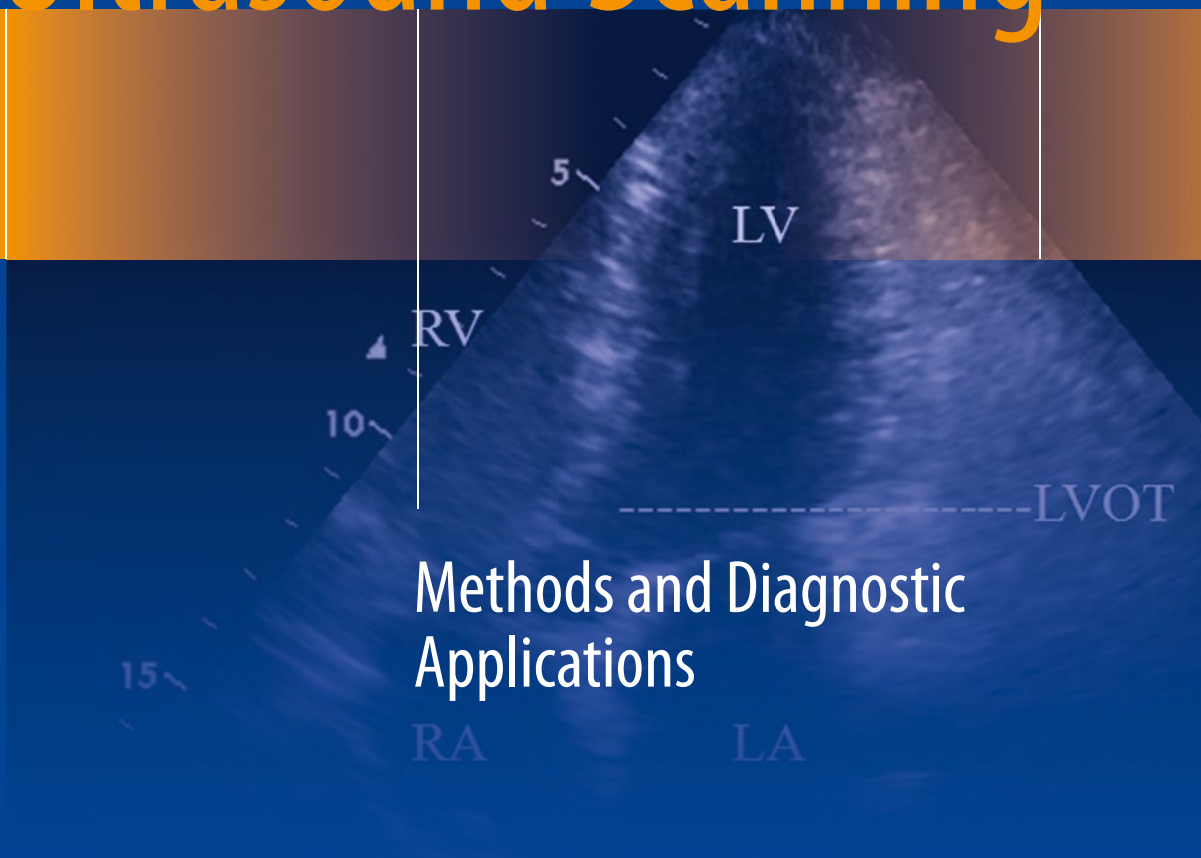

Methods and Diagnostic Applications

Springer

Atlas of Human Body Ultrasound Scanning

Mei Zhang
Editor

Atlas of Human Body Ultrasound Scanning

Methods and Diagnostic Applications

Springer

Editor
Mei Zhang
Department of Ultrasound
Beijing Royal Integrative Medical Hospital
Beijing
China

Jointly published with People's Military Medical Press, Beijing, China
ISBN 978-981-10-5833-2 ISBN 978-981-10-5834-9 (eBook)
https://doi.org/10.1007/978-981-10-5834-9

The print edition is not for sale in China Mainland. Customers from China Mainland please order the print book from: People's Military Medical Press.

Library of Congress Control Number: 2017955689

Printed on acid-free paper

This Springer imprint is published by Springer Nature
The registered company is Springer Nature Singapore Pte Ltd.
The registered company address is: 152 Beach Road, #21-01/04 Gateway East, Singapore 189721, Singapore

Preface

The rapid improvements in modern acoustics, electronics, and computer image processing techniques raise the possibility of improving and upgrading ultrasound instruments and provide vast prospects for their application. Ultrasound is now widely applied in various clinical medicine fields and, with its increasingly incomparable and irreplaceable advantages of low cost, convenience, rapidity, ease of use, and accuracy, etc., ultrasound has become an important medical imaging diagnostic method. Many medical colleges and universities have departments of medical imaging and encourage graduates to treat the ultrasonography profession as their priority in their future hospital careers. Nowadays, there are thousands of sonographers in various primary hospitals, and there are thousands of professionals with doctorates and master's degrees in ultrasonography who need to expand their knowledge of ultrasound diagnosis in many organs. This atlas has been compiled for the purpose of satisfying the needs of the increasing numbers of those professionals and the demand for knowledge on the part of clinicians to improve their diagnostic abilities. The atlas is edited by high-profile sonographers from various prime hospitals, aiming to provide basic, practical, and standardized knowledge on ultrasound diagnosis.

This atlas has been adopted as an international standard, combining different local ultrasound diagnostic practices. It offers strong guidance in a way that is simple, clear, comprehensive, and experiential. As far as possible, high-resolution ultrasound and anatomical images are included to cover standard sections of every visceral organ. The atlas also clearly describes the detection methods, structures of cross-sections, and measurement methods, and provides more overall value; moreover, it provides a brief description of the clinical application value of each illustration for readers to understand every standard ultrasound section, as well as its function. For every character, an English–Chinese conversion table is provided for readers to check, mark, and remember.

We sincerely invite any experts, professionals, and readers to give us good advice regarding any omissions. Although the atlas has been edited by high-profile sonographers, it may not cover everything, considering how widely ultrasound is now applied.

I am very appreciative for all of the contributors' input to enable this atlas to be completed. I thank Ms. W.Z. Chen, Ms. Z.L. Lu, Prof. Y.Q. Qian, and Prof. W.H. Jian. Furthermore, I thank Mr. Lei Yao, who participated in the

review process, and I also thank Ms. Jun Niu, who drew the schematic diagrams; their comments play an important role in showing the scientific value and authoritativeness of the illustrations. I am also deeply indebted to my family for all of their help.

Beijing, China
September 11, 2018

Mei Zhang

Contents

1 The Eye Scanning

W. L. Yang

Abstract

This chapter introduces the eye scanning and section sonogram with the fine schematic diagram. The shown parts are eyeball, visual pathways, ocular adnexal, extraocular muscles, ophthalmic artery and nerve, scanning methods, measuring methods and normal values, structures in section, and clinical application values.

Abbreviations

CRA	Central retinal artery
EDV	End diastolic velocity
OA	Ophthalmic artery
PCAs	Posterior ciliary artery short
PI	Pulsatility index
PSV	Peak systolic velocity
RI	Resistive index
TAMX	Time average peak velocity

1 An Overview of Anatomy

The eye is the organ of vision. It is divided into three parts: eyeball, visual pathways, and ocular adnexal. The eyeball, located within the orbit, is approximately spherical, with an anteroposterior diameter averaging 24 mm, vertical diameter averaging 23 mm, and horizontal diameter averaging 23.5 mm. It is divided into the wall and the content of the eye. The wall of eyeball consists of three layers, with the outermost layer being the fibrous membrane, the innermost layer retina, and the pigment layer in the middle. The content of the eyeball includes aqueous humor, lens, and vitreous body (Fig. 1.1).

W. L. Yang
Ophthalmology Department, Beijing Tongren Hospital, No. 1, Dongjiaominxiang Road, Dongcheng District,
Beijing, People's Republic of China
e-mail: yangwl_tr@163.com

M. Zhang (ed.), *Atlas of Human Body Ultrasound Scanning*,
https://doi.org/10.1007/978-981-10-5834-9_1

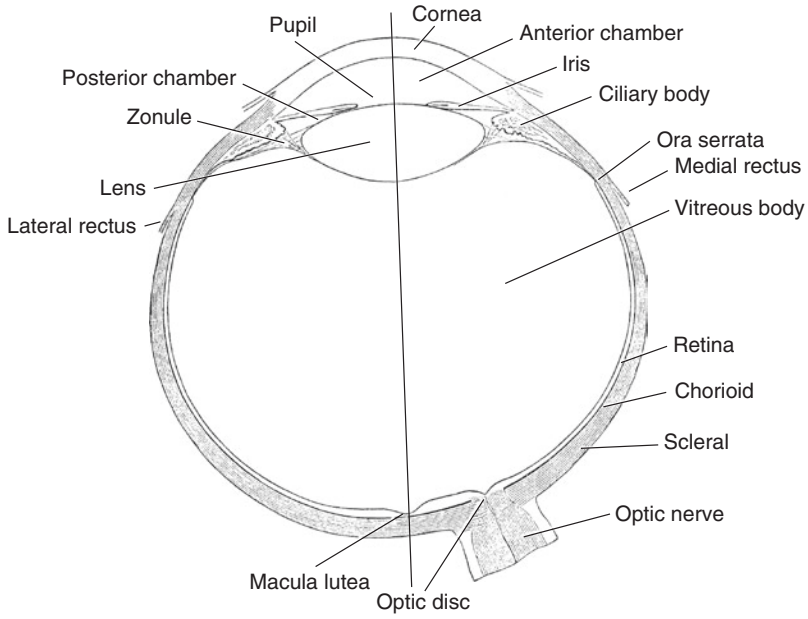

Fig. 1.1 The transverse view of the eyeball

2 The Sonogram of the Anterior Segment, Chamber Angle, and the Adjacent Structures. See Figs. 1.2, 1.3 and 1.4

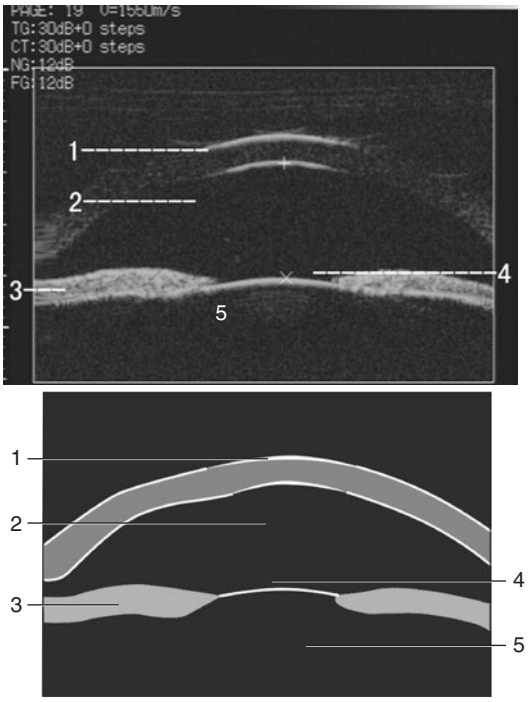

Fig. 1.2 The UBM view of the center area of the anterior segment. Note: *1* cornea, *2* anterior chamber, *3* iris, *4* pupil, *5* lens

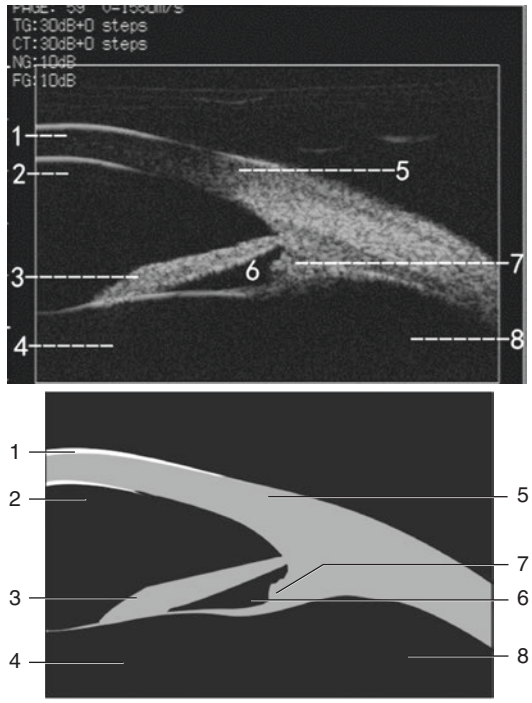

Fig. 1.3 The UBM view of the angle of the eye and the structures around it. Note: *1* cornea, *2* anterior chamber, *3* iris, *4* lens, *5* scleral, *6* posterior chamber, *7* ciliary body, *8* vitreous body

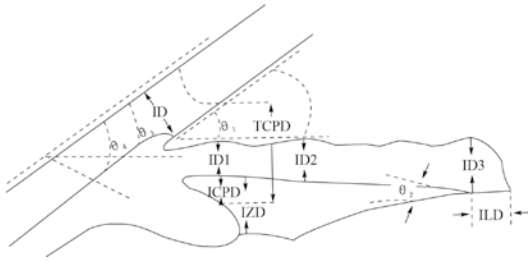

Fig. 1.4 The measurement methods of the anterior segment Pavlin CJ, Foster FS: Ultrasound biomicroscopy of the eye. New York, Springer-Verlag, 1995

2.1 Scanning Method

Ultrasound biomicroscopy is usually performed in supine position. Drops of anesthesia are added in the eye. Then a plastic shell is inserted into the eye. Liquid is added to the shell to form a seal. The operator places instrument in shell to perform the examination.

2.2 Section Structure

Due to the limited range of the instrument, the cornea, anterior chamber, anterior lens surface, iris, and pupil can generally be visualized at the axial section scan of the anterior segment. The corneoscleral limbus, part of the sclera, anterior chamber, iris, lens surface, anterior chamber angle, posterior chamber, zonule, ciliary body, peripheral vitreous, etc., can be observed when the probe is placed perpendicular to the corneoscleral limbus.

2.3 Measuring Method and Normal Value

Anterior segment parameters in the axial plane section are observed. Pavlin developed the measurement methods. First of all, a point needs to be determined 500um above the scleral spur. The distance between the trabecular meshwork and the ciliary process at 500 μm anterior to the scleral spur is called trabecular-ciliary process distance (TCPD). The iris thickness at 500 μm anterior to the scleral spur is called iris thickness (ID1). The distance between the iris and the ciliary process along the line of TCPD is called iris-ciliary process distance (ICPD). The iris thickness at 2 mm from the iris root is called iris thickness (ID2). The maximum iris thickness near the pupillary edge is called iris thickness (ID3). The distance between the iris and the zonule along the line of TCPD is called iris-zonule distance (IZD). The angle between the iris and the lens is θ_2. The contact distance between the iris and lens is called iris-lens contact distance. The angle between the sclera and iris is θ_3. The sclera-ciliary process angle is θ_4. The angle between the iris and the cornea is θ_1.

2.4 Clinical Value

UBM (50 MHz transducer) can be used to clearly image the structure of the anterior segment, with the image as clear as that made by an ordinary optical microscope and, in particular, unique features in imaging the chamber angle, posterior chamber, ciliary body, and peripheral vitreous. It is a valuable tool for the diagnosis of diseases in anterior and posterior chambers (glaucoma), hypotony syndrome resulted from trauma, peripheral vitreous diseases (inflammation, foreign matter), etc.

2.5 Notice

Ultrasound biomicroscopy has not been used widely. The purpose for introducing it is to show that there is a more clearer way to image it in the diagnosis of anterior segment disease.

Normal value shown in Table 1.1.

Table 1.1 Normal value of the anterior segment

ID1	390.88 ± 88.270	ID2	481.07 ± 57.70
ID3	800.42 ± 84.92	TCPD	1210.43 ± 233.00
θ_1	33.43 ± 8	CPD	62.41 ± 134.25
θ_2	17.22 ± 5.24	IZD	939.95 ± 4.6.20
θ_3	37.4 ± 45.28	ILCD	978.13 ± 207.16
θ_4	71.63 ± 13.87		

Note: *TCPD* trabecular-ciliary process distance, *ID1* iris thickness, *ICPD* iris-ciliary process distance, *ID2* iris thickness, *ID3* iris thickness, *IZD* iris-zonule distance. The angle between the iris and the lens is θ_2. *ILCD* iris-lens contact distance. The angle between the sclera and iris is θ_3. The sclera-ciliary process angle is θ_4. The angle between the iris and the cornea is θ_1

3 Axial Scanning of the Eye Globe. See Fig. 1.5

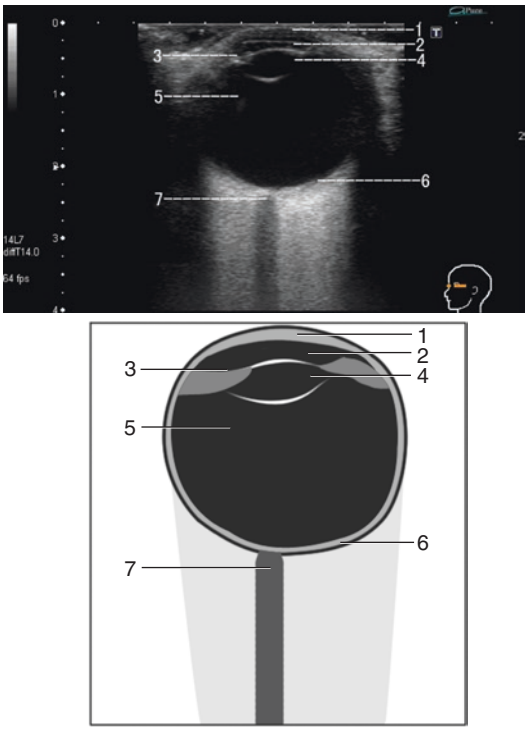

Fig. 1.5 The axial section of the eye globe. Note: *1* cornea, *2* anterior chamber, *3* iris, *4* lens, *5* vitreous body, *6* eyeball, *7* optic nerve

3.1 Scanning Method

High-frequency linear array transducer probe can be used to get an axial image of the eye globe from the corneal vertex to the optic nerve, with the patient lying flat on his/her back, the eye looking upward, and the probe is placed in a horizontal manner. In case the peripheral of the globe cannot be imaged clearly, you can tell the patient to move his/her eyes from side to side so that it can be imaged clearly.

3.2 Sectional Structure

Cornea, anterior chamber, iris, lens, vitreous body, walls of the eyeball, optic nerve, extraocular muscle, etc.

3.3 Measuring Method and Normal Value

It is generally the axial length of the eye globe that is measured, with the distance between the top of the cornea and the wall of the eye 3 mm adjacent to the optic disk as the reference point. Normal value is 23.5–24.5 mm. Two-dimensional ultrasound is not recommended for measuring anterior chamber depth, thickness of lens, length of vitreous, etc.

3.4 Clinical Value

Ultrasonography is one of the most helpful diagnostic methods for ocular disease, especially for patients whose fundus cannot be seen clearly with routine inspection methods. It is also one of the most helpful diagnostic methods for refractive interstitial opacity, trauma, and tumor.

4 Sonogram of the Normal Lacrimal Gland. See Fig. 1.6

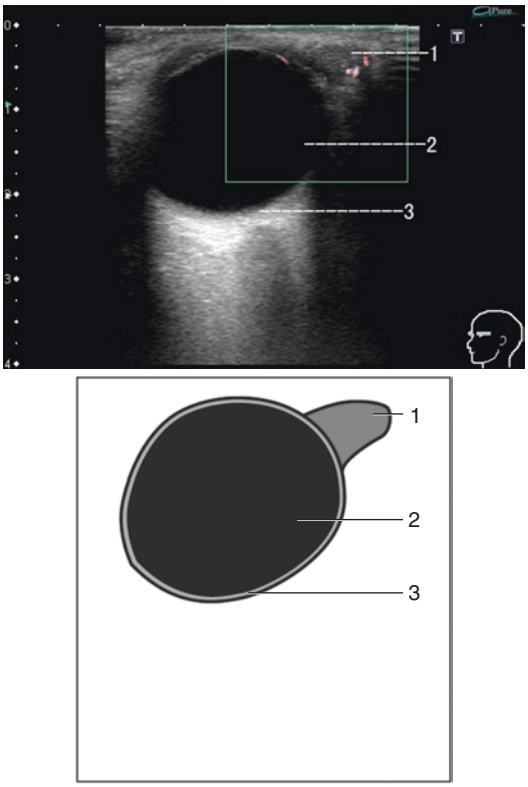

Fig. 1.6 Sonogram of the normal lacrimal gland. Note: *1* lacrimal gland, *2* vitreous body, *3* eyeball

4.1 Scanning Method

The probe is placed in a horizontal manner toward the superior temporal of the eye globe so that the palpebral portion of the lacrimal gland can be imaged. The orbital portion of the lacrimal gland can't be imaged completely and clearly because of the shelter from the orbital bone.

4.2 Sectional Structure

The palpebral portion of the lacrimal gland produces a weak echo triangle above the superior temporal of the eye in two-dimensional ultrasound, with clear boundaries between axial tissues and strong echo light dots evenly distributed inside.

4.3 Measuring Method and Normal Value

The maximum diameter of the lacrimal gland can be measured after the structure of the lacrimal gland is clearly imaged. The anatomical size of the orbital portion is 10 mm × 20 mm, while the palpebral-portioned lacrimal gland is somewhere between one third and one half. The structure of ultrasound measurement is limited by its capability to image the lacrimal gland which is generally smaller than its anatomical size.

4.4 Clinical Value

Sonography is clinically useful in diagnosing lacrimal gland disease, which, in particular, has unique features for diagnosing the palpebral-portioned lacrimal gland disease. Sphere techniques can be used to observe the orbital portion if the lesion is big or if it affects the orbit. Based on the exam results of the palpebral portion and the orbital portion, we can get a comprehensive understanding of lacrimal gland disease.

5 Normal Sonogram of the Extraocular Muscles. See Fig. 1.7

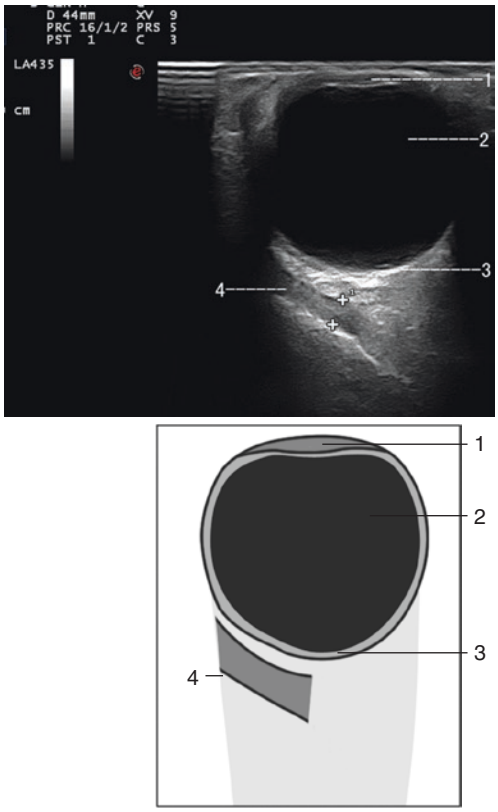

Fig. 1.7 Normal sonogram of the extraocular muscles. Note: *1* cornea, *2* vitreous body, *3* eyeball, *4* extraocular muscle

5.1 Scanning Method

The vertical scanning is used. The probe is placed opposite from the muscle being examined and the probe calibration toward the center of the cornea and the muscle being examined. The place is put vertically to scan the corneal limbus back and forth to display the long axial image of the muscle.

1. Medial rectus: The patient is asked to look straight ahead. Scanning is performed from the outer canthal region.
2. Lateral rectus muscle: Scanning is performed from the nasal side. If the nose hinders the exam, ask the patient to move the eyeball 10° outward.
3. Inferior rectus: Ask the patient to move the eyeball 10° downward and place the probe above the eye to exam.
4. Superior and levator palpebrae superioris muscle: Place the probe below the eyeball. Two weak reflection structures can be detected; however, it is not easy to distinguish.

5.2 Sectional Structure

Ultrasonic scans can show the dark muscle bands from the peripheral of the eyeball to the behind. The boundary is clear because of the fascia between the muscle and other orbit tissue.

5.3 Measuring Method and Normal Value

Measurement is based on vertical scanning of the extraocular muscle. Measurements are performed at the posterior 1/3 of the muscle.

The thickness of the normal extraocular muscle. See Table 1.2.

Table 1.2 The thickness of the normal extraocular muscle

Muscle	Normal range (mm)
Superior rectus/levator complex	3.9–6.8
Lateral rectus	2.2–3.8
Inferior rectus	1.6–3.6
Medial rectus	2.3–4.7
Sum of all muscles	11.9–16.9

5.4 Clinical Value

The value of using ultrasonography to determine the thickness of the extraocular muscle is still arguable. The author does not recommend this method because the repeatability and accuracy of this measurement are not very satisfactory. However, this measurement is considered to be useful for the observation of inflammation, tumor, and other orbital disorders involving the extraocular muscle. If the thickness of the extraocular muscle is measured merely to diagnose relevant diseases such as dysthyroid ophthalmopathy, it's better to run a MRI to get a more direct and reliable result.

6 Color Doppler and Pulse Doppler Imaging of the Eye.

See Fig. 1.8

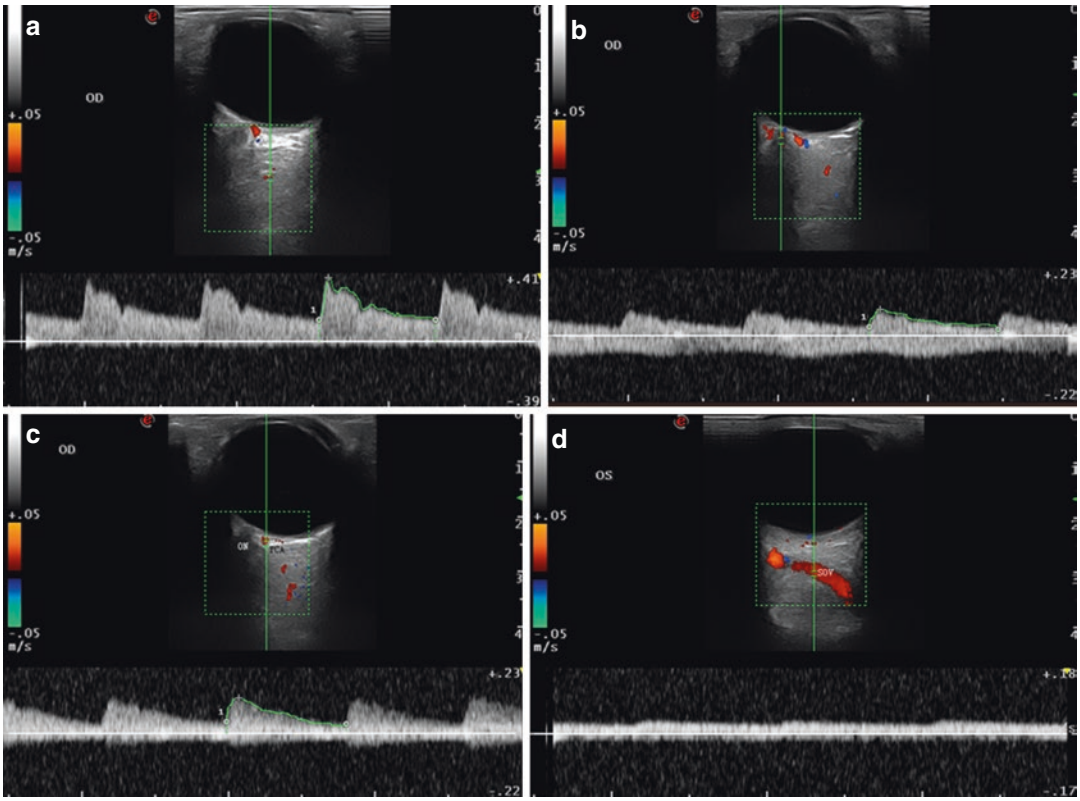

Fig. 1.8 Color Doppler and pulse Doppler imaging of the eye. Note: (**a**) *OA* ophthalmic artery, (**b**) *CRA* central retinal artery, (**c**) *PCAs* posterior ciliary artery short, (**d**) Superior OphthalmicVein

6.1 Scanning Method

The globe should be scanned in transverse planes. The optic nerve should be identified clearly to locate the orbit vessels. The Doppler sample gate is set 15–25 mm posterior to the globe in the OA, which is located along the optic nerve and is similar to the letter "S." Set the Doppler sample gate 2–5 mm posterior to the globe in the CRA and CRV which are in the center of the optic nerve. Set the Doppler sample gate 5–8 mm posterior to the globe in the PCA beside the optic nerve.

6.2 Sectional Structure

Color blood flow imaging can be seen in the orbit. Generally, it is the ophthalmic artery (OA) that can be located with color Doppler imaging by scanning the optic nerve on the nasal sides 15 mm posterior to the globe. The red and blue blood flow in the optic nerve is the central retinal artery (CRA) and central retinal vein (CRV). The clustered blood flow adjacent to the optic nerve is PRA. While SOV cannot be identified in every patient, it can be located between the medial rectus and optic nerve in the orbit.

Table 1.3 Blood flow parameter values of the normal ophthalmic vessels (Tongren Hospital, ultrasonic diagnosis department)

	PSV (cm)	EDV (cm)	TAMX (cm)	PI	RI	S/D
Ophthalmic artery (OA)	31.47 ± 9.63	7.11 ± 2.34	12.44 ± 3.64	2.02 ± 0.71	0.77 ± 0.06	4.60 ± 1.08
Central retinal artery (CRA)	10.82 ± 2.97	3.28 ± 1.11	5.50 ± 2.06	1.48 ± 0.49	0.71 ± 0.08	3.93 ± 1.28
Posterior ciliary artery short (PCAs)	11.61 ± 3.41	3.34 ± 1.25	5.83 ± 1.91	1.49 ± 0.43	0.70 ± 0.09	4.29 ± 1.82

6.3 Measuring Method and Normal Value

The ophthalmic artery is generally measured in the way as used in the measurement of peripheral vessels. Their normal values are listed in Table 1.3. including peak systolic velocity (PSV), end diastolic velocity (EDV), time average peak velocity (Tmax), etc. Pulsatility index (PI), resistive index (RI), and S/D: PSV/EDV can be calculated based on formulas.

6.4 Clinical Value

Color Doppler imaging is sensitive to determine changes of blood flow velocity in orbit blood vessels. Vessels can be identified correctly according to their anatomical location. Therefore, this method is valuable in the diagnosis of eye diseases such as vascular obstruction, inflammation, ischemic disease, orbital vascular malformation, etc.

2 Transcranial Ultrasonography

Haiyan Niu

Abstract

The objective of this chapter is to show the readers how to operate tanscranial ultrasound scanning, to recognize the normal anatomic structure through ultrasonic image, and to understand the clinical application value of each section. The standardized sections can get through anterior fontanelle or temporal area by sagittal, oblique, or coronary scanning of lateral ventricle or thalamus. The schematic diagram-matched each ultrasonic scanning plane is shown. The contents contain the scanning method, section structures, measuring method, reference values and clinical application value of the sections of the craniocerebral.

Abbreviations

CC	Corpus callosum
CH	Cerebellar hemisphere
CN	Caudate nucleus
CP	Choroid plexus
CSP	Cavum of septum pellucidum
CS	Cingulate sulcus
CT	Cerebellar tentorium
FL	Frontal lobe
IC	Internal capsule
IHF	Interhemispheric fissure
LV	Lateral ventricle
OL	Occipital lobe
T	Thalamus
TL	Temporal lobe
V	Cerebellar vermis
V3	Third ventricle
V4	Fourth ventricle

HY. Niu
Ultrasonic Diagnosis Department,
PLA Army General Hospital,
Dongcheng District, Dongsi Nanmencang No. 5,
Beijing 100700, China
e-mail: 13901152856@163.com

M. Zhang (ed.), *Atlas of Human Body Ultrasound Scanning*,
https://doi.org/10.1007/978-981-10-5834-9_2

1 Sagittal Scanning of the Lateral Ventricle Through Anterior Fontanelle

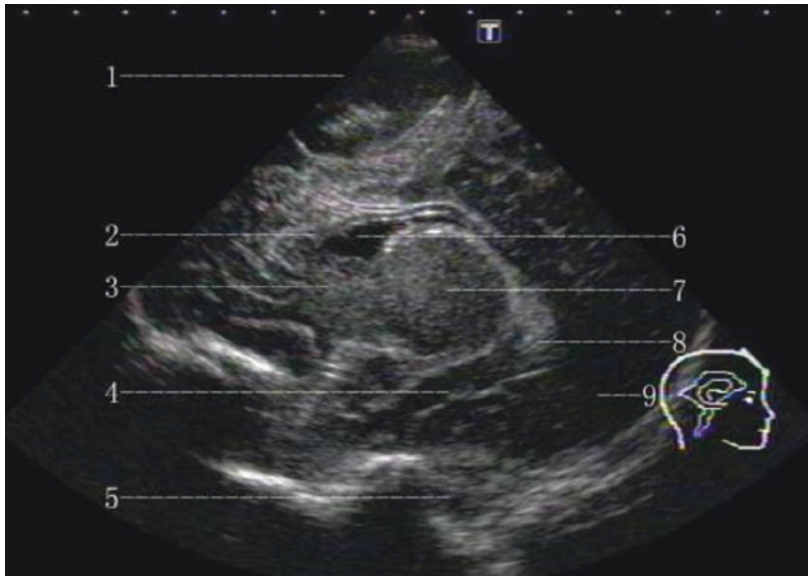

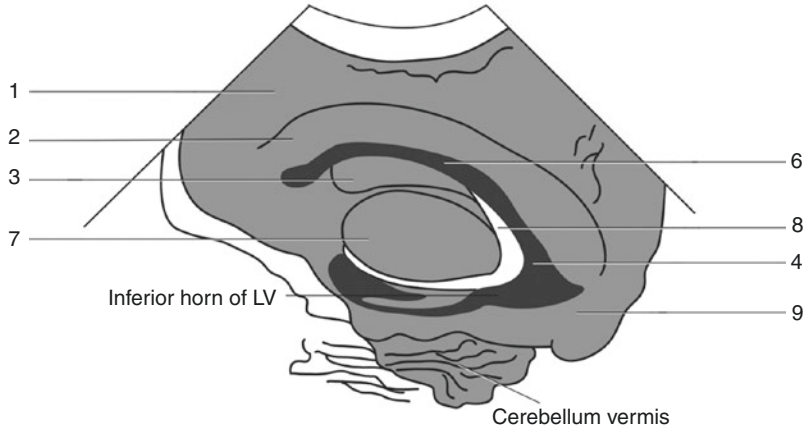

Fig. 2.1 Sagittal section of the lateral ventricle through the anterior fontanelle. Note: *1* frontal lobe, *2* corpus callosum, *3* caudate nucleus, *4* inferior horn of the lateral ventricle, *5* cerebellar vermis, *6* anterior horn of lateral ventricle, *7* thalamus, *8* choroid plexus, *9* occipital lobe

1.1 Scanning Method

The patient should take a supine position. Probe is placed vertically on the anterior fontanelle 0.5–1.0 cm beside midline.

1.2 Section Structure

Sagittal section of brain parenchyma of the frontal lobe, occipital lobe, thalamus, corpus callosum, caudate nucleus, body, anterior horns and occipital horns of lateral ventricle, and cerebellar vermis.

1.3 Measuring Method and Normal Values

Measuring sagittal diameter of the anterior horn of lateral ventricle, normal value should be less than 4 mm. Anteroposterior diameter of occipital horn is measured from posterior edge of the thalamus to the apex of occipital horns, normal range: 8.7~15 mm.

1.4 Clinical Application Value

To diagnose hemorrhage, hydrocephalus, congenital malformations and tumors of the frontal lobe and occipital lobe, cyst of choroid plexus, and edema of the brain parenchyma.

2 Sagittal Scanning of the Midline Structures Through Anterior Fontanelle

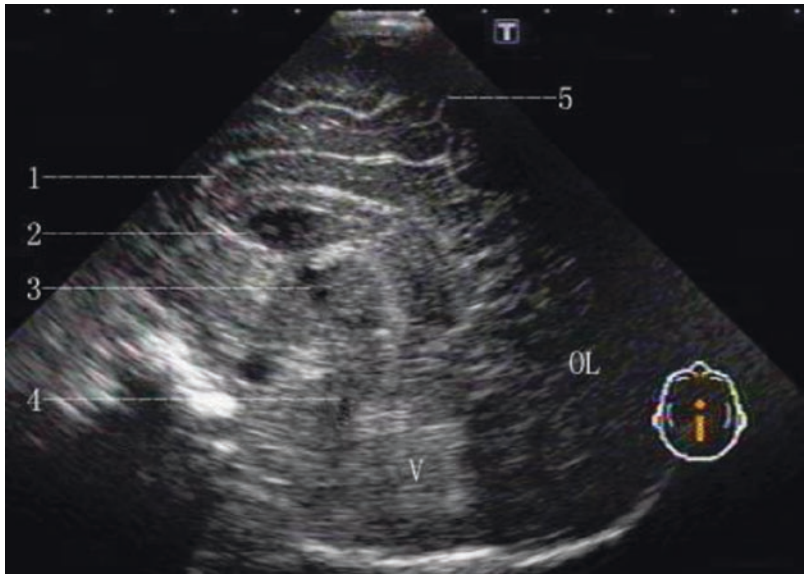

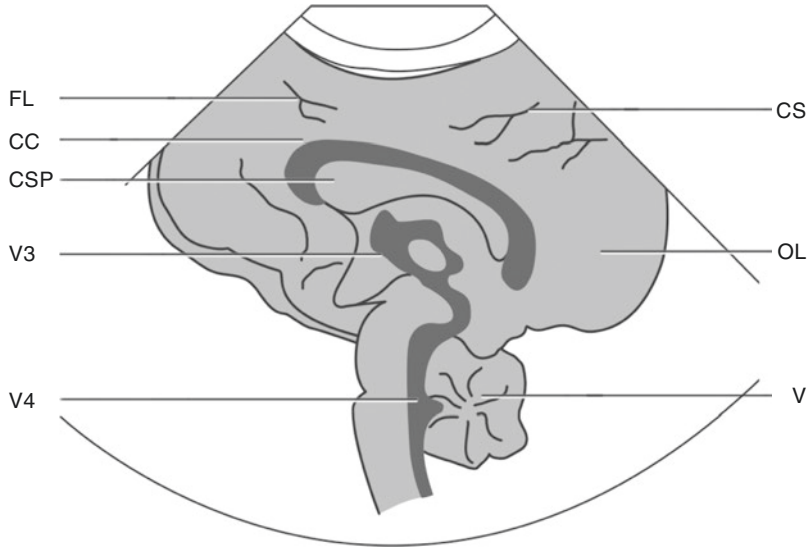

Fig. 2.2 Sagittal section of the midline structures. Note: *1* callosum corpus, *2* cavum of septum pellucidum, *3* third ventricle, *4* fourth ventricle, *5* cingulate sulcus, *OL* occipital lobe, *V* cerebellar vermis

2.1 Scanning Method

The patient should take a supine position. Probe is placed vertically on the anterior fontanelle through midline, acoustic beam towards inferoposterior.

2.2 Section Structure

Sagittal section of the frontal lobe and occipital lobe, callosum corpus, cavum of the septum pellucidum, third ventricle, fourth ventricle, cingulate sulcus, and cerebellum is shown.

2.3 Measuring Method and Normal Value

Measuring sagittal diameter of the cavum of septum pellucidum (CSP), anterior horn, body, and occipital horn of lateral ventricle. The normal value of CSP is less than 5mm in neonates.

2.4 Clinical Application Value

Observing brain parenchyma of the frontal lobe, occipital lobe, and cerebellum, to diagnose hemorrhage, hydrocephalus, congenital malformations and tumors, cyst of choroid plexus, and edema of brain. Observing cavity of the third ventricle and the fourth ventricle, to diagnose ventriculomegaly.

3 Coronary Scanning of the Thalamus Through Anterior Fontanelle

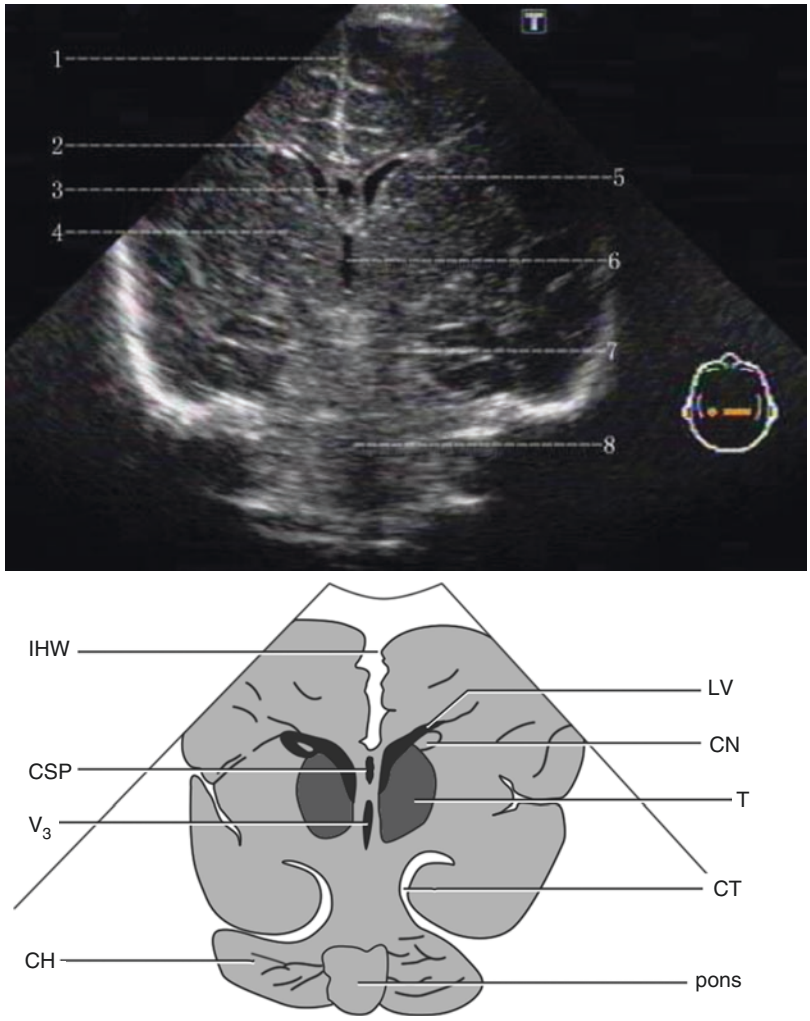

Fig. 2.3 Coronary section of the thalamus through anterior fontanelle. Notes: *1* interhemispheric fissure, *2* lateral ventricle, *3* cavum of septum pellucidum, *4* thalamus, *5* caudate nucleus, *6* third ventricle, *7* cerebellar tentorium, *8* cerebellar hemisphere and pons

3.1 Scanning Method

The patient should take a supine position. Probe is placed coronary transversely on the anterior fontanelle.

3.2 Section Structure

The coronary section of the interhemispheric fissure, cavum of septum pellucidum, thalamus, caudate nucleus, third ventricle, temporosphenoid lobe, anterior horns of lateral ventricle, cerebellar hemisphere, and pons is shown.

3.3 Measuring Method and Normal Value

Measuring the width of the anterior horns of lateral ventricle, cavum of septum pellucidum, third ventricle, and interhemispheric fissure. The normal value of anterior horn of lateral ventricle is less than 3 mm in newborns. The reference value of cavum of septum pellucidum is less than 5 mm.

3.4 The Clinical Application Value

Observing brain parenchyma echogenity of the temporosphenoid lobe and cerebellar hemisphere, diagnosis of hemorrhage, tumor, and premature infant hydrocephalus. The widths of anterior horn of lateral ventricle is 4–6 mm, 7–10 mm, and larger than 10 mm, measured up to mild, moderate, and severe dilation, respectively.

4 Coronary Transverse Scanning of the Lateral Ventricle Through Anterior Fontanelle

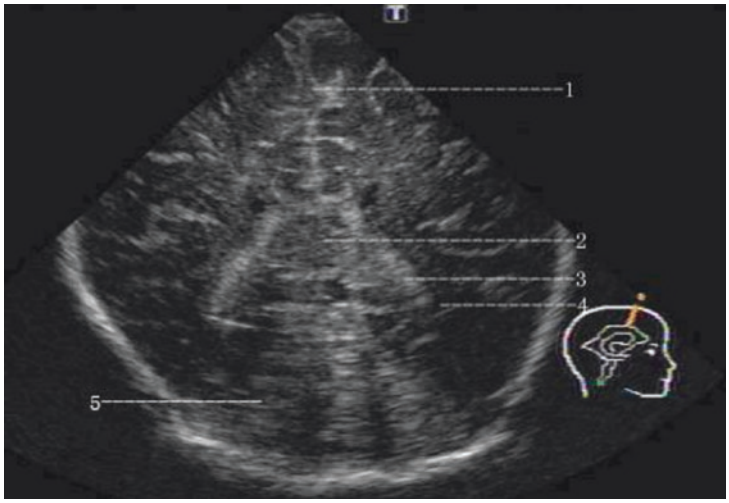

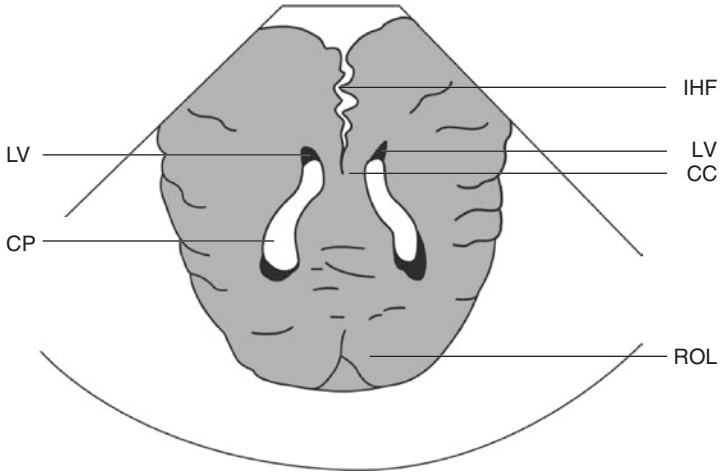

Fig. 2.4 Coronary section of the lateral ventricle through anterior fontanelle. Notes: *1* interhemispheric fissure, *2* corpus callosum, *3* choroid plexus, *4* lateral ventricle, *5* occipital lobe

4.1 Scanning Method

The patient should take a supine position. Probe is placed coronary transversely on the anterior fontanelle, acoustic beam inclined to interior slightly.

4.2 Section Structure

Coronary section of the choroid plexus, temporal lobe, occipital lobe, and body of lateral ventricle.

4.3 Measurement Method and Normal Value

Measuring diameter of body of the lateral ventricle, the reference value in full-term infants should be less than 10 mm.

4.4 The Clinical Application Value

To diagnose the diseases of the brain parenchyma and lateral ventricle, such as tumor, hemorrhage, hydrocephalus and hypoxie-ischemic encephalopathy(HIE) of premature infants.

5 Oblique Scanning of the Lateral Ventricle Through Temporal Area

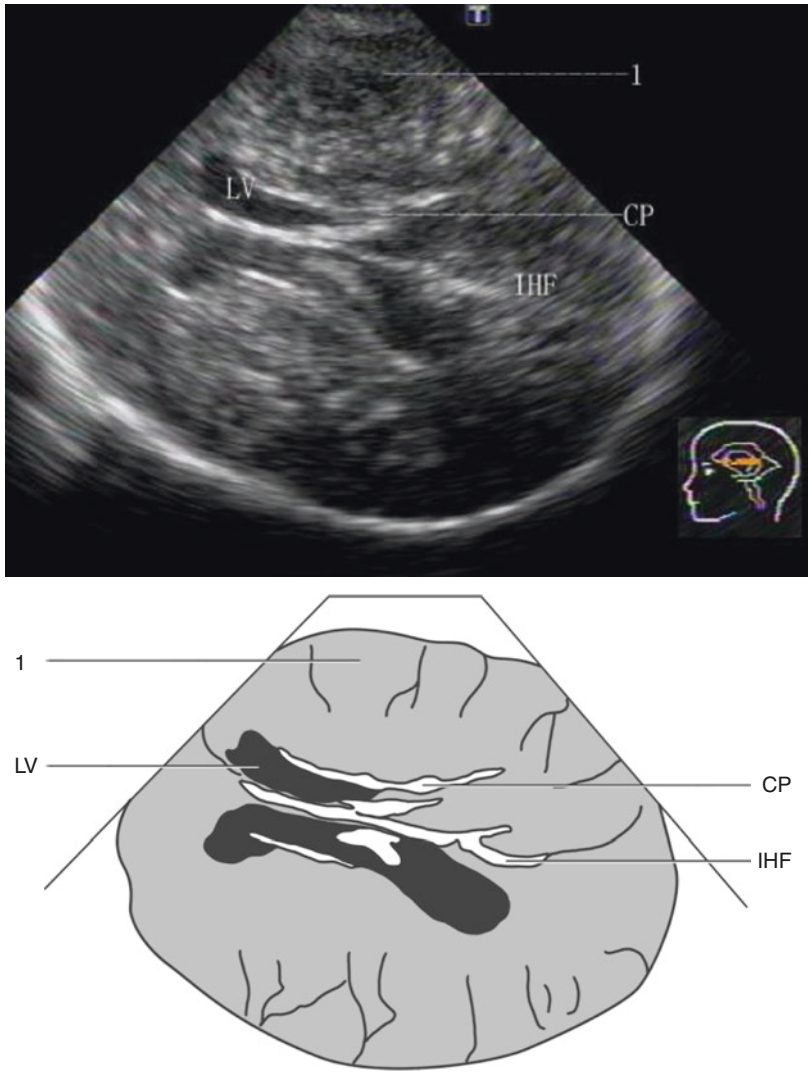

Fig. 2.5 Oblique section of the lateral ventricle through temporal area. Notes *1* temporal lobe, *LV* lateral ventricle, *CP* choroid plexus, *IHF* interhemispheric fissure